

## 9th International Congress on Psychopharmacology & 5th International Symposium on Child and Adolescent Psychopharmacology

Özge Şahmelikoğlu Onur, Merve Çukurova, Sevda Bağ, Suat Yalçın, Cansu Çakır Şen, Çağatay Karşıdağ, Serdar Süleyman Can, Emine Tuğçe Akçaer, Ayşegül Taşdelen Kul, Mustafa İspir, Osman Bakkal, Ayhan Algül, Servet Ebrinç, Serdar Süleyman Can, Ayşegül Taşdelen Kul, Cihad Yükselir, Serkan Zincir, Pelin Öztürk, Bülent Karaahmetoğlu, Özlem Baş, Özge Şahmelikoğlu Onur, Sema Ulukaya, Serdar Süleyman Can, Çağlar Soykan, Ali Çayköylü, Ayşegül Taşdelen Kul, Neslihan Yazar, Zehra Başar Kocagöz, Adnan Özçetin, Safiye Bahar Ölmez, Ahmet Ataoğlu, Yasin Hasan Balcioglu, Tonguc Demir Berkol, Filiz Ekim Cevik, Fatih Oncu, Guliz Ozgen, Dudu Demiröz, Hatice Yardım Özayhan, Hilal Seven, Mustafa Çağrı Yıldız, Recep Başaran, İbrahim Eren, Elif Özlem Canazlar, Levent Sevinçok, Bilge Doğan, Çağdaş Öykü Memiş, Ali Baran Tanrikulu, İkbâl İnanlı, Mustafa Çağrı Yıldız, Tuba Şerife Elmas, İbrahim Eren, Şükrü Alperen Korkmaz, Cansu Pınar Şen, Mehmet Fatih Ceylan, Selma Tural Hesapçıoğlu, Burcu Bakar, Can Tuncer, Rümeyza Yeni Elbay, Aynur Görmez, Yusuf Tokgöz, Abdullah Bolu, Cemil Çelik, Özcan Uzun, Simge Seren Kirlioglu, Yasin Hasan Balcioglu, Pinar Cetinay Aydin, Mustafa Uğurlu, Görkem Karakaş Uğurlu, Emine Tuğçe Akçaer, Serdar Süleyman Can, Ali Çayköylü, Zuhâl Koç, Nazlı Kapubağlı, Ömer Faruk Tuncer, Gülsen Ünlü, Yasin Hasan Balcioglu, Simge Seren Kirlioglu, Guliz Ozgen, Ali Çayköylü, Mustafa Uğurlu, Esra Kabadayı Şahin, Görkem Karakaş Uğurlu, Serdar Süleyman Can, Zuhâl Koç Apaydın, Semra Ulusoy Kaymak, Oğuz Peker, Serdar Süleyman Can, Zuhâl Koç, Ali Çayköylü, Bedriye Özkan, Ali Güven Kılıçoğlu, Gül Karaçetin, Zeynep Yücehan, Tuğba Şerife Elmas, Dudu Demiröz, Nafiye Yağlı, Bilge Çetin İlhan, İbrahim Eren, Derya Adalı Aker, Yiğit Kivılcım, Mustafa Solmaz, Yeşim Ruhut Kutlu, Bahar Yeşil, Behice Han Almış, Başak Küçük, Cem Cerit, Burcu Sarici, Ayşe Ceren Kaypak, Erensu Baysak, Serhat Ergün, Mesut Yıldız, Aslihan Okan İbiloğlu, Abdullah Atli, Mehmet Asoğlu, Mustafa Ozkan, Nursu Çakın Memik, Hatice Ünver, Özlem Yıldız Gündoğdu, Necati Uzun, Ömer Faruk Akça, Gizem Aral, Demet Sağlam Aykut, Özgür Maden, Mustafa İspir, İbrahim Gündoğmuş, Ayhan Algül, Servet Ebrinç, Fulya Gok, Seda Kiraz, Arif Cipil, Meliha Zengin Eroğlu, Elvan Çiftçi, Zeynep Aslan, Melike Kevser Gül, Neslihan Taştepe, Esra Demirci, Sevgi Özmen, Hicran Doğru, Elif Karayağmurlu, Ali Karayağmurlu, Muhsine Göksu, Leyla Ezgi Tüngen, Ayşe Burcu Ayaz, Ayşe Arman, Recep Başaran, Hatice Yardım Özayhan, Deniz Altunova, Dudu Demiröz, İbrahim Eren, Mustafa Çağrı Yıldız, Yasin Hasan Balcioglu, Simge Seren Kirlioglu, Pinar Cetinay Aydin, Serdar Süleyman Can, Çağlar Soykan, Murat İlhan Atagün,

Ali Çayköylü, Görkem Karakaş Uğurlu, Ayşegül Taşdelen Kul, Ekrem GÜltaş, Güler Göl, Uğur Savcı, Ali Evren Tufan, Seda Yıldırım Özbek, Süleyman Özbek, Hilal Uygur, Başak Demirel, İ. Esra Çiçek, İbrahim Eren, Hüseyin Kara, Mehmet Murat Balcı, Servet Karaca, Mehmet Murat Kuloğlu, Hasan Mervan Aytaç, Mehmet Can Ger, Abdullah Atli, Aslıhan Okan İbiloğlu, Mehmet Asoğlu, Ayşe Çakır, Demet Sağlam Aykut, Ahmet Tiryaki, Gülşah Güçlü Çelme, Mehmet Hamid Boztaş, Fatma Sırmatel, Yasin Hasan Balcioglu, Muhahid Erdogan, Cengiz Dayan, Hayrunisa Dilek Atakli, Gülşen Kartalcı, Ebru Yücel, Şükrü Kartalcı, Meliha Zengin Eroğlu, Arif Çipil, Mecit Çalışkan, Semra Ulusoy Kaymak, Görkem Karakaş Uğurlu, Oğuz Peker, Zuhul Koç, Murat İlhan Atagün, Ali Çayköylü, Emine Cengiz Çavusoglu, Yusuf Özay Özdemir, Elvan Çiftçi, Abdullah Atli, Aslıhan Okan İbiloğlu, Mehmet Asoğlu, Dudu Demiröz, Hatice Yardım Özayhan, Zeynep Yücehan, Tuba Şerife Elmas, İbrahim Eren, Ebru Fındıklı, Hasan Mervan Aytaç, Berkan Şahin, Koray Karabekiroğlu, Mustafa Kurt, Çağdaş Öykü Memiş, Bilge Doğan, Doğa Sevinçok, Levent Sevinçok, Merve Sertdemir, Ömer Faruk Akça, Doğa Sevinçok, Çağdaş Öykü Memiş, Bilge Doğan, Levent Sevinçok, Rukiye Ay, Nevzat Yılmaz, Sevcen Karakoç Demirkaya, Hatice Aksu, Hacer Gizem Gerçek, Gülser Karakoç, Ayşe Ender Altıntoprak, Hakan Coşkunol, Ipek Percinel Yazıcı, Kemal Utku Yazıcı, Hicran Doğru, Seda Kiraz, Kevser Altıntaş, Fulya Gök, Meliha Zengin Eroğlu, Ferhat Yaylacı, Handan Özek Erkuran, Murat Eyüboğlu, Diğdem Göverti, Rabia Nazik Yüksel, Alper Bülbül, Makbule Çiğdem Aydemir, Erol Göka, İlğaz Kınalı, Münevver Yıldırım Hacıoğlu, Ayşe Ceren Kaypak, Burcu Sarıcı, Erensu Baysak, Serhat Ergün, Kemal Sayar, İbrahim Gündoğmuş, Mustafa İspir, Ayhan Algül, Servet Ebrinç, Hatice Doğan, Hatice Doğan, Sevda Bağ, Merve Çukurova, Ömer Akay, Çağatay Karşıdağ, İbrahim Gündoğmuş, Osman Bakkal, Ayhan Algül, Servet Ebrinç, Heecheol Kim, Hyunjoo Lee, Çağlar Soykan, Serdar Süleyman Can, Ali Çayköylü, Ayşegül Taşdelen Kul, Abdulkadir Karagöz, İbrahim Gündoğmuş, Hakan Kullakçı, Özgür Maden, Ayhan Algül, Servet Ebrinç, Serdar Süleyman Can, Yasin Duman, Murat İlhan Atagün, Ayşegül Taşdelen Kul, Ali Çayköylü, Yusuf Çokünlü, Memduha Aydın, Tuba Şerife Elmas, İbrahim Eren, Ali Baran Tanrıku, Memduha Aydın, Tuba Şerife Elmas, Deniz Altunova, İbrahim Eren, Hande Ayraller Taner, Burcu Akın Sarı, Çiğdem Yektaş, Nuran Demir Samurcu, Ali Evren Tufan, Tuba Şerife Elmas, Saliha Çalışır, Memduha Aydın, Dudu Demiröz, Ali Baran Tanrıku, İbrahim Eren, Hakan Kullakçı, Mustafa İspir, Ayhan Algül, Servet Ebrinç, Mustafa İspir, İbrahim Gündoğmuş, Özgür Maden, Ayhan Algül, Servet Ebrinç, Özalp İkinci, Muhammet Emin Tan, Merve Kalınlı, Murat Kıyanççek, İbrahim Gündoğmuş, Özgür Maden, Ayhan Algül, Meltem Küçükdağ, Çiğdem Yektaş, Hasret Karabulut Gül, Demet Sağlam Aykut, Emel Uysal, Filiz Civil Arslan, Emel Uysal, Demet Sağlam Aykut, Hasret Karabulut Gül, Evrim Özkorumak Karagüzel, Dudu Demiröz, Hatice Yardım Özayhan, Hilal Seven, Recep Başaran, Mustafa Çağrı Yıldız, İbrahim Eren, Burak Karakök, Halime Tuna Çak, Pınar Kızılay Çankaya, İlkay Keleş Altun, Eren Abatan, Emel Uysal, Yusuf Çokünlü, Tuba Şerife Elmas, Süleyman Özbek, Ali Metehan Çalışkan, İbrahim Eren, Hatice Kübra Çakı, Burak Doğangün, Muhammed Tayyib Kadak, Mehmet Kefeli, Asiye Arıcı, Hatice Altun, Can Acıpayam, Pelin Çon Bayhan, Neslihan Taştepe, Melike Kevser Gül, Sevgi Özmen, Esra Demirci, Tuba Şerife Elmas, Saliha Çalışır, Ali Baran Tanrıku, Yusuf Çokünlü, Mustafa Çağrı Yıldız, Zeynep Yücehan, İbrahim Eren, Muhammet Emin Tan, Özalp İkinci, İlkay Keleş Altun, Pınar Kızılay Çankaya, Emel Uysal, Elif Nurgül Sungur, Ayşe Nur İnci Kenar, Sevde Afife Ersoy, Mehmet Gürkan Gürok, Sevler Yıldız, Tuba Korucu, Denizhan Danacı Keles, Murad Atmaca, Esra Hoşoğlu, Ömer Faruk Akça, Kübra Kılınç, Barış Şen, Erdem Örnek, Cengiz Çelebi, Ayşe Sakallı Kani, Ömer Yanartaş, Zeynep Şenkal, Yıldız Akvardar, Kaan Kora, Ümran Egilmez, Ali Kandeğer,

Özkan Güler, Kemal Utku Yazici, Ipek Percinel Yazici, Selcen Dogru Kösker, Elif Ates Budak, Zeliha Deveci Karasin, Mehmet Diyaddin Güleken, Mustafa Celik, Ipek Percinel Yazici, Kemal Utku Yazici, Hande Yıldırım, Ayşe Ender Altıntoprak, Burçin Güler, Baybars Veznedaroğlu, Funda Lale, Halime Tuna Çak Esen, Göknur Haliloğlu, Bahar Yeşil, Behice Han Almış, Nuran Ekinci, Gamze Özçürümez Bilgili, Can Tuncer, Volkan Seneger, Rümeyza Yeni Elbay, Aynur Görmez, Ümit Işık, Gonca Aşut, Elif Tatlıdil Yaylacı, Ömer Asan, Erol Göka, Serkan Güneş, Bahar Yeşil, Ali Metehan Çalışkan, Ebru Çiftçi, Sehure Azra Yaşar, İkbāl İnanlı, İbrahim Eren, Kevser Altıntaş, Seda Kiraz, Sencan Sertçelik, Meliha Zengin Eroğlu, Osman Bakkal, İbrahim Gündoğmuş, Özgür Maden, Ayhan Algül, Servet Ebrinç, Abdullah Atli, Aslıhan Okan İbiloğlu, Mehmet Asoğlu, Selma Hilal Avcı, Aynur Görmez, Can Tuncer, Volkan Seneger, İbrahim Gündoğmuş, Mustafa İspir, Özgür Maden, Ayhan Algül, Servet Ebrinç, Kevser Altıntaş, Alişan Burak Yaşar, Sencan Sertçelik, Can Tuncer, Burcu Bakar, Hasan Turan Karatepe, Rümeyza Yeni Elbay, Melike Dönmez, Volkan Topçuoğlu, Ömer Yanartaş, Merve Sertdemir, Ayhan Bilgiç, Hicran Doğru, Volkan Doğru, Abdullah Bozkurt, Berkan Şahin, Koray Karabekiroğlu, Tuğba Kalyoncu, Deniz Argüz Çıldır, Can Beşer, Neşe Perdahlı Fiş, Serkan Güneş, Şermin Bilgen Ulgar, Hamza Ayaydın, Hatice Takatak, Hamza Ayaydın, Cansu Çobanoğlu, Mahmut Müjdecı, Berkan Şahin, Yusuf Yasin Gümüş, Merve Kalınlı, Özalp Ekinci, Serkan Güneş, Betül Akbaş, Ömer Faruk Akça, Hicran Doğru, Feyza Hatice Sevgen, Hatice Altun, Hasan Mervan Aytaç, Fatih Öncü, Nilfer Şahin, Damla Balkan, Fatma Coşkun, Savaş Yılmaz, Ömer Faruk Akça, Çağla Çelikkol, Savaş Yılmaz, Ganime Dilek Emlik, Hüseyin Çaksen, Derya Arslan, Özden Arısoy, Ahmet Şair, Yaşan Bilge Şair, Dilek Sarı, Mustafa İspir, Ayhan Algul, Servet Ebrinç, Vuslat Kara Ölmeztoprak, Esra Porgalı Zayman, Süheyla Ünal, Dudu Demiröz, Hatice Yardım Özayhan, Sehure Azra Yaşar, Ali Hakan Öztürk, İbrahim Eren, Başak Karabucak, Ebru Sadriye Çengel Kültür, Tuna Halime Çak Esen, Arif Çipil, Meliha Zengin Eroğlu, Alişan Burak Yaşar, Mecit Çalışkan, Ferhat Yaylacı, Handan Özek Erkuran, Meliha Zengin Eroğlu, Mecit Çalışkan, Seda Kiraz, Arif Çipil, İpek Fatma Özaktaç, Murat Altın, Ayşe Sena Sarıdoğan, Eser Buluş, Alper Bülbül, Sevilay Güneş, Rabia Nazik Yüksel, Makbule Çiğdem Aydemir, Erol Göka, Hamza Ayaydın, Hatice Takatak, Zehra Koyuncu, Muhammed Tayyib Kadak, Rahime Hülya Bingöl, Burak Doğangün, Mine Uzgel, Selahattin Ayas, Yüksel Kıvrak, Yiğit Şahbal, Kübra Kocagöz, Demet Sağlam Aykut, Gamze Kutlu, Ali Baz, Güler Göl, Ekrem Gölbaş, Mehmet Akif Cansız, Ali Evren Tufan, Deniz Argüz Çıldır, Tuğba Kalyoncu, Yasin Duman, Serdar Süleyman Can, Çağlar Soykan, Ayşegül Taşdelen Kul, Ebru Sağlam, Ömer Faruk Akça, Özlem Önen, Ayşe Kutlu, Handan Özek Erkuran, Handan Özek Erkuran, Ecenur Aydın Aşık, Şermin Yalın Sapmaz, Tuğba Kalyoncu, Deniz Argüz Çıldır, Serpil Erermiş, Hatice Ünver, Şahika Gülen Şişmanlar, İsmail Karka, Fethiye Kilicaslan, Mehmet Asoglu, Ceren Enüstün Hürmeydan, Özge Şahmelikoğlu Onur, Sevda Bağ, Suat Yalçın, Ozge Sahmelikoğlu Onur, Didem Nagehan Sarı, Bahar Kılıç, Elif Merve Kurt, İsmail Ak, Ali Emre Şevik, Ayşe Dilara Yalçın, Ümit Tural, Hilmi Yaşar, Serdar Süleyman Can, Yasin Duman, Ali Çayköylü, Şükrü Alperen Korkmaz, Görkem Karakaş Uğurlu, Ayşegül Taşdelen Kul, Yasin Hasan Balcioglu, Simge Seren Kirlioglu, Guliz Ozgen, Deniz Altunova, Recep Başaran, Mustafa Çağrı Yıldız, Ali Baran Tanrikulu, Münir Karaaslan, İbrahim Eren, Fatih Kizilağaç, Ümit Tural, Yusuf Tokgöz, Taner Öznur, Cemil Çelik, Özcan Uzun, Ali Baran Tanrikulu, Mustafa Çağrı Yıldız, İkbāl İnanlı, Tuba Şerife Elmas, Yusuf Çokünlü, Seher Serez Öztürk, Hilal Seven, Dudu Demiröz, Seda Özbek, İsmet Esra Çiçek, İbrahim Eren, Esra Porgalı Zayman, Rifat Karlıdağ, Mustafa Akan, Lara Utku İnce, İsmail Reyhani, Dilek Çağlar Tetik, Ayşe Büyükaslan, Musa Yılanlı, Ender Cesur, Sevda Bağ, Çağatay Karşıdağ, Yasin Hasan Balcioglu, Simge Seren Kirlioglu, Fatih Oncu, Fatma

**Belger, Bürge Kabukçu Başay, Volkan Seneger, Can Tuncer, Hasan Turan Karatepe, Aynur Görmez, Cansu Pinar Şen, Mehmet Fatih Ceylan, Selma Tural Hesapcioglu, Tuba Şerife Elmas, Saliha Çalışır, Ali Metehan Çalışkan, Ali Baran Tanrikulu, İbrahim Eren, Aslihan Okan Ibiloglu, Abdullah Atli, Mehmet Asoglu, Mustafa Ozkan, Özge Şahmelikoğlu Onur, Ender Cesur, Gülşen Teksin, Suat Yalçın, Sevda Bağ, Serkan Güneş, Ali Metehan Çalışkan, Ebru Çiftçi, Sehure Azra Yaşar, İkbāl İnanlı, İbrahim Eren, Erensu Baysak, Nese Yorguner Kupeli, Serhat Ergun, Kaan Kora, Mehmet Asoğlu, Hatice Takatak, Abdullah Atli, Aslihan Okan İbiloğlu, Mehmet Asoğlu, Öznur Akıl, Abdullah Atli & Aslihan Okan İbilioğlu**

To cite this article: Özge Şahmelikoğlu Onur, Merve Çukurova, Sevda Bağ, Suat Yalçın, Cansu Çakır Şen, Çağatay Karşıdağ, Serdar Süleyman Can, Emine Tuğçe Akçaer, Ayşegül Taşdelen Kul, Mustafa İspir, Osman Bakkal, Ayhan Algül, Servet Ebrinç, Serdar Süleyman Can, Ayşegül Taşdelen Kul, Cihad Yükselir, Serkan Zincir, Pelin Öztürk, Bülent Karaahmetoğlu, Özlem Baş, Özge Şahmelikoğlu Onur, Sema Ulukaya, Serdar Süleyman Can, Çağlar Soykan, Ali Çayköylü, Ayşegül Taşdelen Kul, Neslihan Yazar, Zehra Başar Kocagöz, Adnan Özçetin, Safiye Bahar Ölmez, Ahmet Ataoğlu, Yasin Hasan Balcioglu, Tonguc Demir Berkol, Filiz Ekim Cevik, Fatih Oncu, Guliz Ozgen, Dudu Demiröz, Hatice Yardım Özayhan, Hilal Seven, Mustafa Çağrı Yıldız, Recep Başaran, İbrahim Eren, Elif Özlem Canazlar, Levent Sevinçok, Bilge Doğan, Çağdaş Öykü Memiş, Ali Baran Tanrikulu, İkbāl İnanlı, Mustafa Çağrı Yıldız, Tuba Şerife Elmas, İbrahim Eren, Şükrü Alperen Korkmaz, Cansu Pinar Şen, Mehmet Fatih Ceylan, Selma Tural Hesapcioglu, Burcu Bakar, Can Tuncer, Rümeyza Yeni Elbay, Aynur Görmez, Yusuf Tokgöz, Abdullah Bolu, Cemil Çelik, Özcan Uzun, Simge Seren Kirioglu, Yasin Hasan Balcioglu, Pinar Cetinay Aydin, Mustafa Uğurlu, Görkem Karakaş Uğurlu, Emine Tuğçe Akçaer, Serdar Süleyman Can, Ali Çayköylü, Zuhall Koç, Nazlı Kapubağlı, Ömer Faruk Tuncer, Gülsen Ünlü, Yasin Hasan Balcioglu, Simge Seren Kirioglu, Guliz Ozgen, Ali Çayköylü, Mustafa Uğurlu, Esra Kabadayı Şahin, Görkem Karakaş Uğurlu, Serdar Süleyman Can, Zuhall Koç Apaydın, Semra Ulusoy Kaymak, Oğuz Peker, Serdar Süleyman Can, Zuhall Koç, Ali Çayköylü, Bedriye Özkan, Ali Güven Kılıçoğlu, Gül Karaçetin, Zeynep Yücehan, Tuğba Şerife Elmas, Dudu Demiröz, Nafiye Yağlı, Bilge Çetin İlhan, İbrahim Eren, Derya Adalı Aker, Yiğit Kivılcım, Mustafa Solmaz, Yeşim Ruhut Kutlu, Bahar Yeşil, Behice Han Almış, Başak Küçük, Cem Cerit, Burcu Sarici, Ayşe Ceren Kaypak, Erensu Baysak, Serhat Ergün, Mesut Yıldız, Aslihan Okan Ibiloglu, Abdullah Atli, Mehmet Asoglu, Mustafa Ozkan, Nursu Çakın Memik, Hatice Ünver, Özlem Yıldız Gündoğdu, Necati Uzun, Ömer Faruk Akça, Gizem Aral, Demet Sağlam Aykut, Özgür Maden, Mustafa İspir, İbrahim Gündoğmuş, Ayhan Algül, Servet Ebrinç, Fulya Gok, Seda Kiraz, Arif Cipil, Meliha Zengin Eroglu, Elvan Çiftçi, Zeynep Aslan, Melike Kevser Gül, Neslihan Taştepe, Esra Demirci, Sevgi Özmen, Hicran Doğru, Elif Karayağmurlu, Ali Karayağmurlu, Muhsine Göksu, Leyla Ezgi Tügen, Ayşe Burcu Ayaz, Ayşe Arman, Recep Başaran, Hatice Yardım Özayhan, Deniz Altunova, Dudu Demiröz, İbrahim Eren, Mustafa Çağrı Yıldız, Yasin Hasan Balcioglu, Simge Seren Kirioglu, Pinar Cetinay Aydin, Serdar Süleyman Can, Çağlar Soykan, Murat İlhan Atagün, Ali Çayköylü, Görkem Karakaş Uğurlu, Ayşegül Taşdelen Kul, Ekrem Gölbaş, Güler Göl, Uğur Savcı, Ali Evren Tufan, Seda Yıldırım Özbek, Süleyman Özbek, Hilal Uygur, Başak Demirel, İ. Esra Çiçek, İbrahim Eren, Hüseyin Kara, Mehmet Murat Balci, Servet Karaca, Mehmet Murat Kuloğlu, Hasan Mervan Aytaç, Mehmet Can Ger, Abdullah Atli, Aslihan Okan İbiloğlu, Mehmet Asoğlu, Ayşe Çakır, Demet Sağlam Aykut, Ahmet Tiryaki, Gülşah Güçlü Çelme, Mehmet Hamid Boztaş, Fatma Sırmatel, Yasin Hasan Balcioglu, Mucahid Erdogan, Cengiz Dayan, Hayrunisa Dilek Atakli, Gülşen Kartalcı, Ebru Yücel, Şükrü Kartalcı, Meliha Zengin Eroğlu, Arif Çipil, Mecit Çalışkan, Semra Ulusoy Kaymak, Görkem Karakaş Uğurlu, Oğuz Peker, Zuhall Koç, Murat İlhan Atagün, Ali Çayköylü, Emine Cengiz Çavusoglu, Yusuf Özyay Özdemir, Elvan Çiftçi, Abdullah Atli, Aslihan Okan İbiloğlu, Mehmet Asoğlu, Dudu Demiröz, Hatice Yardım Özayhan, Zeynep Yücehan, Tuba Şerife Elmas, İbrahim Eren, Ebru Fındıklı, Hasan Mervan Aytaç, Berkan Şahin, Koray Karabekiroğlu, Mustafa Kurt, Çağdaş Öykü Memiş, Bilge Doğan, Doğa Sevinçok, Levent Sevinçok, Merve Sertdemir, Ömer Faruk Akça, Doğa Sevinçok, Çağdaş Öykü Memiş, Bilge Doğan, Levent Sevinçok, Rukiye Ay, Nevzat Yılmaz, Sevcan Karakoç Demirkaya, Hatice Aksu, Hacer Gizem Gerçek, Gülser Karakoç, Ayşe Ender Altıntoprak, Hakan Coşkunol, İpek Percinel Yazici, Kemal Utku Yazici, Hicran Doğru, Seda Kiraz, Kevser Altıntaş, Fulya Gök, Meliha Zengin Eroğlu, Ferhat Yaylacı, Handan Özek Erkuran, Murat Eyüboğlu, Diğdem Göverti, Rabia Nazik Yüksel, Alper Bülbül, Makbule Çiğdem Aydemir, Erol Göka, İlgaz Kınalı, Münevver Yıldırım Hacıoğlu, Ayşe Ceren Kaypak, Burcu Sarıcı, Erensu Baysak, Serhat Ergün, Kemal Sayar, İbrahim Gündoğmuş, Mustafa İspir, Ayhan Algül, Servet Ebrinç, Hatice Doğan, Hatice Doğan, Sevda Bağ, Merve Çukurova, Ömer Akay, Çağatay Karşıdağ, İbrahim Gündoğmuş, Osman Bakkal, Ayhan Algül, Servet Ebrinç, Heecheol Kim, Hyunjoon Lee, Çağlar Soykan, Serdar Süleyman Can, Ali Çayköylü, Ayşegül Taşdelen Kul, Abdulkadir Karagöz, İbrahim Gündoğmuş, Hakan Kullakçı,

Özgür Maden, Ayhan Algül, Servet Ebrinç, Serdar Süleyman Can, Yasin Duman, Murat İlhan Atagün, Ayşegül Taşdelen Kul, Ali Çayköylü, Yusuf Çokünlü, Memduha Aydın, Tuba Şerife Elmas, İbrahim Eren, Ali Baran Tanrıkulu, Memduha Aydın, Tuba Şerife Elmas, Deniz Altunova, İbrahim Eren, Hande Ayraller Taner, Burcu Akın Sarı, Çiğdem Yektaş, Nuran Demir Samurcu, Ali Evren Tufan, Tuba Şerife Elmas, Saliha Çalışır, Memduha Aydın, Dudu Demiröz, Ali Baran Tanrıkulu, İbrahim Eren, Hakan Kullakçı, Mustafa İspir, Ayhan Algül, Servet Ebrinç, Mustafa İspir, İbrahim Gündoğmuş, Özgür Maden, Ayhan Algül, Servet Ebrinç, Özalp Ekinci, Muhammet Emin Tan, Merve Kalınlı, Murat Kıyanççek, İbrahim Gündoğmuş, Özgür Maden, Ayhan Algül, Meltem Küçükdağ, Çiğdem Yektaş, Hasret Karabulut Gül, Demet Sağlam Aykut, Emel Uysal, Filiz Civil Arslan, Emel Uysal, Demet Sağlam Aykut, Hasret Karabulut Gül, Evrim Özkorumak Karagüzel, Dudu Demiröz, Hatice Yardım Özayhan, Hilal Seven, Recep Başaran, Mustafa Çağrı Yıldız, İbrahim Eren, Burak Karakök, Halime Tuna Çak, Pınar Kızılay Çankaya, İlkay Keleş Altun, Eren Abatan, Emel Uysal, Yusuf Çokünlü, Tuba Şerife Elmas, Süleyman Özbek, Ali Metehan Çalışkan, İbrahim Eren, Hatice Kübra Çakı, Burak Doğan, Muhammed Tayyib Kadak, Mehmet Kefeli, Asiye Arıcı, Hatice Altun, Can Acıpayam, Pelin Çon Bayhan, Neslihan Taştepe, Melike Kevser Gül, Sevgi Özmen, Esra Demirci, Tuba Şerife Elmas, Saliha Çalışır, Ali Baran Tanrıkulu, Yusuf Çokünlü, Mustafa Çağrı Yıldız, Zeynep Yücehan, İbrahim Eren, Muhammet Emin Tan, Özalp Ekinci, İlkay Keleş Altun, Pınar Kızılay Çankaya, Emel Uysal, Elif Nurgül Sungur, Ayşe Nur İnci Kenar, Sevde Afife Ersoy, Mehmet Gürkan Gürok, Sevler Yıldız, Tuba Korucu, Denizhan Danaci Keles, Murad Atmaca, Esra Hoşoğlu, Ömer Faruk Akça, Kübra Kılınç, Barış Şen, Erdem Örnek, Cengiz Çelebi, Ayşe Sakallı Kani, Ömer Yanartaş, Zeynep Şenkal, Yıldız Akvardar, Kaan Kora, Ümrân Egilmez, Ali Kandeğer, Özkan Güler, Kemal Utku Yazıcı, Ipek Percinel Yazıcı, Selcen Doğru Köşker, Elif Ates Budak, Zeliha Deveci Karasin, Mehmet Diyaddin Güleken, Mustafa Celik, Ipek Percinel Yazıcı, Kemal Utku Yazıcı, Hande Yıldırım, Ayşe Ender Altıntoprak, Burçin Güler, Baybars Veznedaroğlu, Funda Lale, Halime Tuna Çak Esen, Gökür Haliloğlu, Bahar Yeşil, Behice Han Almış, Nuran Ekinci, Gamze Özçürümez Bilgili, Can Tuncer, Volkan Seneger, Rümeyza Yeni Elbay, Aynur Görmez, Ümit Işık, Gonca Aşut, Elif Tatlıdil Yaylacı, Ömer Asan, Erol Göka, Serkan Güneş, Bahar Yeşil, Ali Metehan Çalışkan, Ebru Çiftçi, Sehure Azra Yaşar, İkbâl İnanlı, İbrahim Eren, Kevser Altıntaş, Seda Kiraz, Sencan Sertçelik, Meliha Zengin Eroğlu, Osman Bakkal, İbrahim Gündoğmuş, Özgür Maden, Ayhan Algül, Servet Ebrinç, Abdullah Atli, Aslıhan Okan İbiloğlu, Mehmet Asoğlu, Selma Hilal Avcı, Aynur Görmez, Can Tuncer, Volkan Seneger, İbrahim Gündoğmuş, Mustafa İspir, Özgür Maden, Ayhan Algül, Servet Ebrinç, Kevser Altıntaş, Alişan Burak Yaşar, Sencan Sertçelik, Can Tuncer, Burcu Bakar, Hasan Turan Karatepe, Rümeyza Yeni Elbay, Melike Dönmez, Volkan Topçuoğlu, Ömer Yanartaş, Merve Sertdemir, Ayhan Bilgiç, Hicran Doğru, Volkan Doğru, Abdullah Bozkurt, Berkan Şahin, Koray Karabekiroğlu, Tuğba Kalyoncu, Deniz Argüz Çıldır, Can Beşer, Neşe Perdahlı Fiş, Serkan Güneş, Şermin Bilgen Ulgar, Hamza Ayaydın, Hatice Takatak, Hamza Ayaydın, Cansu Çobanoğlu, Mahmut Müjdecı, Berkan Şahin, Yusuf Yasin Gümüş, Merve Kalınlı, Özalp Ekinci, Serkan Güneş, Betül Akbaş, Ömer Faruk Akça, Hicran Doğru, Feyza Hatice Sevgen, Hatice Altun, Hasan Mervan Aytaç, Fatih Öncü, Nilfer Şahin, Damla Balkan, Fatma Coşkun, Savaş Yılmaz, Ömer Faruk Akça, Çağla Çelikkol, Savaş Yılmaz, Ganime Dilek Emlik, Hüseyin Çaksen, Derya Arslan, Özden Arısoy, Ahmet Şair, Yaşan Bilge Şair, Dilek Sarı, Mustafa İspir, Ayhan Algül, Servet Ebrinç, Vuslat Kara Ölmeztoprak, Esra Porgalı Zayman, Süheyla Ünal, Dudu Demiröz, Hatice Yardım Özayhan, Sehure Azra Yaşar, Ali Hakan Öztürk, İbrahim Eren, Başak Karabucak, Ebru Sadriye Çengel Kültür, Tuna Halime Çak Esen, Arif Çipil, Meliha Zengin Eroğlu, Alişan Burak Yaşar, Mecit Çalışkan, Ferhat Yaylacı, Handan Özek Erkuran, Meliha Zengin Eroğlu, Mecit Çalışkan, Seda Kiraz, Arif Çipil, Ipek Fatma Özaktaç, Murat Altın, Ayşe Sena Sarıdoğan, Eser Buluş, Alper Bülbül, Sevilay Güneş, Rabia Nazik Yüksel, Makbule Çiğdem Aydemir, Erol Göka, Hamza Ayaydın, Hatice Takatak, Zehra Koyuncu, Muhammed Tayyib Kadak, Rahime Hülya Bingöl, Burak Doğan, Mine Uzgel, Selahattin Ayas, Yüksel Kıvrak, Yiğit Şahbal, Kübra Kocagöz, Demet Sağlam Aykut, Gamze Kutlu, Ali Baz, Güler Göl, Ekrem Gölbaş, Mehmet Akif Cansız, Ali Evren Tufan, Deniz Argüz Çıldır, Tuğba Kalyoncu, Yasin Duman, Serdar Süleyman Can, Çağlar Soykan, Ayşegül Taşdelen Kul, Ebru Sağlam, Ömer Faruk Akça, Özlem Önen, Ayşe Kutlu, Handan Özek Erkuran, Handan Özek Erkuran, Ecnur Aydın Aşık, Şermin Yalın Sapmaz, Tuğba Kalyoncu, Deniz Argüz Çıldır, Serpil Erermiş, Hatice Ünver, Şahika Gülen Şişmanlar, İsmail Karka, Fethiye Kilicaslan, Mehmet Asoglu, Ceren Enüstün Hürmeydan, Özge Şahmelikoğlu Onur, Sevda Bağ, Suat Yalçın, Ozge Sahmelikoğlu Onur, Didem Nagehan Sarı, Bahar Kılıç, Elif Merve Kurt, İsmail Ak, Ali Emre Şevik, Ayşe Dilara Yalçın, Ümit Tural, Hilmi Yaşar, Serdar Süleyman Can, Yasin Duman, Ali Çayköylü, Şükrü Alperen Korkmaz, Gökem Karakaş Uğurlu, Ayşegül Taşdelen Kul, Yasin Hasan Balcioglu, Simge Seren Kirioglu, Guliz Ozgen, Deniz Altunova, Recep Başaran, Mustafa Çağrı Yıldız, Ali Baran Tanrıkulu, Münir Karaaslan, İbrahim Eren, Fatih Kizilağaç, Ümit Tural, Yusuf Tokgöz, Taner Öznur, Cemil Çelik, Özcan Uzun, Ali Baran Tanrıkulu, Mustafa Çağrı Yıldız, İkbâl İnanlı, Tuba Şerife Elmas, Yusuf Çokünlü, Seher Serez Öztürk, Hilal Seven, Dudu Demiröz, Seda Özbek, İsmet Esra Çiçek, İbrahim Eren, Esra Porgalı Zayman, Rifat Karlıdağ, Mustafa Akan, Lara Utku İnce, İsmail Reyhani, Dilek Çağlar Tetik, Ayşe Büyükaslan, Musa Yılanlı, Ender Cesur, Sevda Bağ, Çağatay Karşıdağ, Yasin Hasan Balcioglu, Simge Seren Kirioglu, Fatih Oncu, Fatma Belger, Bürge Kabukçu Başay, Volkan Seneger, Can Tuncer, Hasan Turan Karatepe, Aynur Görmez, Cansu

Pinar Şen, Mehmet Fatih Ceylan, Selma Tural Hesapcioglu, Tuba Şerife Elmas, Saliha Çalışır, Ali Metehan Çalışkan, Ali Baran Tanrikulu, İbrahim Eren, Aslıhan Okan İbiloğlu, Abdullah Atli, Mehmet Asoğlu, Mustafa Ozkan, Özge Şahmelikoğlu Onur, Ender Cesur, Gülşen Teksin, Suat Yalçın, Sevda Bağ, Serkan Güneş, Ali Metehan Çalışkan, Ebru Çiftçi, Sehure Azra Yaşar, İkbâl İnanlı, İbrahim Eren, Erensu Baysak, Nese Yorguner Kupeli, Serhat Ergun, Kaan Kora, Mehmet Asoğlu, Hatice Takatak, Abdullah Atli, Aslıhan Okan İbiloğlu, Mehmet Asoğlu, Öznur Akıl, Abdullah Atli & Aslıhan Okan İbiloğlu (2017) 9th International Congress on Psychopharmacology & 5th International Symposium on Child and Adolescent Psychopharmacology, Psychiatry and Clinical Psychopharmacology, 27:sup1, 85-180, DOI: [10.1080/24750573.2017.1308709](https://doi.org/10.1080/24750573.2017.1308709)

To link to this article: <https://doi.org/10.1080/24750573.2017.1308709>



© 2017 The Author(s). Published by Informa UK Limited, trading as Taylor & Francis Group



Published online: 18 May 2017.



Submit your article to this journal [↗](#)



Article views: 3398

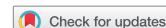
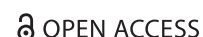
View related articles [↗](#)



View Crossmark data [↗](#)

CASE REPORTS PRESENTATIONS



## 9th International Congress on Psychopharmacology & 5th International Symposium on Child and Adolescent Psychopharmacology

Abstract:0040

### The First Episode of Psychosis with Intense Occupation of Reiki

Özge Şahmelikoğlu Onur, Merve Çukurova, Sevda Bağ, Suat Yalçın, Cansu Çakır Şen and Çağatay Karşıdağ

Bakırköy Research and Training Hospital for Psychiatry, Neurology, and Neurosurgery, 3rd Psychiatry Department, Istanbul, Turkey

E-mail address: [ozge\\_sahmelikoglu@hotmail.com](mailto:ozge_sahmelikoglu@hotmail.com)

#### ABSTRACT

It is suggested that in case of blockage in an energy center, illness or imbalance may occur and it may be treated by touching by hand according to Reiki. In this case, the first episode of psychosis with intense occupation of reiki will be presented. A 57 year-old woman presented with the complaints of auditory hallucinations, decreased need for sleep, and skepticism. In psychiatric examination; poor self-care, irritable affect, decreased psychomotor activity, flight of associations, mystic delusions, and auditory illusions were noted. It was her first psychiatric administration and her complaints were exacerbated 10 days ago. According to her family, the patient, who has no intimate friendship, has been busy with reiki for 4 years. As the level of reiki goes up, the patient, who predicts the increase of the auditory hallucinations as a reward, has tried to heal the patients through the energy and has tried to eat the earth and to throw herself from 3 meters high. For a possible organic etiology, no pathological findings were found in the results of the blood tests and cranial MRI. Haloperidol 20 mg/day, biperidene 4 mg/day quetiapine 100 mg/day was recommended for the patient who was diagnosed as atypical psychosis. Within a week, her complaints were down. The beginning of the psychotic manifestations of our case, such as hearing the voices, may suggest that a mission like healing in this ritual leads the patient to a psychotic life. From another point of view, the fact that the patient's introverted prodromal period may suggest that there is a psychotic pattern with negative symptoms in the beginning, and perhaps the patient may turn to this area for self-medication. It may be appropriate to evaluate Reiki healing technique from the perspective of psychosis in addition to healing activity.

#### KEYWORDS

Reiki; psychosis; first episode; healing

Abstract:0062

### A Case of Intentional Tremor-Induced by Aripiprazole Treatment

Serdar Süleyman Can, Emine Tuğçe Akçaer and Ayşegül Taşdelen Kul

Department of Psychiatry, Yıldırım Beyazıt University, Ankara, Turkey

E-mail address: [aysegul.tsdl04@hotmail.com](mailto:aysegul.tsdl04@hotmail.com)

#### ABSTRACT

Aripiprazole is an atypical antipsychotic which has unique pharmacologic action. The mechanism of aripiprazole in psychotic disorders has not been fully elucidated but from a pharmacological view, aripiprazole is different to other antipsychotic agents, as it is the only approved antipsychotic that reduces dopaminergic neurotransmission through D2 partial agonism. As partial agonist at D2 receptors, it modulates neurotransmission in dopaminergic pathways especially in mesolimbic and mesocortical pathway. Aripiprazole might decrease activity in the mesolimbic pathway through partial D2 agonism, which would in turn reduce positive psychotic symptoms. Because of this action it is expected that aripiprazole treatment rarely cause extrapyramidal adverse events. But recently it is shown that aripiprazole has parkinsonian side effects and dyskinesia other than akathisia. Intention tremor is an involuntary trembling of the body or limbs; it may have either a physical or a psychological cause. Early symptoms of intention tremor include trembling of the hands and nodding of the head. Tremors are often associated with Parkinson's disease, which affects nerve centers in the brain that control the muscles. Here we describe a case of intention tremor induced by aripiprazole treatment. 42 year-old female patient suffering from psychotic disorder was

#### KEYWORDS

Aripiprazole; intention tremor; psychotic disorder



put on aripiprazole 15 mg/day. After aripiprazole treatment her disorganized behavior improved but still had significant psychotic features. Then dose of aripiprazole increased to 30 mg per day. 1 week later she developed lateralized intentional tremor. Lorazepam 2 mg/day is added her treatment and the patient was completely without tremor. In conclusion, although aripiprazole is less associated with extrapyramidal system side effects compared to other atypical antipsychotics; careful observation is needed for the development of extrapyramidal adverse effects in patients treated with aripiprazole.

Abstract:0064

## Olanzapine-Induced Delayed-Onset Oculogyric Crisis

Mustafa İspir, Osman Bakkal, Ayhan Algül and Servet Ebrinç

Department of Psychiatry, Haydarpaşa Sultan Abdulhamid Training and Research Hospital, Istanbul, Turkey

E-mail address: [mispirkadirli@gmail.com](mailto:mispirkadirli@gmail.com)

### ABSTRACT

Olanzapine is an atypical antipsychotic drug that is very effective and has weak potential for extrapyramidal adverse effects. Oculogyric crisis (OGC) is an acute dystonic reaction that usually occurs after initiation of antipsychotic treatment, characterized by spasmodic deviations of the eyes, lasting for a few minutes to several hours. Among the atypical antipsychotics, cases of olanzapine, clozapine and ziprasidone-induced acute OGC have been reported. As far as we know a few cases have been reported about delayed onset or tardive OGC with olanzapine. We reported a case of olanzapine-induced OGC that started after 1 month of initiation of the treatment and improved addition of oral biperiden. In the case of OGC, there was a great response to low-dose anticholinergic at one week. In the literature, there is medical case of dystonia due to the long-term usage of olanzapine and case of tardive dystonia which was not responding to anticholinergics, and the cases of OGC appeared in the first one or two days. The distinctive feature of our case is the appearance of the situation after a month, and responded in a week after supplementation of anticholinergics. The certain mechanism of neuroleptic-induced OGC is just unclear and possibly attributable to higher striatal inhibition of dopamine function or higher dopamine-acetylcholine antagonism. Considering recovery of OGC with anticholinergics, a dopamine deficiency and acetylcholine excess may be implicated, for OGCs. However, why some cases develop acute and, others, tardive OGCs is not known. It is hypothesized that sensitizing effect of striatum from past antipsychotic exposures may contribute toward delayed of OGC. But our case was the first episode psychosis. In conclusion, although possibility of such a side effect is weak, clinicians should be known with this side effect and alert to early detection and rapid initiation of treatment.

### KEYWORDS

Olanzapine; oculogyric crisis; side effect

Abstract:0067

## A Rare Presentation of Delusional Parasitosis

Serdar Süleyman Can and Ayşegül Taşdelen Kul

Department of Psychiatry, Yıldırım Beyazıt University, Ankara, Turkey

E-mail address: [aysegul.tsdln04@hotmail.com](mailto:aysegul.tsdln04@hotmail.com)

### ABSTRACT

Delusional parasitosis is a rare psychiatric disorder which is characterized by the fixed and false belief as the person's body is infected with parasites or other living organisms. Visual or tactile hallucinations consistent with thought content can accompany the delusions. It has been typically reported in elderly women. In this report, a 76-year-old woman who had thoughts about lice that were strolling on her scalp's very limited area and tactile and auditory hallucinations, who subsequently remitted with low dose trifluoperazine was presented. A 76 year-old female patient came with the complaints of disturbed sleep because of itching due to lice infestation for two years. She had thoughts about that lice were on her scalp and tactile hallucination about lice that were strolling. She believed that lice were only on one limited area less than 4 cm in diameter on the left side on her scalp. She was also hearing voices of crunching as lice cracked whenever she pressed on that area. She visited several dermatologists. There were secondary lesions, erythematous changes and scratch excoriations marks were seen over the limited region. After ruling out organic diseases and other psychiatric disorders, trifluoperazine treatment was started 1 mg/day and dosage was

### KEYWORDS

Delusional parasitosis; hallucination; tactile



increased to 2 mg/day. During the control visits, it was observed that patient did not mention about lice; she stopped picking her skin; and number of skin lesions was decreased in a short-time about 2-3 months. In conclusion, rare presentations of delusional disorders are essential for differential diagnosis in clinical practice.

Abstract:0071

## A Paranoid Psychosis Case After Chronic Subdural Hematoma: A Case Report

Cihad Yükselir<sup>a</sup>, Serkan Zincir<sup>b</sup>, Pelin Öztürk<sup>c</sup> and Bülent Karaahmetoğlu<sup>d</sup>

<sup>a</sup>Psychiatry Clinic, Atatürk Hospital, Balıkesir, Turkey; <sup>b</sup>Psychiatry Clinic, Necati Çelik Hospital, Golcuk, Kocaeli, Turkey; <sup>c</sup>Department of Psychiatry, Erenköy Teaching and Research Hospital for Neurological and Psychiatric Disorders, Istanbul, Turkey; <sup>d</sup>Psychiatry Clinic, Çukurova Dr. Aşım Tüfekçi Hospital, Adana, Turkey

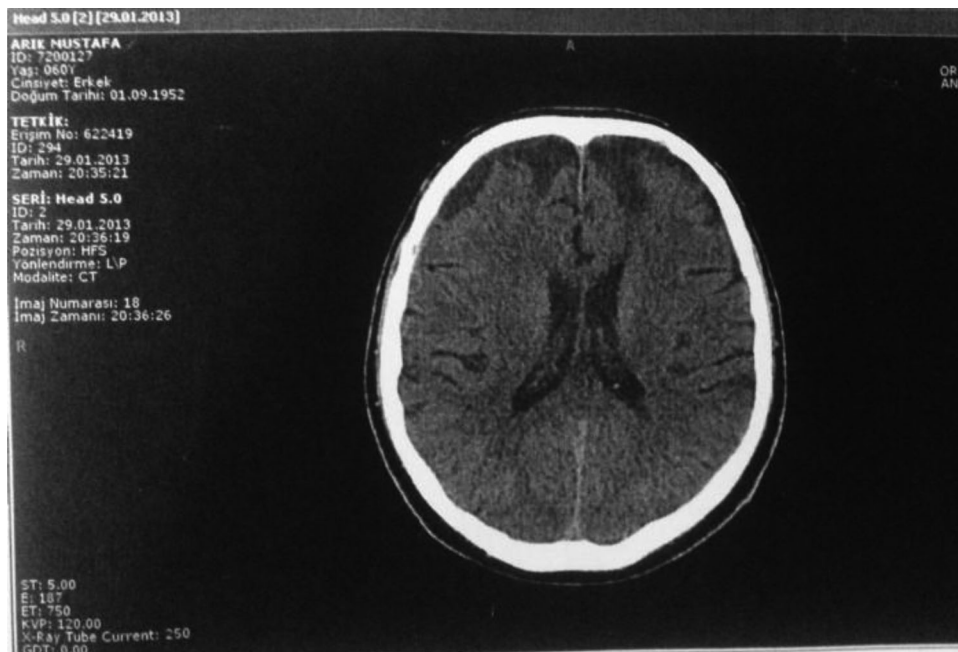
E-mail address: [dr.c.yukselir@gmail.com](mailto:dr.c.yukselir@gmail.com)

### ABSTRACT

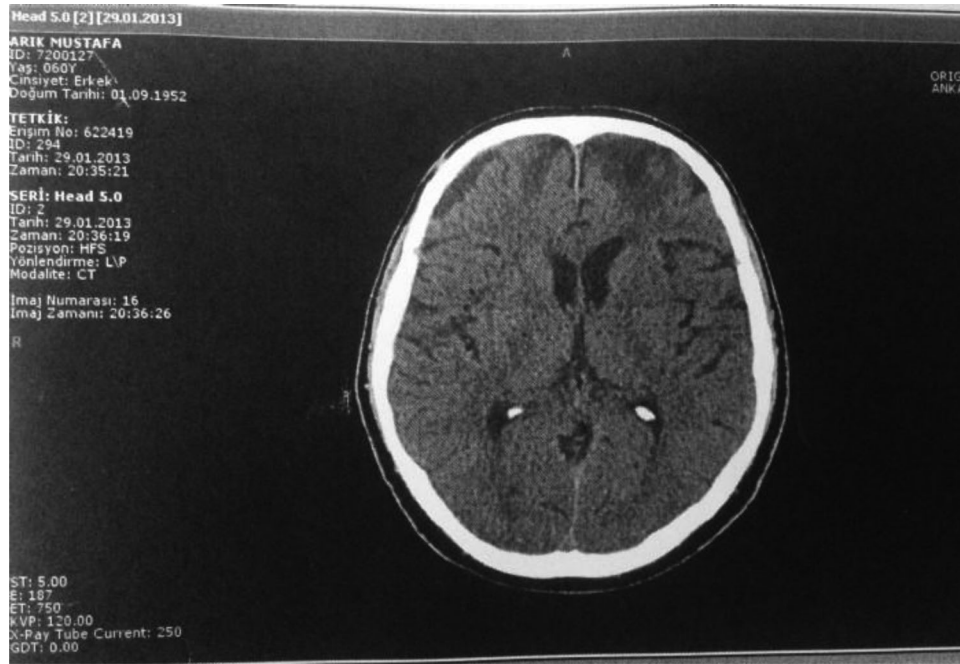Head trauma is the most common reason of subdural hematoma. Subdural hematomas can impair the function of the brain, either directly or indirectly by pressing. It may cause neurological or cognitive impairment, also organic personality changes and psychotic disorders. 63 year-old truck driver male patient had a head trauma three months ago. His family complained about his headache, confusion, forgetfulness, irritability, aggression, disorganized speech and behavior. Chronic subdural hematoma areas were found in CT of his brain. There were no neurological deficits. In his psychiatric examination; he had hypomnesic consciousness, visual hallucinations, delusions of persecution and reference, his memory and also his objective and subjective judgments were distorted, he had blunted affect. He was diagnosed with psychotic disorder due to subdural hematoma according to DSM 5 criteria. He had benefited from the treatment of risperidone 2 mg/day. His behavioral pathologies and delusions were partially improved. SAPS total score was decreased from 62 to 25, BPRS total score was decreased from 52 to 17 in two months. The frontal lobe syndrome which due to the frontal lobe damage, clinical view varies according to the settlement and the dimension of the lesion. If the lesion is located in convexity part of the frontal lobe, indifference against the around, unresponsiveness, nonchalance and apathy occur in the patient. Disinhibition, aggression, social disharmony and sexual inappropriate behaviors can be seen if the lesion is located in the orbito-frontal region. Impairment in executive functions such as loss of ability to show initiative, goal setting, planning, selection of appropriate answering, following continuing behavior and lack of interest, social maladjustment, impulse control disorders, and obsessive behavior are common clinical manifestations. In addition to these symptoms, the presentation of psychosis can be seen in frontal lobe damage. While investigating the etiology of psychotic disorders, head trauma should be questioned.

### KEYWORDS

Subdural hematoma; head trauma; paranoid psychosis; frontal lobe syndrome



**Figure 1.** Chronic subdural hematoma on CT of the head.



**Figure 2.** Chronic subdural hematoma on CT of the head.

Abstract:0082

## Psychotic Attack Due to Hypothyroidism: A Case Report

Özlem Baş<sup>a</sup>, Özge Şahmelikoğlu Onur<sup>b</sup> and Sema Ulukaya<sup>a</sup>

<sup>a</sup>Bakırköy Research and Training Hospital for Psychiatry, Neurology and Neurosurgery, 4th Psychiatry Department, Istanbul, Turkey;

<sup>b</sup>Bakırköy Research and Training Hospital for Psychiatry, Neurology and Neurosurgery, 3rd Psychiatry Department, Istanbul, Turkey

E-mail address: [ozge\\_sahmelikoglu@hotmail.com](mailto:ozge_sahmelikoglu@hotmail.com)

### ABSTRACT

Endocrine system diseases, especially thyroid hormone abnormalities may cause psychiatric complaints or may increase existing complaints. In the literature review there were psychosis-delirium in 5%, anxiety disorders in 20–33%, cognitive impairment in 29% and major depression in 33–44% of hypothyroidism cases. In this report we present a case of psychotic attack due to hypothyroidism. 78 year-old married, male, American patient presented to our clinic with the complaints of excitation, disorganized speech and behaviors. In his psychiatric examination decreased self-care, increased psychomotor activity, decreased amount of speech, auditory and visual hallucinations and grandiose delusions were noted. He thought that he had a mission for finding Noah's ship and he had come to Turkey for looking for Noah's ship. No significant pathology was detected in urine toxicology and brain MRI. In the laboratory tests TSH: 18.60 (high) and T4: 0.883 (low) were detected. No significant pathology was detected in thyroid autoantibodies tests and thyroid USG. He was diagnosed with psychotic attack due to hypothyroidism. By the direction of internal medicine consultation he was ordered levothyroxine sodium 50 mcg/day. He was ordered haloperidol 15 mg/day (i.m.) and biperidene 5 mg/day (i.m.). On the 5th day of levothyroxine, due to remission of the patient's complaints, antipsychotic treatment was discontinued. Clinically improved patient was discharged with levothyroxine sodium 50 mcg/day. Many psychiatric disorders, such as mild cognitive impairment, depression and psychotic disorders can occur due to hypothyroidism. Thyroid hormone disorders should be investigated in all psychiatric cases regardless of age, especially those with sudden onset, no history of psychiatric illness in history and/or family history.

### KEYWORDS

Hypothyroidism; psychosis; thyroid hormone

Abstract:0093

## Clozapine Intoxication: A Complicated Case

Serdar Süleyman Can, Çağlar Soykan, Ali Çayköylü and Ayşegül Taşdelen Kul

Department of Psychiatry, Yildirim Beyazıt University, Ankara, Turkey

E-mail address: [aysegul.tsldn04@hotmail.com](mailto:aysegul.tsldn04@hotmail.com)

**ABSTRACT**

Clozapine is an atypical antipsychotic used for treatment resistant schizophrenia. Clozapine toxicity may cause altered levels of consciousness, delirium, coma, seizures, tachycardia, arrhythmias, hypotension, pancreatitis, hepatitis, cardiac arrest, aspiration, and respiratory depression. We report a case receiving clozapine for treatment of schizophrenia who presented to the Outpatient Clinic with reduced level of consciousness. 56 years old, female patient diagnosed with paranoid schizophrenia for 32 years presented to our psychiatry clinic with the symptoms of lethargy, disorientation, irritability, dysarthria, tremor, ataxia and fever. She was on clozapine 500 mg/day and valproic acid 1000 mg/day for past two years. The patient's relatives reported a clinically similar period 6 months ago while on clozapine. Patient received a consultation from an infectious disease physician and infectious agent was not suspected. Complete blood count and ECG demonstrated no pathological findings. Cranial MRI performed on the day of admission showed subdural hematoma in the region of left frontoparietal area. Neurosurgery service was consulted, and recommended no surgical intervention at this time. Lesion was described as a chronic hematoma. Her laboratory test revealed that serum valproic acid level was 88 mg/dL and serum clozapine level was 910 µg/L. Her clozapine treatment was reduced to 150 mg/day. During clinical follow-up, her vital signs remained stable, patients confusion disappeared, her consciousness improved, her speech and comprehension improved, her attention normalized gradually. Clozapine levels greater than 600–1000 µg/L were more likely to cause adverse effects. Clozapine blood levels are influenced by, gender, age, physical illnesses changes in the activity of the cytochrome oxidase enzymes because of genetic variability, concurrent medication use. We believe that the symptoms in our patient are related to intoxication of clozapine. In conclusion, clozapine blood level measurements should be considered if a patient experiences neurological symptoms.

**KEYWORDS**

Blood level; clozapine; intoxication

Abstract:0108

## A Psychosis Case Triggered by Protein Powder on the Context of Body Dysmorphic Disorder

Neslihan Yazar, Zehra Başar Kocagöz, Adnan Özçetin, Safiye Bahar Ölmez and Ahmet Ataoğlu

Department of Psychiatry, Düzce University School of Medicine, Düzce, Turkey

E-mail address: [nyazar91@gmail.com](mailto:nyazar91@gmail.com)

**ABSTRACT**

Body dysmorphic disorder (BDD) is a mental disorder characterized by dealing with an imaginary defect in one's own appearance or struggling a small physical defect heavily. In this study, we will present a case who had BDD and who has experienced psychosis attack due to NSCPP use.

A 26-years-old male patient. He had complaints that involve not meaningful speech and behaviors, self-harm attempts for a month. The patient has not had any psychiatric follow-up and treatment in the past. In his history, he had used NSCPP intensively in the last three months. In his mental status examination, his emotional state was dysphoric. Regarding the content of his thought, he had somatic delusion that contains grandiosity, and thoughts about reference and persecution. His sleep duration, insight and judgment had decreased. There was no pathological sign on his cranial MRI. Also, no psychoactive substances were detected. At the eleventh day we added Risperidone 2 mg/day to and increased the dosage 3 mg/day later on. In the twenty-second day, he had somatic delusion that contains grandiosity. Hence, we added Valproic Acid 500 mg/day. At the thirty-third day, we discharged the patient from the clinic, because his thought disorders quite decreased, he seemed to regain his functionality, and his insights increased substantially. After his discharge there was no sign observed for any psychosis in his follow-ups. Nowadays, nutrient supplements that may contain amino acids like taurine, arginine, glutamine or omega 3 fatty acids, vitamins and minerals. It has been known that taurine has an impact on dopaminergic transmission and it can cause psychosis symptoms as in our case. our patient had psychosis secondary to overuse of NSCPP as well. In the literature, to our knowledge, there does not exist any study reported in the literature that demonstrates psychosis after NSCPP use.

**KEYWORDS**

Nutrient supplement; protein powder; taurine; psychosis; body dysmorphic disorder

Abstract:0146

## Electroconvulsive Therapy in Schizophrenia with Coincidental Choroidal Fissure Cyst: A Case Report

Yasin Hasan Balcioglu<sup>a</sup>, Tonguc Demir Berkol<sup>a</sup>, Filiz Ekim Cevik<sup>b</sup>, Fatih Oncu<sup>a</sup> and Guliz Ozgen<sup>a</sup><sup>a</sup>Department of Psychiatry, Bakirkoy Prof. Dr. Mazhar Osman Training and Research Hospital for Psychiatry, Neurology and Neurosurgery, Istanbul, Turkey; <sup>b</sup>Department of Medical Sciences, Institute of Forensic Sciences, Istanbul University, Istanbul, TurkeyE-mail address: [yasinhasanbalcioglu@bakirkoyruhsinir.gov.tr](mailto:yasinhasanbalcioglu@bakirkoyruhsinir.gov.tr)

### ABSTRACT

Choroidal fissure cysts (CFC) are often incidentally identified and generally regarded not to present with overt clinical signs. To the best of our knowledge, any case report of a psychosis with coincidental CFC has not been published before in the literature. Electroconvulsive therapy (ECT) has been frequently considered relatively contraindicated in patients with space-occupying lesions in the brain, however, in last few years, increased numbers of case reports encourage clinicians to treat drug-resistant psychiatric patients with ECT. In this article, we present a schizophrenia case with a coincidental CFC, who benefited from ECT. A 21 year-old male patient hospitalized due to paranoid and somatic delusions, auditory hallucinations, sleeplessness and aggression directed to his parents, despite being under regular medication with aripiprazole and quetiapine for four months. CFC was seen in MRI scan, in right lateral ventricle, by the temporal horn. Neurological examination has not revealed any intracranial pressure signs. Despite antipsychotic injections for 10 days, psychotic and aggressive symptoms had not regressed. Bilateral, modified ECT was administered in nine sessions without any complication. Symptomatic remission was observed and maintenance antipsychotic medication lined up after discharge. Current guidelines suggest to be deliberate in the administration of ECT, in the presence of space-occupying lesions. ECT may lead side effects by increasing intracranial pressure on the patients, including rupture of cystic lesions. However, recent publications stated that ECT could be used safely in patients with cystic lesions which don't cause edema or intracranial pressure increase. This report supports the safety and efficacy of ECT in the treatment of psychiatric disorders accompanied by intracranial structural lesions, nevertheless, the ECT option should be approached cautiously and the opinion of neurosurgeons should be taken by calculating the benefit-loss ratio.

### KEYWORDS

Choroidal fissure cyst;  
electroconvulsive therapy;  
schizophrenia

Abstract:0158

## Combination of Neuro-Behçet Disease and Psychosis

Dudu Demiröz, Hatice Yardım Özeyhan, Hilal Seven, Mustafa Çağrı Yıldız, Recep Başaran and İbrahim Eren

Department of Psychiatry, Konya Research and Training Hospital, Konya, Turkey

E-mail address: [drdemiroz42@gmail.com](mailto:drdemiroz42@gmail.com)

### ABSTRACT

Behçet's disease is a rare immune-mediated small-vessel systemic vasculitis. Triple-symptom complex of recurrent oral aphthous ulcers, genital ulcers, and uveitis are seen in Behçet disease. The Behçet disease with neurological involvement, Neuro-Behçet's disease (NBD), involves central nervous system damage in 5–50% of cases. In addition to these; psychiatric disorders can be seen frequently. Psychiatric symptoms are seen 8–50% in these patients. Also there is a subgroup which is named as neuro-psychobehçet whose symptoms are loss of insight, disinhibition, psychomotor agitation and retardation, euphoria, obsessive thoughts, paranoid behavior. The combination to Neuro-Behçet disease and delusional disorders frequency is lower in literature. In this report we presented case about combination of neuro-behçet disease and delusional disorders. The patient who is man has some complaint like suspiciousness, irritability, aggression, insomnia and delusional jealousy. These symptoms are increased almost one months and disturb him so he presented to the psychiatric outpatient clinic. In 2000; because of blurred vision oral aphthous ulcers, genital ulcers he has gone to doctor and diagnosed as a Behçet disease. The doctor prescribes him colchicine. During 2 years; suspiciousness, irritability, aggression complaint are progressing. Oral risperidone was ordered as medication. Psychotic symptoms are regressed with this medication and disease in remission now. The information about combination of neuro-behçet disease and delusional disorders are obtained from some case reports in literature. Psychiatric problems are mostly seen in Behçet disease the reason of this situation is not clear. Some kinds of proinflammatory cytokines like IL-1 beta, IL-8 and TNF alfa may

### KEYWORDS

Neuro-Behçet disease;  
psychosis; risperidone

influence the activity of neuroendocrine system which increases the predisposition of psychiatric disease. The patients whose diagnosis is Bechet disease have important psychiatric problems. So; these patients must be examined by psychiatrist during clinical follow-up and must be treated for psychiatric disease.

Abstract:0162

## A Case of Late Onset Post-Stroke Psychosis

Elif Özlem Canazlar, Levent Sevinçok, Bilge Doğan and Çağdaş Öykü Memiş

Department of Psychiatry, Adnan Menderes University, Aydın, Turkey

E-mail address: [eoc\\_eoc@hotmail.com](mailto:eoc_eoc@hotmail.com)

### ABSTRACT

The most common post-stroke neuropsychiatric symptoms are related to depression and anxiety, while delusions and hallucinations are rarely seen. There are a few reports describing stroke related psychotic symptoms. In most of them, psychosis appeared until the third day of stroke. Here we report a patient who developed psychosis seven months after a stroke. A 37 year-old female was presented to psychiatry department with the complaints of auditory and visual hallucinations, persecution delusions which appeared four days ago. She reported that she had her first stroke seven months ago. Her Magnetic Resonance Imaging of the brain taken within the first week of stroke revealed a subacute infarct at left frontotemporal region, and also a hematoma at left frontal white matter. She had no previous history of medical or psychiatric disorders. At initial psychiatric assessment, she had referential and persecutory delusions; auditory and visual hallucinations. The initial scores of SANS and SAPS were 17, and 40, respectively. Following a 5 mg/day haloperidol treatment, her scores totally disappeared (SANS:0, SAPS:0). Psychosis after stroke is relatively rare when compared to anxiety and affective disorders. A study reported that the rate of psychosis along 12 years after strokes was 6.7%. Moreover, psychosis develops at earlier stages in most of the post-stroke patients. To our knowledge, our case is the first who developed psychosis at such a relatively late time. Previous studies found an association between auditory hallucinations and hyperactivity at right frontal regions. Particularly impairments in connectivity at right frontal lobes are considered important in development of psychosis. Surprisingly, our case had auditory hallucinations and delusions following a left-sided lesion. Our case might demonstrate that post-stroke psychosis might be both late-onset and also be related to an atypical lesion localization.

### KEYWORDS

Post stroke; psychosis; late-onset

Abstract:0189

## Aripiprazole-Induced Oculogyric Crisis

Ali Baran Tanrikulu, İkbâl İnanlı, Mustafa Çağrı Yıldız, Tuba Şerife Elmas and Ibrahim Eren

Psychiatry Clinic, Konya Training and Research Hospital, Konya, Turkey

E-mail address: [dr.floyd9@yahoo.com](mailto:dr.floyd9@yahoo.com)

### ABSTRACT

Oculogyric crisis (OGC) is a rare neurologic manifestation characterized by sustained dystonic, conjugate and typically upward deviation of the eyes lasting from seconds to hours. OGCs have been reported in association with numerous conditions for example neurometabolic and neurodegenerative movement disorder, drug-induced and consequence of focal brain lesions. The common basis of these disorders is a metabolic, anatomical or functional disruption of the nigrostriatal pathway, mainly of dopamine metabolism. The most frequent reason of OGC is antipsychotic medications. In this report we presented a case of oculogyric crisis induced by aripiprazole. A 40 year-old married female was brought by her relatives to the psychiatry clinic complaints of irritability, visual hallucinations, sleep disturbances, paranoid delusions, and religious delusions. In patient history along 12 years, there are lots of stays in hospital with schizophrenia diagnosis. She used lots of medicines like risperidone, olanzapine, biperidene, clonazepam, mirtazapine, clozapine in abroad. She had treatment adherence problem in this time because of side effects of drugs. We started with 5 mg/day oral aripiprazole. After 2 weeks we titrated 30 mg/day. After 1 week administration of 30 mg/day aripiprazole she presented with involuntary upward deviation of the eyes and visual hallucination about holy book Arabic writing on ceiling. This state was relieved

### KEYWORDS

Aripiprazole; oculogyric crisis; side effect



spontaneously. After that we reduced and ceased oral aripiprazole. We switched therapy to clozapine. She stayed in hospital for 6 weeks. In this 6 weeks OGC did not reappear. As a partial agonist of D2 receptors aripiprazole has low propensity for extrapyramidal side effects include oculogyric crisis. OGC occurred after 3 weeks administration of aripiprazole. And we reduced and ceased oral aripiprazole. Introduction of a new agent or increasing of an existing agent may associated with risk of OGC. In conclusion, case outlines a significant side effect of aripiprazole, which clinician should be vigilant about initiating the medication.

Abstract:0201

## Postictal Psychosis Developing After An Epileptic Seizure in Adolescent: A Case Report

Şükrü Alperen Korkmaz<sup>a</sup>, Cansu Pınar Şen<sup>b</sup>, Mehmet Fatih Ceylan<sup>b</sup> and Selma Tural Hesapçıoğlu<sup>b</sup>

<sup>a</sup>Department of Psychiatry, Yildirim Beyazıt University, Ankara, Turkey; <sup>b</sup>Department of Child and Adolescent Psychiatry, Yildirim Beyazıt University, Ankara, Turkey

E-mail address: [fatihceylan80@yahoo.com](mailto:fatihceylan80@yahoo.com)

### ABSTRACT

Psychological disorders are frequently encountered in children with epilepsy. The prevalence of psychotic disorders in patients with epilepsy is known as 2–7% while for postictal psychosis consists one quarter of epileptic psychosis. In this case, we present a 14-year-old patient who had a psychotic episode that occurs six days after the epileptic seizure. A 14 year-old boy, who had neither psychiatric nor neurologic complaints before, experienced generalized tonic epileptic seizure with loss of conscious and whole body contraction for 5–6 minutes and followed by postictal confusion. Postictal EEG had shown secondary generalized epileptic discharges originated from frontal lobe. In consideration of clinical finding and EEG report, the disease was diagnosed as epilepsy and divalproex 1000 mg/day treatment had been started. Six days after the seizure, he had started to think that his mother would poison him, terror organizations were working for him and his mother had relationships with other men. Besides he said that he was hearing voices, saying his headmaster should not communicate with his family. Since organic reasons were excluded, risperidone had been started and increased to 3 mg/day gradually. Although the regular use of drugs, there was no change in symptoms. He applied to our out-patient clinic, in the examination delusions of persecutory, delusions of grandiosity and command auditory hallucinations had been observed to continue. His treatment was changed with olanzapine 10 mg/day. Within 3 weeks after alteration of treatment, recovery had been observed in psychotic symptoms. It is known that postictal psychosis generally seen in people who have epileptic seizure for more than 10 years and the seizures are often originated from temporal lobe. Our aim in this case, which had a psychotic episode just after the diagnosis of epilepsy and the fact that seizures originated from frontal lobe, to make a contribution to the literature.

### KEYWORDS

Adolescent; epileptic psychosis; epileptic seizure; postictal psychosis

Abstract:0224

## Variation in Hyperprolactinemia and Its Impact on Prognosis of Schizophrenia

Burcu Bakar, Can Tuncer, Rümeyza Yeni Elbay and Aynur Görmez

Department of Psychiatry, Istanbul Medeniyet University, Istanbul, Turkey

E-mail address: [burcubakar00@hotmail.com](mailto:burcubakar00@hotmail.com)

### ABSTRACT

The variation in different levels of hyperprolactinemia might have different implications on psychiatric treatment of schizophrenia. However the reasons of the variability of high prolactin (PRL) levels are unclear. There were studies into the PRL response to antipsychotics (APs) as a 'biomarker' D2 blockade that made it even more complicated. There are effects of tuberoinfundibular dopamine neurons in the arcuate nucleus of the hypothalamus on PRL secretion from the anterior pituitary; however, according to Kapur et al. atypical APs responses, regarding high PRL levels, were very challenging indeed. 35 year-old, male patient suffering from schizophrenia, and mild mental retardation, presented with the symptoms of worsening effects of fatigue, tiredness, withdrawal, lack of energy, and long hours of sleep in the last 2–3 months. His current treatment included paliperidone-palmitate, clozapine and

### KEYWORDS

Antipsychotics; neuroradiology; prolactin; prolactinoma; schizophrenia; side-effect

carbamazepine. His PRL level was found abnormal (PRL ng/ml, normal range 3–19 ng/ml). Further investigations including MR of brain, revealed micro-adenoma. After stopping carbamazepine PRL level was 38 ng/ml and then increased again to 67 ng/ml. Three weeks later psychotic symptoms were precipitated and then clozapine dosage was increased. Patient's regular follow-up with PRL levels and six monthly neuroradiological investigation of pituitary are carried out. The modest variations in hyperprolactinemia and the course of psychotic symptoms were assessed together. There were mix messages about PRL levels and the worsening of psychotic symptoms. The other important aspect of variation in hyperprolactinemia is when to look for neuroradiological investigation to rule out prolactinoma. Although there is awareness of significance of hyperprolactinemia in schizophrenia, it is challenging to understand how these different levels are related with prognosis of schizophrenia and also evidence of prolactinoma. Last but not the least the, PRL side effects of atypical APs are still in need of understanding whether these are dose-related or not.

Abstract:0225

## N-Acetylcysteine Augmentation in a Patient with Leukopenia

Yusuf Tokgöz, Abdullah Bolu, Cemil Çelik and Özcan Uzun

Department of Psychiatry, Health Sciences University, Ankara, Turkey

E-mail address: [tbptokgoz@gmail.com](mailto:tbptokgoz@gmail.com)

### ABSTRACT

N-acetylcysteine, a glutathione (GSH) precursor, is a pharmacologic agent used in clozapine augmentation therapy. While NAC has glutamatergic, neurotropic and inflammatory pathway modulating characteristics, it may have benefits beyond being a GSH precursor. It is thought that progressive changes in these pathways are responsible for the neuroprogressive course in schizophrenia, and are in interaction with oxidative factors. A 62 years old male patient with a history of Bipolar Disorder, was started on 900 mg/day lithium and 20 mg/day olanzapine in another clinic. Lithium therapy was discontinued because of lithium intoxication, and olanzapine was found to be ineffective. The patient was then switched to 2000 mg/day valproic acid and 500 mg/day clozapine. Clozapine use soon resulted in leukopenia, and treatment was adjusted to 2000mg/day valproic acid, 200 mg/day clozapine, 10 mg/day olanzapine. The patient was admitted to our unit after exhibiting excessive speech, spending, disorganized and excitable behavior for a month. The patient was regarded to be in a manic episode of bipolar disorder, baseline WBC was measured 4.60 µl. Olanzapine treatment was gradually discontinued, and clozapine was gradually increased. The treatment was augmented with NAC 2400 mg/day since, from clinical experience, it was expected to have a beneficial effect on leukopenia. Even though clozapine dose was increased to 400 mg, routine CBC testing showed significant increase in leukocyte counts following NAC augmentation. The patient is currently on 1500 mg/day valproic acid, 500 mg/day clozapine and 2400 mg/day NAC; WBC value is 6.10 µl

### KEYWORDS

Clozapine; N-Acetylcysteine; leukopenia

Abstract:0231

## Possible Genetic Liability of Concurrent Kallmann Syndrome with Psychotic Disorder: A Case Report

Simge Seren Kirlioglu, Yasin Hasan Balcioglu and Pinar Cetinay Aydin

Department of Psychiatry, Bakirkoy Prof. Dr. Mazhar Osman Training and Research Hospital for Psychiatry, Neurology and Neurosurgery, Istanbul, Turkey

E-mail address: [yasinhasanbalcioglu@bakirkoyruhsinir.gov.tr](mailto:yasinhasanbalcioglu@bakirkoyruhsinir.gov.tr)

### ABSTRACT

Kallmann Syndrome (KS) is a rare disorder caused by the deficient production or secretion of gonadotropin-releasing hormone (GnRH), manifests with absent spontaneous puberty and absent or impaired sense of smell. KS has multiple inheritance patterns and mutations had been determined in five known disease genes (*KAL1*, *FGFR1*, *FGF8*, *PROKR2*, *PROK2*). It has been considered that KS and psychotic disorders originate in same predisposing genes due to their similar clinical features. We report a case diagnosed KS with psychotic disorder on

### KEYWORDS

Fibroblast growth factor; Kallmann Syndrome; schizophrenia



the purpose of discuss probable common etiopathogenesis. A 19 year-old male, was diagnosed KS after a detailed examination in order to admission to pediatrics due to delayed and absence of initial signs of puberty at his 13. He was on the treatment with hormone replacement. The patient presented to our outpatient clinic with hallucinations and delusions lasted for two years and suicidal thoughts also existed and he was hospitalized with a view of diagnosing and treatment. He was diagnosed psychotic disorder and olanzapine 5 mg/day was initiated then potentiated to 15 mg/day. Psychotic symptoms improved with the treatment, then he was discharged. Schizophrenia had been thought as a variant model of KS due to the similarities in between like trait defects, occurrence ratio, and sex distribution, and KAL-X gene mutation had been presumed in the pathophysiology of schizophrenia at first. It was thought that defect on this gene leads to impairment in GnRH releasing neurons migration and it was concluded as olfactory deficits in various severity and normal sexual development disruption. The defect in genes encoding the *fibroblast growth factor receptor (FGFR)* and *fibroblast growth factor (FGF)* which are responsible neurogenesis, gliogenesis, myelinogenesis and axonal overgrowth, are under-research in both KS and schizophrenia. This report aimed to contribute in the matter of similar molecular etiopathogenesis in both disease

Abstract:0243

## Suspicious Effect on Treatment and Prognosis of Schizophrenia: Ankylosing Spondylitis

Mustafa Uğurlu<sup>a</sup>, Görkem Karakaş Uğurlu<sup>b</sup>, Emine Tuğçe Akçaer<sup>b</sup>, Serdar Süleyman Can<sup>b</sup>, Ali Çayköylü<sup>b</sup> and Zuhale Koc<sup>a</sup>

<sup>a</sup>Department of Psychiatry, Atatürk Training and Research Hospital, Ankara, Turkey; <sup>b</sup>Department of Psychiatry, Yıldırım Beyazıt University School of Medicine, Ankara, Turkey

E-mail address: [zuhalkoc\\_19@hotmail.com](mailto:zuhalkoc_19@hotmail.com)

### ABSTRACT

Ankylosing spondylitis (AS) is a common inflammatory disease. Several studies showed that rheumatic disorders had a higher risk of psychiatric comorbidity especially depressive disorder. But co-occurrence of psychotic disorder and ankylosing spondylitis is considered to be low in relation. Here we describe a case of schizophrenia and ankylosing spondylitis comorbidity. 24 year-old, male patient suffering from contamination and asymmetry obsessions presented to our outpatient clinic 6 years ago. His psychiatric symptoms dated after 7 months when diagnosed with ankylosing spondylitis. He complained of elaborate washing and checking rituals that interfered greatly with his daily life. His particular concern was with food contamination. Because of this appetite of patient was diminished and had social isolation. The symptoms were diagnosed with obsessive-compulsive disorder and put on treatment with sertraline. Due to treatment noncompliance, his treatment changed with fluoxetine. At the same time, patient's medical adherence of ankylosing spondylitis was poor. Patient's rituals began to consume several hours a day leading disturbance in functionality. According to reports, besides to obsessions patient had persecutory and referential delusions and psychomotor agitation, disturbance in judgement. After that patient had several hospitalizations was diagnosed with schizophrenia. Patient put on treatment with several antipsychotics especially injection form. At last visit; treatment changed to once-monthly paliperidone palmitate 100 mg injection, risperidone 5 mg/day and depakine 2000 mg/day. Patient psychotic presentation cleared after treatment but obsessional thoughts remained. Underlying mechanism of ankylosing spondylitis with psychotic disorder relation should be studied for providing comprehensive care to patients. Ankylosing spondylitis activity and general well-being of patient acts together with psychological status so psychiatric evaluation should keep in mind during the evaluation and management of patients with AS by clinicians.

### KEYWORDS

Schizophrenia; ankylosing spondylitis; prognosis; rheumatic diseases

Abstract:0253

## Psychotic Manifestations Associated with Mega Cisterna Magna

Ali Çayköylü<sup>a</sup>, Mustafa Uğurlu<sup>b</sup>, Esra Kabadayı Şahin<sup>a</sup>, Görkem Karakaş Uğurlu<sup>a</sup>, Serdar Süleyman Can<sup>a</sup> and Zuhale Koç Apaydın<sup>b</sup>

<sup>a</sup>Department of Psychiatry, Yıldırım Beyazıt University, Ankara, Turkey; <sup>b</sup>Department of Psychiatry, Ankara Atatürk Research and Training Hospital, Ankara, Turkey

E-mail address: [zuhalkoc\\_19@hotmail.com](mailto:zuhalkoc_19@hotmail.com)

**ABSTRACT**

It has become apparent that cerebellum is critical for many functions other than coordination of movement. It is related in regulation of cognition and emotion. Mega cisterna magna is described as developmental variation of posterior fossa. Although some case reports suggest that there is relationship between mega cisterna magna and some psychiatric disorders, its pathogenesis has not been fully understood. We present here a case series that consists of two cases of schizophrenia and a case of dementia and late onset psychosis associated with mega cisterna magna.

Case 1: A 25 year-old, male patient with diagnosis of schizophrenia presented to clinic with complaints of having the fear of being killed, psychomotor agitation, aggression and poor treatment response. Brain MRI showed mega cisterna magna variation and frontal cortical atrophy. He had paroxysmal activity in EEG examination.

Case 2: A 29 year-old, male patient with diagnosis of schizophrenia for 4 years. He was brought to clinic because of noncompliance to treatment. He had complaints of suspiciousness, fear of being chased and harmed by other people, restlessness and insomnia. Brain MRI showed mega cisterna magna variation.

Case 3: A 76 year-old, male patient had been hospitalized with diagnosis of dementia and psychotic disorder 8 years ago. He presented to clinic with complaints of restlessness, insomnia, suspiciousness and memory impairment. In brain MRI, diffuse cortical atrophy and mega cisterna magna variation was reported. Mini mental state examination was performed and he had score of 17 of 30. He was discharged with diagnosis of dementia and late-onset schizophrenia. Functional and structural cerebellar abnormalities are considered that are associated with pathophysiology of schizophrenia. Beside structural changes, clinical studies showed there is altered corticocerebellar connectivity in these patients. It is suggested cerebellum has connection with several cortical regions via cortico-cerebellar-thalamic-cortical circuit (CCTCC) and disruption in activity of this circuit leads to symptoms observed in schizophrenia. So, any abnormality in cognitive process results with 'cognitive dysmetria', characterized by variety of disorganization symptoms in schizophrenia.

**KEYWORDS**

Mega cisterna magna; cerebellum; schizophrenia

Abstract:0338

## Evaluation and Management of Severe of Tardive Dyskinesia

Semra Ulusoy Kaymak<sup>a</sup>, Oğuz Peker<sup>b</sup>, Serdar Süleyman Can<sup>b</sup>, Zuhal Koç<sup>a</sup> and Ali Çayköylü<sup>b</sup>

<sup>a</sup>Department of Psychiatry, Atatürk Training and Research Hospital, Ankara, Turkey; <sup>b</sup>Department of Psychiatry, Yildirim Beyazıt University School of Medicine, Ankara, Turkey

E-mail address: [zuhalkoc\\_19@hotmail.com](mailto:zuhalkoc_19@hotmail.com)

**ABSTRACT**

Tardive dyskinesia (TD) is one of the most prominent obstacles of treatment with not only first generation antipsychotics but also second generation's. TD creates appearance problems, functional problems and distorts the quality of life. To get the best result, the most detailed evaluation should be made. A 38 year-old male patient with schizoaffective disorder had been using several different antipsychotic drugs (risperidone, amisulpride, olanzapine, quetiapine, and thioridazine) since 17 years. He was diagnosed as TD since ten years and given biperiden, tetrabenazine, valproate, and clonazepam and clozapine treatments. Ataxia, contractions in the limbs, and dyskinetic and dystonic movements in the neck increased and became more severe, to hinder the daily function of the patient. He had attempted suicide by jumping from a height, two times and underwent an operation due to vertebral fracture 8 months ago. In that period clozapine was stopped and was started again 2 months ago. He had undergone 2 cures of Botox treatment. The ongoing therapy of the patient includes clonazepam 6 mg/day, vitamin E 800 mg/day, omega 3 capsule 1000 mg/day, clozapine 250 mg/day, quetiapine 300 mg/day, valproate 1250 mg/day, and mirtazapine 15 mg/day. When the patient had been questioned about his awkward movements, such as putting his head in the drawer and sleeping in that position, compressing his head in the drawer, and consciously bumping his head on hard objects, he had told that he was relieving in that way. In inpatient service, the movements of the patient were increasing during the family visits. In addition to severe movement disorder, it was observed there are some motions toward the purpose. Management of anger and depression controlled the motions. Psychiatric symptoms may improve TD. Secondary gains and coincidental conversion disorders should be evaluated carefully.

**KEYWORDS**

Tardive dyskinesia; clozapine; conversion disorder; secondary gain

Abstract:0353

## Nocturnal Enuresis Associated with Clozapine Use: Is This an Epileptic Seizure or Not?

Bedriye Özkan, Ali Güven Kılıçoğlu and Gül Karaçetin

Department of Child and Adolescent Psychiatry, Bakırköy Prof. Dr. Mazhar Osman Mental Health and Neurological Diseases Hospital, Istanbul, Turkey

E-mail address: [bedriye.ozkn@gmail.com](mailto:bedriye.ozkn@gmail.com)

### ABSTRACT

Clozapine, a serotonin 5HT-2A- dopamine D2 antagonist, appears as a 'prototype' of atypical antipsychotics. Clozapine is an antipsychotic that is considered to be particularly effective when other antipsychotics fail and thus is the 'gold standard' for efficacy in the treatment of schizophrenia resistant to treatment. However, clozapine's varying intensity of side effects limits use. Enuresis nocturna is rarely seen but disturbing side effect of clozapine and its mechanism spectrum is widely versatile. One of them is to show up of epileptic seizures associated to clozapine as nocturnal enuresis during the sleep, with the decay of seizure threshold. In this presentation, an adolescent who developed nocturnal enuresis which was perceived as acting out was presented. In December 2015, a 15 year-old male consulted to the clinic with the complaints; anger, aggression, harming the others and himself and skepticism. It was learned that the patient has an early-onset schizophrenia about four years. Later then he has been hospitalized because of homicide risk. During hospital stay, the patient had no recovery of his positive symptoms with antipsychotic drugs cause of the multi drug resistance, treatment changed to clozapine, after some time interval, complaint of bedwetting is started. At this time the patient was having antiepileptic valproic acid. In simultaneous tests it is understood that Valproic Acid level was below the protective levels. By increase of Valproic Acid dose, proper blood level is obtained; after that, complaint of bedwetting is completely recovered. Recovery and the non-recurrence of the complaints with the proper dose of antiepileptic treatment is a highly probable evident that the acting out of the seizure is enuresis nocturna development. Compared to the other atypical antipsychotics, clozapine has higher rate of enuresis. In the orientation period of treatment, it is important to consider these side effects and manage it decently.

### KEYWORDS

Antipsychotics; clozapine; enuresis nocturna; epileptic seizure; side effect

Abstract:0363

## Self-Mutilation in Schizophrenia: A Case Report

Zeynep Yücehan, Tuğba Şerife Elmas, Dudu Demiröz, Nafiye Yağlı, Bilge Çetin İlhan and İbrahim Eren

Department of Psychiatry, Konya Training and Research Hospital, Konya, Turkey

E-mail address: [drzeynepgungor@hotmail.com](mailto:drzeynepgungor@hotmail.com)

### ABSTRACT

Self-mutilation is a person's intentional harming of the self without any intention of suicide. Self-injurious behavior is more common in schizophrenia patients, with higher morbidity and mortality in psychotic disorders. The prevalence of self-mutilation was reported as 4.3% for general psychiatric population and with a ratio of 15–20% among schizophrenia patients. In this case report we present a schizophrenia patient with recurrent behavior of self-mutilation in parallel with delusions. A 43 year-old man, applied to our clinic with complaints of wounding, aggression, nervousness, fear, and suspiciousness against his partner. A large number of wounds were present on his face, nape, back, extremities, and gluteal regions, most of which were infected. As part of his somatic delusions, the patient had thoughts of having a wire in his body, and his injuries were due to he was trying to find it. The patient had schizophrenia diagnosis for 25 years. The last treatment was clozapine 400 mg/day and escitalopram 10 mg/day. Even though his self-mutilating tendencies improved during treatment periods, the patient did not use his medication for the last 5 months, due insufficient social support. We started clozapine treatment and applied 7 sessions of ECT, after which self-mutilating behavior reduced. Self-mutilating behavior can be harmful especially under influence of delusions and hallucinations in schizophrenia patients, and should be avoided as it can cause serious injuries. It is known to decrease with necessary precautions and due to following a regular follow-up. In several studies clozapine was shown to reduce self-harm behavior. Clozapine treatment and ECT is important in preventing self-mutilation behavior.

### KEYWORDS

Self-mutilation; schizophrenia; clozapine

Abstract:0365

## Capgras Syndrome: A Case Report

Derya Adali Aker<sup>a</sup>, Yiğit Kılıncım<sup>a</sup>, Mustafa Solmaz<sup>b</sup> and Yeşim Ruhat Kutlu<sup>a</sup>

<sup>a</sup>Psychiatry Clinic, Eyüp State Hospital, Istanbul, Turkey; <sup>b</sup>Department of Psychiatry, Health Sciences University, Bağcılar Training and Research Hospital, Istanbul, Turkey

E-mail address: [drderyaadaliaker@gmail.com](mailto:drderyaadaliaker@gmail.com)

### ABSTRACT

Capgras Syndrome, which is described by French psychiatrists, Jean Marie Joseph Capgras and Reboul Lachous, is rarely common in past but nowadays is more common among psychiatry field. This syndrome is characterized by delusions of misidentification, where a patient believes and accepts that people closely related to him/ her are replaced by some similar or same appearance impostors or persecutors. These beliefs were ruminated persistently and changing them were difficult. Here, we present a patient who claims that his family is not his real family and he believes that the family members are imposters for five years. He was piped off by his reputed real family when he wanted to live with them. He was blacklisted by his reputed real family when he wanted to live with them. After that, he finally wanted to see a psychiatrist when the police advise him to seem by a doctor. Firstly we made a few examination for differential diagnosis especially organic etiology. After all, we gave oral olanzapine 10 mg per day for the treatment of drug-naïve patient. We observed him weekly for treatment.

### KEYWORDS

Capgras syndrome; imposters; delusions

Abstract:0376

## Visual and Auditory Hallucinations Associated with Mega Cisterna Magna: A Case Report

Bahar Yeşil<sup>a</sup> and Behice Han Almış<sup>b</sup>

<sup>a</sup>Elazığ Mental Health and Disorders Hospital, Elazığ, Turkey; <sup>b</sup>Adiyaman Research and Training Hospital, Adiyaman, Turkey

E-mail address: [baharyesilege@hotmail.com](mailto:baharyesilege@hotmail.com)

### ABSTRACT

Mega cisterna magna is a developmental variation of the posterior fossa characterized by the enlargement of the cisterna magna that is associated with various psychiatric conditions before. We want to describe visual and auditory hallucinations in a patient with mega cisterna magna. A 23 year-old man presented with the complaint of visual and auditory hallucinations which was insidious onset and continued for 1 year. Hallucinations were about his daily life, he has no delusions. He had no history of psychiatric and neurological disorders and no family history. His developmental history was normal, self-care was good, but his cognitive functions were impaired and he left his work. There was no alcohol or substance use. Physical and biochemical examination was normal. In the cranial MRI; mega cisterna magna and asymmetric lateral ventricles were detected. Cerebellum and vermis were intact. EEG was unremarkable. Olanzapine treatment has begun 10 mg/day for 2 months. The symptoms decreased by 80% controlled by PANNS score. The patient could begin to work again, mental and academic performance improved after the period following treatment. Mega cisterna magna has been described in association with schizophrenia and obsessive-compulsive disorder, manic episode, psychosis (delusional type), impulsive behaviors and recurrent major depression previously. For schizophrenia a model was suggested to explain "misconnections" between cortical regions and the cerebellum mediated through the thalamus (the cortico-cerebellar-thalamic-cortical circuit). Psychotic symptoms such as hallucinations may occur in this circuit. We observed a good response on slow-onset positive symptoms at the treatment dose of an atypical antipsychotic. The isolated mega-cisterna magna in this case can lead to less effect on the circuit, this may be the result of the good response. Mega cisterna magna may be associated that various psychiatric manifestations including psychosis. Olanzapine could be useful drug with its low side effects

### KEYWORDS

Mega cisterna magna; visual auditory hallucinations; olanzapine

## A Patient with Schizophrenia with Intense Magical Belief and Kinesthetic Hallucinations

Başak Küçük and Cem Cerit

Department of Psychiatry, Kocaeli University, Kocaeli, Turkey

E-mail address: [basak\\_0012@hotmail.com](mailto:basak_0012@hotmail.com)

### ABSTRACT

Auditory hallucinations are common in schizophrenia patients, kinesthetic hallucinations can be seen also. In addition, these patients' familial beliefs and cultural features can affect the progression of schizophrenia. In this case report we present a schizophrenia patient with kinesthetic hallucinations whose parents have intense spiritual beliefs. Patient referred to us with loss of appetite complaints and hospitalized. Patient believed that his father commands his thoughts. His complaints first began 8 years ago with social isolation and he was thinking that there has been something inside in his head. Then his parents brought him to a spiritual healer. For the last two years patient was researching about bioenergy and metaphysics subjects. His family said and believed that he was going better with these sessions. In psychiatric examination; the patient had an proper physical development for his age and proper clothing for his socioeconomic status. He had kinesthetic hallucinations. The dominant part of his thought content was that his father was reading his mind through bioenergy. Judgment and reality testing was deteriorated. We started 10 mg/day olanzapine and depot zuclopenthixol 200 mg/week. In the forthcoming days, patient described that he feels something moving under his left arms skin, also he experienced something like electric discharging. He told that his brain was getting numb, or moving and contracted. He verbalized that his father was a member of religious organization. He believed that the worshipper people spread out the bad energy. His initial PANSS scale point was 82 and 71 at the discharge. Toxic drug test was negative. EEG monitoring was normal. After a month of treatment patient's symptoms relieved and his schizophrenia diagnosis was confirmed. Even though there is neuroanatomical background of the psychotic phenomenon, culture and environment have an important role on these phenomenon. Some symptoms of psychosis can be acceptable or even approvable in eastern societies.

### KEYWORDS

Magical beliefs; kinesthetic hallucinations

Abstract:0435

## Electroconvulsive Therapy in a Pregnant Woman with Psychotic Exacerbation

Burcu Sarici, Ayşe Ceren Kaypak, Erensu Baysak, Serhat Ergün and Mesut Yildiz

Department of Psychiatry, Marmara University School of Medicine, Istanbul, Turkey

E-mail address: [burcumatt@hotmail.com](mailto:burcumatt@hotmail.com)

### ABSTRACT

Psychiatric disorders are common during pregnancy, affecting 15–29% of all pregnant women and pregnancy makes the treatment of psychiatric disorders very difficult. Because of the possible harmful effects of pharmacotherapy on the fetus during pregnancy, Electroconvulsive therapy (ECT) is used as another option in treatment and effective in several mental disorders. ECT has some reversible side effects and complications, but most of the complications are mild and limited. We aim to present a pregnant women with psychotic exacerbation who was resistant to antipsychotics and controlled symptoms with ECT. We also want to discuss relapsing symptoms shortly after ECT. A 25 year-old female patient was followed for 10 years with schizophrenia and she was taking Olanzapine 30 mg/day. Treatment of the patient was changed to Haloperidol 10 mg/day because of pregnancy planning. The patient was brought to the hospital by her family due to aggression and inappropriate behavior. It was learned that persecutory delusions and auditory hallucinations increased after the treatment change. The patient was hospitalized. Haloperidol 10 mg/day treatment was continued and ECT was planned. At the end of the 4th session, her complaints were decreased and at the end of the 7th session, all psychotic symptoms almost gone. There were no maternal and fetal complications after each ECT treatment. After treatment, she was discharged with haloperidol 10 mg/day while she was 36 weeks pregnant. She had labor at 38th week. It was learned that the patient had stopped taking pills for 2 days because of labor and her symptoms start again after the birth. Although ECT is a safe and efficient treatment choice during pregnancy, relapse and recurrence rate is still high in first year even if the antipsychotic treatment continues. Continuation and maintenance electroconvulsive therapy may be recommended in these cases.

### KEYWORDS

Electroconvulsive therapy; schizophrenia; pregnancy



Abstract:0448

## A Case Report of First Attack Psychosis and Wilson Disease

Aslihan Okan Ibiloglu<sup>a</sup>, Abdullah Atli<sup>a</sup>, Mehmet Asoglu<sup>b</sup> and Mustafa Ozkan<sup>a</sup>

<sup>a</sup>Department of Psychiatry, Dicle University School of Medicine, Diyarbakir, Turkey; <sup>b</sup>Department of Psychiatry, Harran University School of Medicine, Sanliurfa, Turkey

E-mail address: [aslihanokan@gmail.com](mailto:aslihanokan@gmail.com)

### ABSTRACT

Wilson's disease is an infrequent, autosomal recessive disorder of copper metabolism, primarily affecting the liver and brain. Kayser–Fleischer ring is present in 99% of neuropsychiatric patients. Compared to other psychiatric manifestations, psychosis is less commonly described in patients with Wilson's disease. In this report we present the case of a 42 years woman with Wilson's disease who developed first acute onset psychotic symptoms. A 42 year-old woman, housewife, divorced was referred to our psychiatry department by the gastroenterologist. She was diagnosed with Wilson's disease approximately 12 years ago. She developed an acute onset psychosis, characterized by persecution and reference delusions, fearfulness, and decreased sleep. There was no past or family history of psychosis. Daughters noticed changes in the patient's behavior. Due to the psychotic symptoms, she occurred irritability, reference and persecution delusions associated with significantly dysfunction of daily activities. Over the next days, the psychotic symptoms became more extensive and systematized; following which she was found to keep all her belonging under lock. Also, all these symptoms were not associated with any altered cognition, hallucinations in any modality, thought disorder, depressive symptoms, head injury or substance abuse. A diagnosis of psychotic disorder due to Wilson's disease was considered. She was treated for psychosis with quetiapine 800 mg/day and lorazepam 2.5 mg/day. Wilson's disease generally appears between the age of 10 and 20. It rarely remains masked until after the age of 40. The first manifestations are hepatic (40% of the cases), neurological (35%) or psychiatric (10%). The severe psychiatric disorders observed during Wilson's disease may require tranquilizers, but care should be taken because of potential neurological or hepatic side effects. It should be noted that the medical history of cases of late onset psychosis or recurrent depressive disorder.

### KEYWORDS

Atypical antipsychotic; first episode; psychosis; Wilson's disease

Abstract:0129

## Effectiveness of Low Dose Aripiprazole in the Treatment of Autistic Child with Separation Anxiety Disorder

Necati Uzun and Ömer Faruk Akça

Department of Child and Adolescent Psychiatry, Necmettin Erbakan University, Meram School of Medicine, Konya, Turkey

E-mail address: [necatiuzun42@gmail.com](mailto:necatiuzun42@gmail.com)

### ABSTRACT

Autism Spectrum Disorder (ASD) is a common disorder which effects children's development of language and social skills. Psychiatric comorbidities are common in children with ASD. Anxiety disorders also show high comorbidity in children with ASD. Some guidelines recommend selective serotonin reuptake inhibitors (SSRIs) as first line treatment for anxiety disorders. Use of atypical antipsychotics to augment antianxiety medication has been shown to be beneficial in the treatment of anxiety. As far as we know this is the first reported case of an autistic child with separation anxiety disorder treated with low dose aripiprazole. The case presented here was a 7 year-old boy consulted our clinic with complaints of cannot staying alone, having an excessive fear in sleeping alone without his mother, and slight hyperactivity. He cannot speak except for few words such as mother, father, and mother. According to his mother he had an excessive fear when she had gone away although some close relatives with the side of him. In these situations he had crying and hurting himself. The patient was diagnosed as having ASD and separation anxiety disorder. Clinical Global Impression (CGI) score of anxiety symptoms was 7 at the beginning of treatment. Aripiprazole 2.5 mg/day was initiated and two weeks later anxiety symptoms slight improved and CGI score was 5 at this visit. Aripiprazole doze increased to 5 mg/day and one month later the patient's anxiety symptoms had decreased, and his CGI score was 1 and his hyperactivity was also improved and anxiety symptoms never recurred over 2 months of follow-up. Treatment of anxiety with SSRIs is well-known. Some studies showed the beneficial results of augmentation of therapeutic effect of SSRIs by adding an aripiprazole in

### KEYWORDS

Aripiprazole; autism; separation anxiety disorder

the treatment of obsessive compulsive disease (OCD) and depression. Low dose aripiprazole brought about improvement in anxiety symptoms in our case.

Abstract:0259

## Adult Separation Anxiety Disorder Responded to Fluoxetine Treatment: A Case Report

Gizem Aral and Demet Sağlam Aykut

Department of Psychiatry, Karadeniz Technical University, Trabzon, Turkey

E-mail address: [gizem.aral@gmail.com](mailto:gizem.aral@gmail.com)

### ABSTRACT

The adult form of separation anxiety disorder (ASAD) has only recently been described in the psychiatric literature. The National Comorbidity Study Replication was the first large-scale epidemiological study to include the diagnosis, revealing a lifetime prevalence of 6.6%. In this case report, an adult anxiety disorder that responds to treatment with fluoxetine. A 32 year-old man with a 5 month of major depression was referred to our clinic because his symptoms intensified when his mother was died. His chief preoccupations were with fears of being separated from people close to him and he was plagued by worries about harm befalling them. He worried about his daughter will be sick and his wife getting divorced, his sister get an accident so he became alone. When he was at job, felt driven to speak to his two adult children every other day on the phone. Also he continued to be anxious about his family members leaving the house and would imagine all sorts of disasters befalling them when they were out. When preparing for sleep, he habitually made sure that his daughter breathing well so he frequently checks his daughter sleeping. He also described recurrent nightmares about someone kidnapping his daughter. He was diagnosed Adult Separation Anxiety Disorder, the treatment began with fluoxetine 20 mg/day increased to 60 mg/day at sixty week. His ASA score was 20 and his worries appeared to decline, began to sleep well, his nightmares was disappeared. Look for other literature most cases early symptoms appear for the first time in childhood, persisting into the later years, although onset can be in adulthood. Fluoxetine is useful and well tolerated for the acute treatment of anxious youths. with, separation anxiety disorder. Aim of this case report to assess fluoxetine treatment response to symptoms onset in adulthood ASAD.

### KEYWORDS

Adult separation anxiety disorder; adulthood; fluoxetine

Abstract:0318

## Does Escitalopram Cause Amenorrhea? The Role of Increased Level of ACTH

Özgür Maden, Mustafa İspir, İbrahim Gündoğmuş, Ayhan Algül and Servet Ebrinç

Department of Psychiatry, Haydarpaşa Sultan Abdulhamid Training and Research Hospital, Istanbul, Turkey

E-mail address: [drozgurmaden@hotmail.com](mailto:drozgurmaden@hotmail.com)

### ABSTRACT

Escitalopram is a selective serotonin reuptake inhibitor that is used to psychiatric disorders. Amenorrhea is defined as the cutting of the menstruation of woman who had previously regularly menstruation. Here, we report the case of a woman who was treated escitalopram for anxiety disorder for a longtime and developed amenorrhea without hyperprolactinemia. A 43-year-old woman presented with reluctance, fatigue, headache, decrease in sleep, difficulty in falling asleep. Her history had no alcohol and drug use, or organic disease. Three years ago, her complaints were started. She was treated with escitalopram 10 mg/d with a diagnosis of anxiety disorder according to DSM-5, and regularly used to escitalopram during this time. Her menstrual irregularities and lack of menstruations complaints had emergence about six months before. No amenorrhea was seen before, and her menstruation period was regularly. She did not use oral contraceptives and was not pregnant. Beck Depression Inventory (BDI) scores was 36, Beck Anxiety Inventory (BAI) score was 30. The physical examination result and laboratory values for hemogram, liver and kidney function tests, prolactin, thyroid hormones, and electrolyte were normal. Her ACTH level's was 51.9 (reference range <46). The patient was referred by gynecology. The result of cranial MRI was normal. The pathologic finding that would explain amenorrhea was not detected by obstetrician. Escitalopram

### KEYWORDS

Escitalopram; amenorrhea; ACTH; anxiety; menstruation



treatment was stopped, and treatment with trazodone 50 mg/d was started; 15 days later, menstruation was detected. One month later, ACTH level was 37.2, BDI score was 12, and BAI score was 16. During three months of follow-up, the patient has taken trazodone, her menstruations were regular. Amenorrhea can be induced by a variety of drugs that affect ACTH levels, especially antidepressants, antipsychotics, cortisol derivatives, and chemotherapeutics. Clinicians should think of escitalopram as a probable cause of amenorrhea due to increased ACTH.

Abstract:0437

## It's Too Cold: A Case Report

Fulya Gok, Seda Kiraz, Arif Cipil and Meliha Zengin Eroglu

Department of Mental Health and Disease, Health Sciences University Haydarpaşa Numune Training and Research Hospital, Istanbul, Turkey

E-mail address: [fufubo@hotmail.com](mailto:fufubo@hotmail.com)

### ABSTRACT

Specific phobia is a feeling of fear or anxiety about certain objects or situations. Frigophobia is a type of phobia reported as a rare psychiatric syndrome, defined as being frightened by cold or cold things. In this case report, we aimed to share and discuss a case of frigophobia which can be defined as specific phobia according to DSM-5. A 53-year-old male patient with no previous psychiatric diagnosis presented to outpatient clinic with cold water-induced chill and tremor attacks. His attacks have been occurring only every 2-3 months in winter and continued for 4-5 hours. When the complaints of the patient started, he entered the bed, covered two quilts, tried to warm up with hot water bag and hair dryer. His physical and laboratory examinations, electrocardiography and electroencephalography were within normal range. His psychiatric examination revealed that he was wide-awake and that his orientation and cooperation were good. Psychomotor activity was normal. His mood was euthymic and affect was normal. Speaking speed and quantity were normal. Their associations were smooth, delusions and hallucinations were not detected. Low dose antidepressant was started to the patient. The patient's follow-up still continues. Frigophobia is considered under the heading of an anxiety disorder related to culture. The common clinical presentation is patients who are suffering from cold extremities, and then, with the onset of fear, covering themselves in layers of clothing, applying emollients, and staying near an fire in an effort to ward off the cold. They avoided foods considered to be "cool" and bathed only in the heat of the afternoon sun. Frigophobia is a rare type of phobia, defined as fear of cold or cold things. Management consists primarily of disease training, assurance and desensitization by exposure to cold stimulants, and short-term use of anxiolytic drugs when necessary.

### KEYWORDS

Anxiety disorders; specific phobias; frigophobia; treatment of phobias

Abstract:0234

## Long-Acting Methylphenidate Treatment in an Adolescent Girl with ADHD and Primary Enuresis: A Case Report

Melike Kevser Gül, Neslihan Taştape, Esra Demirci and Sevgi Özmen

Department of Child and Adolescent Psychiatry, Erciyes University, Kayseri, Turkey

E-mail address: [melikegul46@hotmail.com](mailto:melikegul46@hotmail.com)

### ABSTRACT

Attention-deficit/hyperactivity disorder (ADHD) is a common neurodevelopmental disorder characterized, by a persistent and impairing pattern of inattention and/or hyperactivity/impulsivity. Enuresis is a pathological state associated with the lack of a developed skill in controlling the urinary bladder, resulting in repeated episodes of involuntary micturition during sleep or waking. Enuresis is a common comorbid disorder in children with ADHD. The rate of enuresis in children with ADHD has been reported as about 30%. In this report, we present an adolescent girl with ADHD and primary enuresis that treated with long acting methylphenidate. A 13-year-old girl was referred to the outpatient clinic by her family with nocturnal bedwetting every night and daytime urinary incontinence. She had same symptoms during 8 years. She also had forgetfulness, difficulty listening and easily distracted. She was experiencing severe problems during making homework and listening classes. Both

### KEYWORDS

Attention-deficit/hyperactivity disorder; bedwetting; imipramine; long-acting methylphenidate; urination; primary enuresis

the clinical interview and the parent and teacher reports were suggestive of an ADHD diagnosis. Until now, there wasn't any improvement with conditioning therapy and imipramine 50 mg/day. We oriented the patient to nephrology and urology departments to detection organic etiology but the results had evaluated normally. Her condition was diagnosed ADHD and primary enuresis. For the treatment long acting methylphenidate drug 10 mg/day was chosen and two weeks later dose was increased to 20 mg/day. She had nocturnal bedwetting only once and no daytime wetting. The ADHD symptoms were decreased during this time. Our case supports the positive scientific findings about the association long acting methylphenidate and the treatment of ADHD with primary enuresis. There are many hypotheses for to explanation of the effects of this medication in the treatment of enuresis and ADHD. But the relationship between the treatment of both these disorders has not been understood clearly yet.

Abstract:0289

## Attention-Deficit/Hyperactivity Disorder Due to Corpus Callosum Agenesis: A Case Report

Hicran Doğru

Department of Child and Adolescent Psychiatry, Erzurum Regional Training and Research Hospital, Erzurum, Turkey

E-mail address: [hicran\\_ktekin@yahoo.com](mailto:hicran_ktekin@yahoo.com)

### ABSTRACT

Attention-deficit/hyperactivity disorder (ADHD), characterized by attention deficit, extreme mobility and impulsivity is a neuropsychiatric disorder in which findings usually start around 3-years of age. This disorder puts the child into a social, academic, emotional, and cognitive turmoil. Incidence of ADHD in school-age children varies between 5–7%. The etiology of ADHD is not explained clearly but various genetic, environmental factors are considered responsible for the disruption in the early development phase. A 4 year-old, presented to the outpatient clinic with complaints of sudden attacks of rage, hyperactivity, restlessness, talkativeness, digging around all the time. On exam distractibility, mobility, talkativeness, inability to sustain attention were evident. After taking the history, it has been learned that the development of the patient's gait and speech started late. In the nursery form, the teacher stated that the patient was always on the move, had difficulty paying attention, and fought too often with his friends. The Corpus Callosum, indicates one of the most common structural abnormalities in the brain. These children might present with growth retardation, microcephaly, epilepsy and mental retardation. The condition virtually might not cause any problem at all. Damage in this area may disrupt the cognitive skills, attention, language, learning, and fields such as impulse control mechanism. Sometimes patients may present with attention deficit, just as in this case. The effect of the structural change in the brain over the course of patient's clinic is not well understood in ADHD but a neurodevelopmental disruption is obvious. Thus, neuroradiological tools are of great importance especially in cases with developmental delay to rule out corpus callosum agenesis.

### KEYWORDS

Attention-deficit/hyperactivity disorder; child; corpus callosum agenesis

Abstract:0310

## Hallucination As a Side Effect in the Treatment of Attention-Deficit/Hyperactivity Disorder

Muhsine Göksu<sup>a</sup>, Leyla Ezgi Tügen<sup>a</sup>, Ayşe Burcu Ayaz<sup>a</sup> and Ayşe Arman<sup>a</sup>

Department of Child and Adolescent Psychiatry, Marmara University School of Medicine, Istanbul, Turkey

E-mail address: [muhsinegoksu@gmail.com](mailto:muhsinegoksu@gmail.com)

### ABSTRACT

Methylphenidate and atomoxetine are frequently used in the treatment of ADHD. With the use of methylphenidate and atomoxetine, side effects such as abdominal pain, decreased appetite are common, while hallucination is a relatively rare side effect. A 4-year-old girl was referred to our outpatient clinic with her family for the complaint of masturbation. The child, who has limited eye contact, lack of empathy, difficulty in initiation, was clinically evaluated as autism spectrum disorder. The child, who applied with the complaint of hyperactivity on the 1st

### KEYWORDS

Atomoxetine; methylphenidate; hallucination

grade of elementary school, was treated with 10 mg methylphenidate daily regarding additional attention-deficit/hyperactivity disorder diagnosis. A few days later, she stated that she was seeing a lot of black images around her that were ambiguous. These images were evaluated as visual hallucinations and hallucinations passed immediately after the drug discontinuation. Subsequently, 18 mg of atomoxetine daily was started for the treatment of ADHD and 25 mg daily dose was reached after 10 days. Shortly after the atomoxetine dose was increased, the child started to shout that she heard some voices and her family reported that she talking and shouting to herself. These symptoms were considered as auditory hallucination and atomoxetine was also cut off. It is known that there are hallucinations at toxic doses and parenteral methylphenidate administration. There are also limited number of case reports reporting hallucinations, with the use of atomoxetine in therapeutic doses. Clinicians should be aware of the rare side effects of methylphenidate and atomoxetine, such as hallucinations, and should be more cautious when using medication in patients with developmental disorders who reported side effects before. Family history of psychosis, familial drug side effects such as hallucinations, and specific neurological tendencies of children diagnosed with social communication disorders should be considered carefully.

Abstract:0078

## Amitriptyline Abuse in a Patient with History of Alcohol Dependence

Recep Başaran, Hatice Yardım Özayhan, Deniz Altunova, Dudu Demiröz, İbrahim Eren and Mustafa Çağrı Yıldız

Psychiatry Clinic, Konya Training and Research Hospital, Konya, Turkey

E-mail address: [recepbsrn@hotmail.com](mailto:recepbsrn@hotmail.com)

### ABSTRACT

Tricyclic antidepressant used to treat depression, anxiety, chronic neuropathic pain, fibromyalgia and insomnia. Amitriptyline is a tricyclic antidepressant which blocks norepinephrine and serotonin transporters and inhibits their neuronal uptake. Anticholinergic drugs have euphoric side effects. So they have higher risk for abuse these drugs. In this report we presented case of amitriptyline abuse in a patient with a history of alcohol dependence. A 47 year-old male patient, married, graduated from high school. The patient has gone to the emergency service with his wife because of using 50 tablet of amitriptyline which is 25 mg. He has complained difficulty in speech, agitation, auditory and visual hallucinations, and distractibility. He consulted with psychiatry. The patient started to drinking alcohol with one beer and he has drunk every day since 20 year. He has been treated at alcohol and substance addiction treatment center. When he did not drink alcohol some symptoms appeared which were discomfort, insomnia, shaking hands, so he started to use drugs and bought amitriptyline 25 mg tablet. Day by day he potentiate amitriptyline and he get drugged 25 tablets in one day. When he used amitriptyline he feels good if he did not used drugs irritation and distractibility symptoms are increased. Bupropion 150 mg/day and risperidone 2 mg/day ordered to patient. During 3 months; the patient came to hospital regularly for control examination and he did not abuse amitriptyline. Antidepressant drugs do not cause addiction but some kinds of antidepressant drugs abused in literature. In this case report; we try to explain the patient abuse amitriptyline because of euphoria effects that has alcohol depended history. When the patient who misused amitriptyline apply to emergency service, the doctor must be aware of about misusing amitriptyline because of euphoria effects. These drug overdoses cause serious side effects and using them with alcohol increased toxicity risk.

### KEYWORDS

Amitriptyline abuse; alcohol dependence; side effects

Abstract:0147

## Polysubstance Use Disorder in Isaacs' Syndrome as Probable Self-Medication: A Case Report

Yasin Hasan Balcioglu, Simge Seren Kirioglu and Pinar Cetinay Aydin

Department of Psychiatry, Bakirkoy Prof. Dr. Mazhar Osman Training and Research Hospital for Psychiatry, Neurology and Neurosurgery, Istanbul, Turkey

E-mail address: [yasinhasanbalcioglu@bakirkoyruhsinir.gov.tr](mailto:yasinhasanbalcioglu@bakirkoyruhsinir.gov.tr)

**ABSTRACT**

Isaacs' Syndrome (IS) is a peripheral motor nerve continuous hyper-excitability disorder manifesting with progressive muscle stiffness, involuntary continuous muscle twitching, muscle pain and cramping, sweating and decreased reflexes. Autoantibodies against voltage-gated potassium channels block the activity of the channels and lead to nerve hyper-excitability with repetitive peripheral nerve discharges. Besides carbamazepine, phenytoin and gabapentin; psychotropic drugs such as dronabinol, antidepressants and benzodiazepines are also offered in the current literature for symptomatic relief in IS. We report a treatment-noncompliant IS patient with both synthetic cannabinoid and opioid use disorders with discussing possible medication effects of these substances on IS symptomatology. A 31 year-old male patient hospitalized due to his polysubstance use with his homicidal thoughts and behaviors without any psychotic symptom. He was diagnosed with IS, after spontaneous, continuous, visible muscle twitching at his 16. The diagnosis was confirmed with the electrophysiological studies and the presence of serum voltage-gated potassium channel autoantibodies. He was not adherent to the prescribed carbamazepine treatment and started to use psychoactive substances with opioids 10 years ago and continued using cannabinoids including synthetic form-. He stated diminished complaints of muscle pain and spasticity with the use of cannabinoids and opioids. Carbamazepine 200 mg/daily was initiated and potentiated to 400 mg in order to treat both IS and impulsive substance use. Besides sodium channel blocking agents, recently, clinical improvement with the cannabinoid dronabinol was shown in IS, probably by its activator role on potassium channels and immunomodulatory effects through CB1 and CB2 receptors. It is also assumed that combination of cannabinoids and opioid analgesics exerts synergistic nociceptive effects. Substance use may provide antispastic and analgesic impacts in IS. Further studies would aid to reveal therapeutic mechanisms of psychoactive molecules in the management of IS, coherent with the current report.

**KEYWORDS**

Isaacs' syndrome; myalgia; spasticity; substance use disorder

Abstract:0148

## Synthetic Cannabinoid Intoxication: A Case Report

Serdar Süleyman Can, Çağlar Soykan, Murat İlhan Atagün, Ali Çayköylü, Gökem Karakaş Uğurlu and Ayşegül Taşdelen Kul

Department of Psychiatry, Yıldırım Beyazıt University, Ankara, Turkey

E-mail address: [aysegul.tsdl04@hotmail.com](mailto:aysegul.tsdl04@hotmail.com)

**ABSTRACT**

Synthetic cannabinoid receptor agonists are becoming increasingly popular as an abused agent. There is very little literature detailing the presentations of individuals who use synthetic cannabinoids. We present a case with loss of consciousness due to synthetic cannabinoid intoxication. A 25 year-old patient was brought to the emergency service after reportedly having state of stupor, tachycardia and fever for a week. His mother stated that he had been using this substance for six months and he had a history of cocaine, heroin and alcohol abuse for ten years. The physical examination showed that he would hold his arm in the abducted position placed by the examiner, then would slowly lower it. He had muscle rigidity in upper extremities. Neurological examination revealed hyperreflexia and dilated pupils. The electrocardiogram, hemogram, brain CT, and routine laboratory tests were within normal limits. EEG patterns were associated with encephalopathy. The urine toxicology screen for drugs of abuse, including THC metabolites, cocaine and heroin were positive. Patient received supportive treatment and he gained consciousness four days after admission to emergency service. He stated that he intentionally used synthetic cannabinoid, heroin and cocaine simultaneously in order to commit suicide. The clinical presentation of synthetic cannabinoid abuse consists of altered mental status, sinus tachycardia, seizures, central nervous system depression, anxiety, hallucinations. Most of these symptoms get better approximately after two to four hours. In our case patient recovered four days after the admission of multiple substance use. In conclusion, if patients have history of substance abuse, physicians should consider synthetic cannabinoid intoxication.

**KEYWORDS**

Intoxication; suicide; synthetic cannabinoid

Abstract:0273

## An Adolescent with Oxybutynin Abuse Developing on the Basis of Unrecognized ADHD: A Case Report

Ekrem GÜLDAŞ, Güler Göl, Uğur Savcı and Ali Evren Tufan

Department of Child and Adolescent Psychiatry, Abant İzzet Baysal University, Bolu, Turkey

E-mail address: [dr.guldass@gmail.com](mailto:dr.guldass@gmail.com)

### ABSTRACT

Anticholinergic agents have been reported to be abused since 1980s. Abuse of those agents among adolescents has received relatively little attention compared to adults. Oxybutynin has relatively weaker anti-cholinergic effects which led to the view that it has lower potential for abuse. The patient was a seventeen year-old adolescent male who was brought to our department with complaints of "weight loss, change in behaviors and mydriasis". Upon questioning it was learned that he had been using at least 50 mg/day of oxybutynin without tolerance or withdrawal symptoms. The abuse had a waxing and waning pattern and coincided with interpersonal stressors. After he had started abusing oxybutynin his sleep and appetite were reduced and he lost 17 kg of weight within the last 10 months. The developmental history was notable for symptoms of hyperactivity, impulsivity and inattention prior to the onset of abuse. Mental status examination revealed reduced grooming, depressed mood with anxious affect. Sleep and appetite were reduced. Psychometric examinations with Beck Depression Inventory and Screen for Childhood Anxiety and Related Disorders revealed scores of 19 (moderate depressive symptoms) and 36 (anxiety symptoms above threshold); respectively. In accordance with the DSM-5 criteria he was diagnosed with other (or unknown) substance use disorder (oxybutynin), ADHD (Inattentive presentation). The depressive and anxious symptoms were judged to be secondary to oxybutynin abuse. He was started on atomoxetine 25 mg/day and quetiapine 25 mg/day and atomoxetine was gradually titrated to 60 mg/day. Oxybutynin abuse remitted within 4 weeks and both the patient and his parents reported improvement in academic and interpersonal domains as well as depressive and anxious symptoms. Clinicians should be aware of the abuse potential of oxybutynin especially by adolescents with unrecognized/untreated ADHD and disruptive behavior disorders. Atomoxetine may be a viable choice for treatment of ADHD in those patients.

### KEYWORDS

ADHD; abuse; oxybutynin

Abstract:0299

## Pregabalin Abuse and Withdrawal: A Case Report

Seda Yıldırım Özbek, Süleyman Özbek, Hilal Uygur, Başak Demirel, İ. Esra Çiçek and İbrahim Eren

Department of Psychiatry, Konya Training and Research Hospital, Konya, Turkey

E-mail address: [seda-yldrm@hotmail.com](mailto:seda-yldrm@hotmail.com)

### ABSTRACT

Pregabalin is a new generation antiepileptic drug that exerts its effects by decreasing the release of neurotransmitters, such as glutamate, noradrenaline, and substance P. There have been studies conducted in recent years demonstrating the effectiveness of pregabalin could be beneficial in the treatment of drug and alcohol withdrawal. However, there have also been cases in which pregabalin dependence developed. The present case describes a male patient developed withdrawal symptoms following pregabalin abuse. The patient is a 26 year-old, married man who started on pregabalin in order to discontinue buprenorphine use than abused it and exhibited withdrawal symptoms when not using it. The patient reported a history of cannabis abuse and heroin dependence but had been abstinent from heroin since he was released from prison 1 year ago. He had been using this drug irregularly on his own. Then his pregabalin use became regular and he finally increased the dosage to 20 capsules of 300 mg/day. After admission to our inpatient clinic, while the intake of pregabalin was decreased, withdrawal symptoms such as insomnia, psychomotor agitation, tremor, irritability, heartburn, nervousness, anxiety and depressive symptoms were observed. The patient's urine drug test was positive for cannabis. The patient was diagnosed with substance abuse disorder, sedative, hypnotic or anxiolytic use disorder. As supportive medication diazepam was initiated. Paroxetine and risperidone was administered. We conclude that pregabalin displays a potential for abuse. The reward effect of pregabalin has been implicated in its potential for abuse. Although pregabalin is a promising drug for various psychiatric disorders, it should be used carefully in patients with a history of substance abuse.

### KEYWORDS

Abuse; pregabalin; withdrawal

Abstract:0303

## Codeine Content Drug Abuse and Alcohol Use Disorder: A Case Report

Hüseyin Kara, Mehmet Murat Balcı, Servet Karaca and Mehmet Murat Kuloğlu

Department of Psychiatry, Akdeniz University, Antalya, Turkey

E-mail address: [kayfen\\_huseyin@hotmail.com](mailto:kayfen_huseyin@hotmail.com)

### ABSTRACT

Epidemiological data suggest that the abusing of non-prescription opioids has increased. It is often forgotten that non-prescription drugs can also be abused. In this case report we discussed a patient who was treated in Akdeniz University Alcohol and Substance Abuse Research and Treatment Centre in patient clinic. The patient was diagnosed with alcohol use disorder comorbid with unidentified opiate use disorder. A 41 year-old male who applied our outpatient clinic complained about abusing alcohol and a drug which contains codeine phosphate (10 mg). He reported that has been using alcohol regularly for the last 20 years and consuming at least 12 bottles of beer per day. He stated that he became addicted to this drug because of its codeine content and he has been purchasing this drug in the black market without any prescription. He also stated that he first encountered this drug twenty years ago. At first he stated that he was using five pills per day and the amount had increased during this last twenty years. He went up to a hundred pills per day recently. When he could not use the drug he had insomnia, palpitation, restlessness, perspiration and aggressiveness and exhibiting aggressive behavior against his family members. There was no abnormal finding in his mental status examination. The results of blood routine biochemistry tests were ALT: 53 AST: 59 GGT: 410. The opiate metabolite was found positive in the urine toxicology. According to DSM-5, alcohol use disorder and opiate use disorder were diagnosed. Naltrexone treatment has begun. No withdrawal symptoms were observed during his hospitalization. He was discharged after one month and out-patient follow-up. When the drugs which contains codeine are prescribed, the risk of misuse of the patients should be considered.

### KEYWORDS

Alcohol; codeine; naltrexone

Abstract:0322

## Increased Cardiovascular Risks Due to Substance Use Disorder by a Woman with Marfan Syndrome and Post-Traumatic Stress Disorder

Hasan Mervan Aytaç and Mehmet Can Ger

Department of Psychiatry, Bakirkoy Prof. Dr. Mazhar Osman Training and Research Hospital for Psychiatry, Neurology and Neurosurgery, Istanbul, Turkey

E-mail address: [mervan176@hotmail.com](mailto:mervan176@hotmail.com)

### ABSTRACT

A woman with Marfan syndrome (MFS) will be discussed who also suffers from multiple substance use disorder and post-traumatic stress disorder. MFS is one of the most common inherited disorders of connective tissue with ocular, cardiovascular and musculoskeletal abnormalities. MFS displays a number of abnormalities of the thoracic and abdominal aorta, ranging from abnormal aortic stiffness to aortic aneurysm and dissection. The case is delivered to a psychiatry clinic after being raped and committing suicide by taking excessive doses of drugs. First, she got the diagnosis of post-traumatic stress disorder and multiple substance use disorder. She began to abuse cocaine, cannabis, ecstasy after the traumatic event. In addition clinicians noticed a disproportionate length of the upper limbs, advanced myopia and lens subluxation in both eyes of her. Transthoracic ECO presented aortic root dilatation and aortic insufficiency with mitral valve prolapses, so she had also the preliminary diagnosis of MFS. After she left the hospital she continued to abuse methamphetamine and cocaine until she was arrested. Among women with PTSD the most common comorbid disorders are depression or anxiety, followed by substance abuse disorder. PTSD may follow substance abuse, which may also mediate developing PTSD. It may also follow PTSD by serving as a "self-medication". Methamphetamine abuse is associated with structural and functional changes of hearts, leading to aortic dissection, cardiac hypertrophy, fibrosis, dilated cardiomyopathy, congestive heart failure and sudden death as the cocaine abuse which is also associated with acute cardiovascular illness, including myocardial ischemia and infarction, aortic dissection and rupture, arrhythmias, myocarditis and vasculitis. We want to draw attention to the increased risk of cardiovascular complications by a women case with MFS who abuse substances like methamphetamine and cocaine.

### KEYWORDS

Marfan syndrome; cardiovascular disease; methamphetamine; cocaine; drug abuse; mortality



Abstract:0458

## Phencyclidine: Is It a Herb or an Angel Dust? A Case Report

Abdullah Atli<sup>a</sup>, Aslıhan Okan İbiloğlu<sup>a</sup> and Mehmet Asoğlu<sup>b</sup>

<sup>a</sup>Department of Psychiatry, Dicle University, Diyarbakır, Turkey; <sup>b</sup>Department of Psychiatry, Harran University, Sanlıurfa, Turkey

E-mail address: [mehmetasoglu@gmail.com](mailto:mehmetasoglu@gmail.com)

### ABSTRACT

Phencyclidine [1-(1-phenylcyclohexyl) piperidine] (PCP) is a hallucinogenic drug that is capable of inducing psychosis. Phencyclidine (PCP) has many names - peace pills, angel dust, angel's mist, goon, hog, 2Ts etc.- and may be found as dilute powder alone or mixed with lysergide, amphetamine, cocaine, tetrahydrocannabinol, or mescaline. PCP functions primarily as an N-methyl-D-aspartate (NMDA) receptor antagonist in the central nervous system, thus inhibiting activity at the NMDA sites. Severe NMDA receptor hypofunction can elicit clinical symptoms similar to psychotic disorders. Also, most common side effects of PCP are nystagmus, hypertension and hyperthermia. We reported here, a case of PCP-induced psychosis and successfully treated with quetiapine are described. A 34 year-old woman, single, university graduate, civil servant presents to our psychiatry department with complaints of persecution and reference delusions, restlessness, insomnia, auditory hallucinations particularly in the evening. The patient went to the herbal medicine shop because of the fatigue complaint and bought a different herbal mixture. However, she had psychiatric complaints two days later after receiving herbal mixture. There is no family history of mental illness. Physical examination is virtually unremarkable. At the admission, PCP was detected as a result of urine screening tests. After then, she was diagnosed to psychosis due to the substance abuse and started quetiapine 600 mg/day. Two weeks after treatment started, her symptoms completely improved. Hallucinogens include mescaline, phencyclidine and scopolamine, benzotropine, trihexyphenidyl and biperiden. Among these, the most commonly abused substance is phencyclidine. Phencyclidine-induced psychosis lasts from 1 to 30 days with average 4 to 5 days. However, phencyclidine can be detected in screening tests up to 8 days. As a result, we present here a case using phencyclidine as involuntarily, and also eventually developing psychosis. At the end, all physicians should be aware of this substance when treating acute onset psychosis without any psychiatric history.

### KEYWORDS

Phencyclidine; herbal medicine; psychosis

Abstract:0142

## Frontotemporal Lobar Degeneration in a Case with the Signs of Depression

Ayşe Çakır, Demet Sağlam Aykut and Ahmet Tiryaki

Department of Psychiatry, Karadeniz Technical University, Trabzon, Turkey

E-mail address: [çakirayseee@gmail.com](mailto:çakirayseee@gmail.com)

### ABSTRACT

Frontotemporal lobar degeneration (FTLD) is a heterogenic neurodegenerative disease which is seen with behavior changes or progressive language disorders. FTLD may present with insidious personality changes, impairment of interpersonal relationships and affectivity, depression, apathy, anxiety, euphoria, irritability. In this case report, we aim to draw attention to psychiatric symptoms of FTLD. A 53 year-old, graduated from university, married, retired, male patient applied with complications of unhappiness, unwillingness, future anxiety, reticence, dullness, withdrawal, indifference to usual hobbies. He also complained of sleeplessness, loss of appetite, loss of weight, heat burden during daytime, tremor in the hands and dull face. The patient was internalized. Psychological examination of the patients revealed; less caring of himself, slow and less speaking, obtuse affectivity, dysphoric mood; spontaneous attention was defected, immediate memory and cognitive functions were normal. Association of ideas was slow, thought context was poor. Neurological examination revealed decreasing of face mimics and jests and walking with small steps. MRI (Magnetic Resonance Imaging) detected bilateral atrophy in frontotemporal region. Patient was pre-diagnosed with FTLD by clinical signs and MRI report and he was consulted to neurology department. Treatment was settled as levodopa 250 mg/day and escitalopram 10 mg/day. Starting from the second day of treatment, movement of the patients fastened; dull face, sleeplessness and loss of appetite were resolved. Patient was externalized with the suggestions of neurology and geropsychiatry consultations. Even psychiatric signs of FTLD are seen often, studies evaluating the psychiatric disturbance prevalence are limited. Structural and functional imaging is supportive to behavioral variants of FTLD but psychiatric and behavioral signs without cognitive disturbance can be seen in prodromal period of

### KEYWORDS

Frontotemporal lobar degeneration; depression; psychiatric symptoms



FLTD. In this case presentation we thought of FTLD diagnosis in a subject presented with depression signs. In this context, we underline that psychological signs can cause to overlook a FLTD case.

Abstract:0205

## Abolition of Guardianship After Treatment of Neurosyphilis: A Case Report

Gülşah Güçlü Çelme<sup>a</sup>, Mehmet Hamid Boztaş<sup>a</sup> and Fatma Sırmatel<sup>b</sup>

<sup>a</sup>Department of Psychiatry, Abant İzzet Baysal University, Bolu, Turkey; <sup>b</sup>Department of Infectious Diseases, Abant İzzet Baysal University, Bolu, Turkey

E-mail address: [gulsahcelme@gmail.com](mailto:gulsahcelme@gmail.com)

### ABSTRACT

Neurosyphilis is caused by infection of the central nervous system of *Treponema pallidum*. Among its clinical presentations are meningovascular syphilis, tabes dorsalis and dementia paralytica and dementia is seen in more than 60% of psychiatric patients with neurosyphilis. In this case report, we wanted to present the patient who had taken under custody with dementia to be diagnosed with neurosyphilis, improvement of cognitive functions after the treatment and the abolition of guardianship. The patient was a 77 year-old woman. She presented to our outpatient clinic after she was referred by the health board for removal of her guardianship. In the patient history, in 2007, Trazodone was given with a diagnosis of "Sleep Disorder". In 2008, Donepezil and acetylsalicylic acid were began to the patient who consulted to neurology with diagnosis of "Dementia" after dysmnnesia and loss of balance. Forgetting her children, leaving home unaware, getting lost, not to pay attention to cleanliness, eating with pouring foods, taking shower with help and becoming introverted were added over time. A guardian was appointed to her with the diagnosis of "Dementia" in petitioning for her custody in 2014. In 2015, she hospitalized with a diagnosis of neurosyphilis and treated with crystallized penicillin. Dysmnnesia, concentration impairment, weakening of discernment with dementia also could be seen in prodromal symptoms and also cerebrovascular pathologies may occur. The patient's waist-leg pain, loss of balance and difficulty in walking provided laboratory tests with thinking the wide range of organic pathology and neurosyphilis is diagnosed. Penicillin has been the mainstay of treatment of neurosyphilis for decades. There is no gold standard for the diagnosis of neurosyphilis, but early diagnosis and treatment is important because it is thought to be a reversible form of dementia.

### KEYWORDS

Dementia; depression; neurosyphilis

Abstract:0250

## Creutzfeldt-Jacob Disease Presenting with Psychomotor Agitation: A Case Report

Yasin Hasan Balcioglu<sup>a</sup>, Mucahid Erdogan<sup>b</sup>, Cengiz Dayan<sup>b</sup> and Hayrunisa Dilek Atakli<sup>b</sup>

<sup>a</sup>Department of Psychiatry, Bakirkoy Prof. Dr. Mazhar Osman Training and Research Hospital for Psychiatry, Neurology and Neurosurgery, Istanbul, Turkey; <sup>b</sup>Department of Neurology, Bakirkoy Prof. Dr. Mazhar Osman Training and Research Hospital for Psychiatry, Neurology and Neurosurgery, Istanbul, Turkey

E-mail address: [yasinhasanbalcioglu@bakirkoyruhsinir.gov.tr](mailto:yasinhasanbalcioglu@bakirkoyruhsinir.gov.tr)

### ABSTRACT

Creutzfeldt-Jacob Disease (CJD) is a rare, prion-associated neurodegenerative disorder that characterized by rapidly progressive dementia and neuropsychiatric symptoms. Neuropsychiatric symptoms are prominently but infrequently manifest in the symptomatology of CJD. Conditions like confusion, agitation, mood and behavioral disturbances, psychosis or depression are reported in concurrence. This report aimed to present a case of sporadic CJD with psychomotor agitation that required hospitalization. A 62-year-old female patient presented with behavioral changes. She had uncontrolled behavior and forgetfulness for approximately one year. She has been coming to follow ups about her dementia. She had brought to emergency room by her relatives for increase in her uncontrolled behaviors and loss of communication for one and a half month. Magnetic

### KEYWORDS

Agitation; antipsychotics; Creutzfeldt-Jacob Disease; dementia

resonance imaging (MRI) showed bilateral diffuse cortical diffusion restriction, bilateral increased signal of putamen and caudate. Electroencephalogram showed generalized periodic sharp wave complexes occurring every 1–2 seconds. Preliminary diagnosis of CJD was made and the patient was admitted to inpatient clinics for further evaluation. No myoclonus was seen while the patient was in clinic. The patient was agitated and low-dose risperidone was initiated. She was discharged after improvement in her behavioral disturbance with the neuroleptic treatment. Rapidly progressive cognitive deterioration is the main neuropsychiatric symptom of CJD. Behavioral disturbances such as agitation and aggression were frequently described in dementia with the presence of psychotic features, however, non-psychotic psychomotor disinhibition disturbances were also recognized in different dementia syndromes. Agitation and repetitive vocalizations were commonly considered as startle reactions in CJD and often coexisted with stimulus-sensitive myoclonus, particularly in the latter stages of the disease. Structural and functional deficits in the specific brain regions such as anterior cingulate were blamed for agitated behavior. Behavioral disturbances reduce life quality in CJD and appropriate management of the symptoms would lessen the burden on caregivers and health-care professionals.

Abstract:0260

## Clinical Manifestation of Delusional Disorder in a Frontotemporal Dementia Case

Gülşen Kartalci<sup>a</sup>, Ebru Yücel<sup>b</sup> and Şükrü Kartalci<sup>a</sup>

<sup>a</sup>Department of Psychiatry, Inonu University, Malatya, Turkey; <sup>b</sup>Department of Neurology, Inonu University, Malatya, Turkey

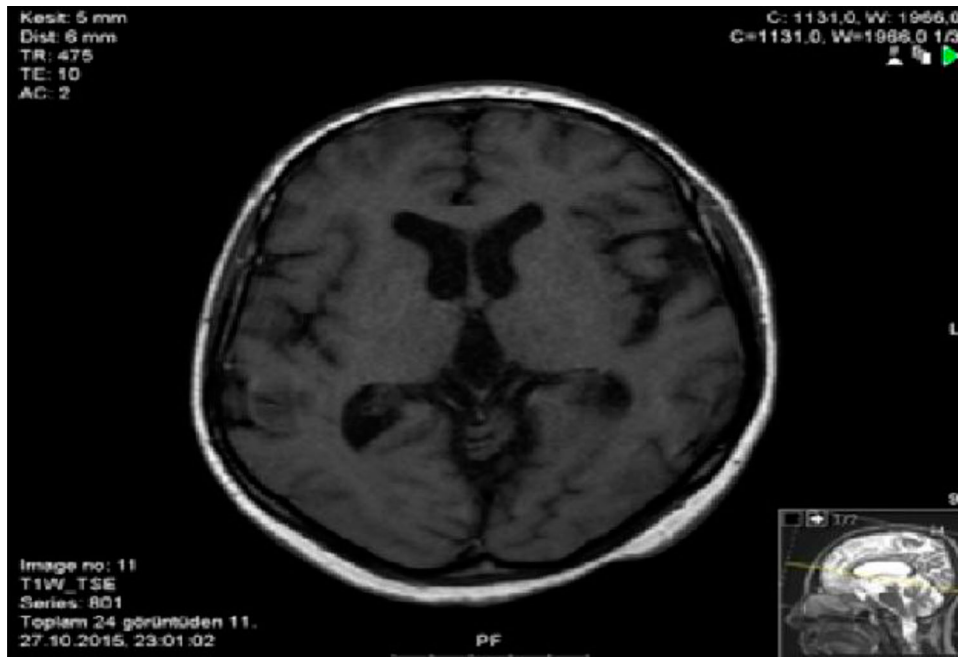E-mail address: [drgulsen44@gmail.com](mailto:drgulsen44@gmail.com)

### ABSTRACT

Frontotemporal dementia (FD) is a neurodegenerative disease characterized by progressive deficits in behavior, executive functions and speech. It commonly occurs in patients younger than 65 years. The disease can be confused with psychiatric disorders because of age of onset and distinctive behavioral features. This case involves the atypical presentation of a FD patient who presents with some delusions. A 59 year-old female patient who had a 2 years history of delusional disorder and with no known additional past psychiatric history, presented to our clinic with nervousness, decreased sociability, paranoid delusions, abusive speech, and anger. The patient also had an occasional complaint of forgetfulness. The two sisters of the patient had similar complaints at the same age, and they died at the age of 57 and 55. In the mental status examination; she was conscious, her speech and movement were slow, voice tone was low, thought content was poor and mostly composed of paranoid delusions, affection was limited, facial expressions decreased and she had no insight. Minor memory defects were detected. Her physical and neurological examination was normal. Standardized Mini Mental Test Score was 20/30. Cranial MR imaging revealed atrophy in the bilateral frontotemporal regions, secondary dilatation in central CSF fields (figure 1). 3 variants of FD have been described; frontal lobe, semantic dementia and progressive arrest aphasia. In our case, the clinical appearance was compatible with frontal lobe variant. This patient was previously followed up with the diagnosis of delusional disorder. The presence of cognitive impairments, imaging findings, and the presence of a similar disease history in her two sisters support the diagnosis of FD. In patients with atypical psychotic symptoms, inappropriate social behavior, and personality changes in late adulthood; performance of detailed neuropsychological evaluation and cranial imaging could be useful in differential diagnosis.

### KEYWORDS

Frontotemporal dementia; psychosis; delusion



**Figure 1.** Atrophy in the bilateral frontotemporal regions, secondary dilatation in central CSF fields in MRI of the brain.

Abstract:0347

## Depressive Symptoms at Onset of Parkinson's Disease: A Case Report

Meliha Zengin Eroğlu, Arif Çipil and Mecit Çalışkan

Department of Psychiatry, Haydarpasa Numune Research and Training Hospital, Istanbul, Turkey

E-mail address: [melihazengin@gmail.com](mailto:melihazengin@gmail.com)

### ABSTRACT

Parkinson's disease can be defined as a neuropsychiatric disease which is basically a dysmotility disease, often with affective cognitive and psychotic disorder. Some of Parkinson's disease symptoms are similar to depression symptoms and sometimes intertwined. The 30-40% of patients with PD have significant depressive symptoms. In this paper a depressive woman who presented Parkinson's disease will be discussed. A 46-years old woman followed for depressive symptoms such as low mood, altered appetite, loss of libido and psychomotor retardation for a year from our outpatient psychiatry clinic. She got duloxetine 60 mg/day for 4 months. During psychiatric follow up she complained from hoarseness, dysphagia, slowness of movement and thinking. Ear, Nose, and Throat (ENT) specialist's physical exams were within normal limits. Later bradykinesia, bradyimia, difficulty at walking added to her clinical appearance. After the evaluation of neurologist she diagnosed as Parkinson's disease. Cerebral tomography and magnetic resonance imaging were at normal limits. Although it typically develops after the age of 65, about 15% of people with the condition develop young-onset Parkinson disease before reaching age 50. Sometimes Parkinson's symptoms can start like psychiatric disease. So clinicians must be careful to neurologic diseases at young psychiatric population.

### KEYWORDS

Parkinson's disease; depression; antidepressant

Abstract:0367

## Medically Unexplained Symptoms in the Course of Dementia

Semra Ulusoy Kaymak<sup>a</sup>, Görkem Karakaş Uğurlu<sup>b</sup>, Oğuz Peker<sup>b</sup>, Zuhal Koç<sup>a</sup>, Murat İlhan Atagün<sup>b</sup> and Ali Çayköylü<sup>b</sup>

<sup>a</sup>Ankara Atatürk Research and Training Hospital, Psychiatry Clinic; <sup>b</sup>Department of Psychiatry, Yıldırım Beyazıt University School of Medicine, Ankara

E-mail address: [zuhalkoc\\_19@hotmail.com](mailto:zuhalkoc_19@hotmail.com)

**ABSTRACT**

In older patients, depression and dementia may appear with different symptomatology. Particularly somatic complaints, which are unexplained, must be carefully examined in terms of an underlying physical and psychiatric disorders. The patient was a 73 year-old woman. Her relatives brought her to the psychiatry outpatient clinic with anal pain and related agitation. She was suffering from anal pain since 2004 when she had a head injury with a tile. For the days after that she had complaints of low mood, anhedonia, irritability, loss of appetite and insomnia. She used quetiapine and diazepam for those complaints and there was no response. She retired. Since 2004 she had been using sertraline, venlafaxine, fluoxetine, mirtazapine, moclobemide and olanzapine in separated times. In addition to the initial symptoms, she suffered from lack of self-care, social withdrawal, complaints of continuous anal pain, increased eating to prevent of the harm of the drugs to her body in 2016. She was admitted in our inpatient unit with those symptoms and after the first examination she was hospitalized due to agitation because of anal pain. She was indifference, apathetic and do confabulate instead of being depressed or unwilling. She had medically unexplained somatic complaints as anal pain or abdominal pain. The initiation of sleep disturbed with agitation. MMSE score was 16. Generalized atrophy and sulcal widening were detected in her Brain MRI. When asked to family to rethink about memory and cognitive symptoms, family realized the hints. In this case we want to remind some points in the elderly: 1) To screen neurocognitive functions regularly of patients, who are older than 65, is crucial. 2) Depression could be the initial scene of dementia. 3) Somatic signs must be evaluated in detail in psychiatric and physical manner.

**KEYWORDS**

Dementia; geriatric psychiatry; medically unexplained somatic symptoms

Abstract:0452

## Difficulties in the Diagnostic Process of Dementia With Lewy Bodies: A Case Report

Abdullah Atli<sup>a</sup>, Aslıhan Okan İbiloğlu<sup>a</sup> and Mehmet Asoğlu<sup>b</sup>

<sup>a</sup>Department of Psychiatry, Dicle University, Diyarbakır, Turkey; <sup>b</sup>Department of Psychiatry, Harran University, Sanlıurfa, Turkey

E-mail address: [mehmetasoglu@gmail.com](mailto:mehmetasoglu@gmail.com)

**ABSTRACT**

Dementia is a neurodegenerative disorder with the progressive memory decline. Dementia with Lewy bodies (DLB) is the second most common type of dementia after the Alzheimer's disease. Main features of the DLB are fluctuating cognitive symptoms, visual hallucinations and spontaneous parkinsonism. The patient was a 54 year-old married man, farmer, admitted to our psychiatry inpatient department with depressive mood, shouting during the sleep, attention disorder, anhedonia, persecutory delusions, and progressive memory decline. Also, on his neurological examination bradykinesia, rigidity, and tremor were detected. Cognitive examination showing impaired concentration, impaired verbal fluency, and impaired (executive) frontal system functions. He was diagnosed with depressive disorder and has been treated with escitalopram 20 mg/day and olanzapine 10 mg/day, over the past 12 months without much benefit. Therefore, his treatment was stopped. After then, we ordered vortioxetine 20 mg/day and aripiprazole 30 mg/day or the treatment of complaints in this patient. Initially, it was quite helpful for depression and several cognitive symptoms related with dementia. The diagnoses were revised to dementia with Lewy bodies with depressive disorder. Most causes of dementia such as Alzheimer's disease, vascular dementia, Wilson's disease, Parkinson's disease and neuroacanthocytosis also need to be carefully considered. It's known that, DLB which constituted to 20% of dementia patients is the second most common type of dementia. Main features of the DLB are fluctuating cognitive symptoms, visual hallucinations and parkinsonism like as the EPS. Other common symptoms including the fainting, recurrent falls, transient loss of consciousness or delirium, sleep disturbances, depression, anxiety symptoms, delirium, and antipsychotic hypersensitivity. Initially, depressive symptoms of the patients lightly improved. Unfortunately, this improvement did not continue, in the following days. Additionally, severe EPS were occurred. Our obese patient had sleep apnea syndrome. For this reason, many symptoms of sleep behavior disorder can be recognized late. It should be remembered that, cognitive function should be carefully assessed and will uncover organic disorders or the pseudodementia of depression. As a result, The patient's cognitive and functional status significantly improved. Our aim was to share these beneficial observations for similar patients.

**KEYWORDS**

Dementia with Lewy bodies; depression; psychosis; sleep related behavior disorder

Abstract:0160

## Arachnoid Cyst with First Episode Psychosis: A Case Report

Dudu Demiröz, Hatice Yardım Özyayhan, Zeynep Yücehan, Tuba Şerife Elmas and İbrahim Eren

Department of Psychiatry, Konya Research and Training Hospital, Konya, Turkey

E-mail address: [drdemiroz42@gmail.com](mailto:drdemiroz42@gmail.com)

### ABSTRACT

Arachnoid cysts are cerebrospinal fluid containing, usually with no clinical signs, determined by radiological examinations accidentally and space-occupying lesions. This article presents the treatment process of the arachnoid cyst and the disease, which was determined as the first episode of psychosis with 3 years duration of psychosis without treatment. A 17 year-old, male patient, first complaints started in the way of frequent hand washing, touching with fear of getting polluted by objects. Three years ago, thinking of being followed, skepticism, auditory hallucination, visual hallucination, carelessness, unhappiness, forgetfulness were added. Neuroimaging revealed an arachnoid cyst in the frontal region. The patient's treatment whose family support is inadequate and who has no insight was set as risperidone depot. After 1.5 months there was a decline in psychotic symptoms. There are many studies showing the relationship between psychotic findings and brain abnormalities. In our case, arachnoid cysts was seen in the size of 20×13 mm in the left frontal region. The other characteristic of the case is that despite the positive psychotic statement that has been going on for 3 years, it has not been treated. The duration of psychosis without treatment in psychotic episodes can be 1 to 2 years. This period can be even longer due to the deterioration of the socio-cultural environment and functioning of the person. The application for treatment is delayed due to the low sociocultural level in our case. It has been reported that atypical antipsychotics are a good option for psychotic disorders due to organic causes and short-psychotic disorder related to arachnoid cyst responding to risperidone treatment. Although the relationship between brain structural abnormalities and psychiatric manifestations cannot be clearly elucidated, first episode psychosis, atypical psychotic features, impaired cognitive abilities should lead us to investigate the organic causes of psychosis.

### KEYWORDS

Arachnoid cyst; first episode psychosis; risperidone

Abstract:0236

## Mega Cisterna Magna in a Patient with Schizoaffective Disorder Incidentally Found Prior to Electroconvulsive Therapy

Ebru Findıklı

Department of Psychiatry, Sütçü İmam University, Kahramanmaraş, Turkey

E-mail address: [ebruhanmaz@gmail.com](mailto:ebruhanmaz@gmail.com)

### ABSTRACT

Cerebellar dysfunction has been associated with schizophrenia, schizoaffective disorder and bipolar disorder among psychiatric disorders. The term Dandy-Walker complex describes a continuum of anomalies in the posterior fossa classified as classic Dandy-Walker malformation, Dandy-Walker variant and mega cisterna magna (MSM) (enlarged cisterna magna with integrity of both cerebellar vermis and fourth ventricle). We report first time a case of treatment resistant schizoaffective disorder in a 23-year-old man with MSM which caused distractibility and atypical symptoms and was noticed by chance before electroconvulsive therapy (ECT) protocol. Our case is a 23-year-old single, male, patient who meets the DSM 5 criteria for schizoaffective disorder (bipolar type). He presented with paranoid thoughts, affective flattening, highly disorganized speech and behavior for the past 2 months and manic and depressive episodes in his history. The neurological exam did not reveal any changes, the Mini-Mental State Examination, EEG and biochemical results were evaluated as normal. The patient was admitted to our clinic because his symptoms were resistant to the medications, ECT was planned for. A giant arachnoid cyst was observed in the brain MR scans of the patient done after the pre-ECT protocol (Figure 1a-1b). The concurrence of MSM and schizoaffective disorder as detected by coincidence prior to ECT, or the contribution of cerebellum pathologies to the formation of psychiatric disorders or their effect on the clinical manifestation have been presented in this case report. Previously the association between MSM and psychiatric diseases such as psychosis mania, obsessive-compulsive disorder with schizophrenia and catatonia was presented as case reports, but the association between psychiatric symptoms and MSM still remains elusive because of the scarcity of sufficient data. It will contribute to the literature in terms of clarifying the relationships between organic brain lesions and psychiatric portraits.

### KEYWORDS

Schizoaffective disorder; mega cisterna magna; cerebellum; vermis; psychosis; arachnoid cyst

Abstract:0042

## History of Trauma and Current Posttraumatic Stress Disorder in Trichotillomania: A Case Report

Hasan Mervan Aytac

Bakırköy Prof. Dr. Mazhar Osman Mental Health and Neurological Diseases Training and Research Hospital, Istanbul, Turkey

E-mail address: [mervan176@hotmail.com](mailto:mervan176@hotmail.com)

### ABSTRACT

Interaction of environmental, biological, and psychological factors is important in the development of trichotillomania and skin tract. While some clinicians assume that trauma and posttraumatic stress disorder may be related to the etiological basis of trichotillomania, very few research has examined this hypothesis up to date. A 20-year-old, single, graduated from high school, male applied to emergency psychiatric clinic with intense anxiety due to continuous hand washing, spending long time in shower and checking lower part of the trouser leg constantly. Patient was wearing shorts even in unfavorable weather because he constantly checked his lower part of trouser leg. During the examination, it was observed rarity of both lateral of eyebrows and in hairs on lower region of jaw. Patient expressed decrease in anxiety level after voice he heard during breakup of his hair. It was felt the need to deepen anamnesis to learn the presence of triggering stressors since all complaints had begun to increase for last 1 year. During interview, it was learned that about 1 year ago the patient lost his best friend in traffic accident. When he visited his friend, learned that his friend had lost his life with internal bleeding shortly after he was removed to the hospital. Patient expressed that since he had seen fragmented dead body of his friend, had never forgot that day and his friend was always in front of his eyes. It was learned that patient had hand tremors and sudden reactions even when he hear least noise. He said that he was hesitant to apply to hospital since it reminded him of event about his friend's accident and so he had come psychiatry emergency in place of outpatient clinic. Fluoxetine 20 mg/day, risperidone 0.5 mg/day were prescribed for ruminations and anxiety. Studies suggest that prevalence of PTSD in trichotillomania may be higher than in general population and that more different type trauma story is related to duration of hair pulling period and location of bald area.

### KEYWORDS

Trichotillomania; trauma; posttraumatic stress disorder

Abstract:0414

## Propranolol-Induced Amnesia and Confabulation in an Adolescent with Dissociative Disorder

Berkan Şahin and Koray Karabekiroğlu

Department of Child and Adolescent Psychiatry, Ondokuz Mayıs University, Samsun, Turkey

E-mail address: [mail.berkan@gmail.com](mailto:mail.berkan@gmail.com)

### ABSTRACT

The relationship between childhood trauma and dissociation is shown both retrospectively and prospectively. Amnesia and memory problems, hallucinations, and secondary psychiatric symptoms are common. The use of propranolol for the prevention and treatment of post-traumatic stress disorder and dissociative symptoms and the elimination of traumatic memories is reported. The effectiveness is controversial. Here we report symptoms of amnesia and confabulation following the use of propranolol in an adolescent who has dissociative disorder. A 13 year-old female adolescent, has normal developmental history. Six months ago, she had a car accident. There was no head trauma. Post-accident examination and brain imaging were reported as normal. After one month from the accident her psychiatric symptoms had started such as fear, anxiety about the accident, visual and auditory hallucinations, illusion, self-harming. The hallucinations are predominantly hypnagogic and hypnopompic. One month after the accident, fluoxetine and propranolol were started by an outpatient clinic. After medication treatment amnesia is occurred. She told her doctor she was exposed to sexual abuse by her brother. She was taken from the family by the social services. At first check in our clinic, she was confused about sexual abuse. She said she had rape images. She also said she was sexually abused by a boy when she was five years old. It was learned the information was not correct. The patient was diagnosed with dissociative disorder and depressive disorder. Propranolol was discontinued. Mirtazapine and risperidone were started. Amnesia, hallucinations and illusions were

### KEYWORDS

Propranolol; dissociative disorder; amnesia; confabulation; adolescent; childhood trauma



completely lost after two months. There was no images about sexual abuse. Risperidone was discontinued. Social services planned the adolescent girl to be sent to her family. In this case, we report that the use of propranolol may increase dissociative symptoms so that the propranolol use may not be appropriate in patients with dissociative disorder.

Abstract:0114

## Postpartum Onset Skin-Picking Disorder Exacerbates with a Sexual Trauma: A Case Report

Mustafa Kurt<sup>a</sup>, Çağdaş Öykü Memiş<sup>a</sup>, Bilge Doğan<sup>a</sup>, Doğa Sevinçok<sup>b</sup> and Levent Sevinçok<sup>a</sup>

<sup>a</sup>Department of Psychiatry, Adnan Menderes University, Aydın, Turkey; <sup>b</sup>Department of Child and Adolescent Psychiatry, Dr. Behçet Uz Child Diseases and Surgery Research and Training Hospital, İzmir, Turkey

E-mail address: [mustafakurt61@outlook.com](mailto:mustafakurt61@outlook.com)

### ABSTRACT

Skin picking disorder (SPD), is characterized by repetitive and compulsive picking of skin, leading to tissue damage. SPD has been classified under obsessive-compulsive and related disorders title in DSM-5. Among young women, history of sexual abuse and rape in childhood were found to be predictors of SPD. Strong evidence suggests that women are at risk for the development of psychiatric disorders in the postpartum period. To our knowledge, there has been no report on postpartum onset SPD to date. We here report a case of SPD presented initially a postpartum onset and exacerbated following a sexual trauma long years after her delivery. A 43 year-old married female presented to psychiatry department with the complaints of excessive picking of skin of the fingers, forearms, abdomen and legs which occurred within the first month of her first delivery 12 years ago. Her SP exacerbated after a sexual assault three years ago. She also developed some posttraumatic symptoms such as flashbacks, hyperarousal, hypervigilance, nightmares and re-experiencing traumatic event. On the basis of current psychiatric examination, she received the diagnoses of SPD, PTSD, and major depression. She had no dermatological or infectious etiologies of the skin picking. She had not previously used any substance or other medications which might cause skin picking behavior. The occurrence of SPD in the postpartum period may be linked to extreme fluctuations in reproductive hormones. In our case, to give birth and experiencing a sexual trauma might have led to emotional and relational vulnerabilities. Developing SP symptoms might help her to cope with intrusive thoughts related to trauma. Future prospective research is necessary to clarify prevalence of SPD or other OCD-related or impulsive disorders during postpartum period. Particularly, it is noteworthy to examine the possible relationship between SPD and aggressive obsessions in future studies.

### KEYWORDS

Skin-picking disorder; postpartum onset; trauma

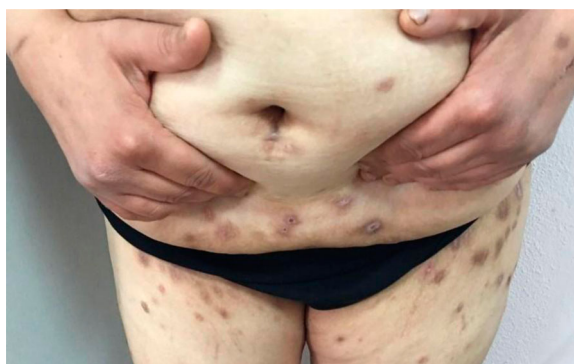

Figure 1. Skin picking lesions on the lower abdomen



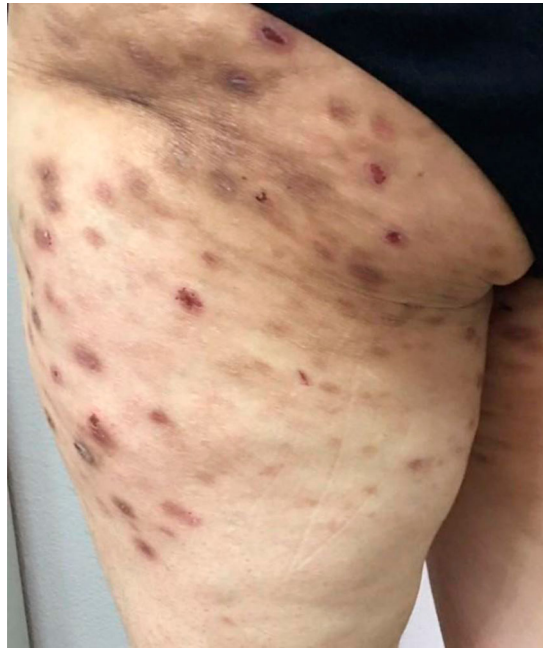

Figure 2. Skin picking lesions on the left upper thigh

Abstract:0118

## Effectiveness of Low Dose Aripiprazole Monotherapy in the Treatment of an Adolescent with Obsessive-Compulsive Disorder

Merve Sertdemir and Ömer Faruk Akça

Department of Child and Adolescent Psychiatry, Necmettin Erbakan University Meram School of Medicine, Konya, Turkey

E-mail address: [dcuramerve@gmail.com](mailto:dcuramerve@gmail.com)

### ABSTRACT

Obsessive-compulsive disorder (OCD) affects 1 to 3 percent of children and adolescents, causing serious disruption in their social and academic functioning. Cognitive Behavioral Therapy (CBT) and pharmacotherapy-with selective serotonin reuptake inhibitors (SSRIs) and clomipramine-are suggested treatment options for children and adolescents with this disorder. However, many patients do not respond to these treatment strategies. The augmentation of SSRIs or clomipramine with aripiprazole is reported to be an effective strategy for adults with treatment-refractor OCD. Nevertheless, studies on its use as monotherapy are limited in treating OCD in both children and adults. A 13 year-old girl was referred to our clinic with complaints of irritability and aggressive behavioral problems. She described being overwhelmed by obsessions that she could harm or kill her father and sister, and could have an incestuous relationship with them. In addition to frequently seeking reassurance and confirmation from her mother with regards to these issues, she took measure to prevent damage to her father and sister. Aripiprazole medication was started at 2.5 mg/day. The Childhood Yale-Brown Obsessive Compulsive Scale (CY-BOCS) and Clinical Global Impression-Severity Scale (CGI) were performed. CY-BOCS score was 26, and CGI score was 6 for OCD symptoms and 6 for aggressive symptoms in the initial assessment. At the first week of treatment, the aripiprazole dose was increased to 5 mg/day. CY-BOCS scale scores were 1 and CGI scores decreased to 1 for OCD symptoms and 2 for aggressive symptoms in the eighth week of treatment. We present an adolescent patient has complaints of severe aggressive behaviors and moderate OCD symptoms. These symptoms disappeared following the administration of low dose aripiprazole monotherapy. Our case supports the notion that aripiprazole, which is mostly used for antipsychotic and anti-aggressive purposes in current practice, may be an option as monotherapy even at low doses in the treatment of children and adolescents with OCD due to both its effects on the dopaminergic system and serotonergic systems.

### KEYWORDS

Aripiprazole; obsessive-compulsive disorder; monotherapy; adolescent

Abstract:0132

## Compulsion of Misidentification in a Patient with Obsessive-Compulsive Disorder

Doğa Sevinçok<sup>a</sup>, Çağdaş Öykü Memiş<sup>b</sup>, Bilge Doğan<sup>b</sup> and Levent Sevinçok<sup>b</sup><sup>a</sup>Department of Child and Adolescent Psychiatry, Dr. Behçet Uz Child Diseases and Surgery Training and Research Hospital, Izmir, Turkey;<sup>b</sup>Department of Psychiatry, Adnan Menderes University, Aydın, TurkeyE-mail address: [dsevincok@hotmail.com](mailto:dsevincok@hotmail.com)

### ABSTRACT

The patients with Delusional Misidentification Syndromes (DMS) misidentify or reduplicates familiar individuals, objects, places or events. DMS have been rarely reported in patients with non-psychotic conditions. We here present an obsessive-compulsive disorder (OCD) case who exhibited a compulsion of misidentification. To our knowledge, this is the first case with OCD exhibiting a misidentification compulsion. A 33 year-old man was admitted in psychiatry ward suffering from substitution of some unfamiliar faces that seemed to be dangerous for his wife and children, with consecutively three different previously known person faces. Unless he did not substitute his face with these faces, he would not decrease his anxiety. His first obsessive-compulsive symptoms emerged at eight years-old with ordering/symmetry obsessions and compulsions. Five years later, he began to substitute the faces of subjects he thought as harmful, with three previously known people. He described a full remission with a treatment of fluoxetine, sertraline, and quetiapine for the next eight years. Two years ago, the compulsion of misidentification emerged as well as an exacerbation of ordering/symmetry obsessions and compulsions. His current score on the Yale-Brown Obsessive Compulsive Scale (Y-BOCS) was 38. His MRI scan, EEG and biochemical tests were normal. He was already started 75 mg/day of clomipramine, 100 mg/day of sertraline, 5 mg/day of aripiprazole, and 2 mg/day of haloperidol. Previously, it was reported that a woman with OCD had doubts about whether her husband, her parents, her cat, and even the city that she lived in had been replaced by identical-appearing duplicates. We here presented a case of OCD exhibiting compulsion of misidentification in order to expel and thus to control his harming and sexual obsessions. The association between forbidden thoughts and misidentification compulsions in our case might represent an example of an overlap between responsibility and threat in OCD patients.

### KEYWORDS

Compulsion;  
misidentification; obsession;  
OCD

Abstract:0230

## Skin-Picking Disorder: A Case Presentation

Rukiye Ay

Malatya State Hospital, Malatya, Turkey

E-mail address: [rukiyeayy@gmail.com](mailto:rukiyeayy@gmail.com)

### ABSTRACT

Skin Picking Disorder includes skin lesions that are created by patients themselves. In this article we present a case of "skin picking disorder". A 42-year old female patient presented to the dermatology department due to an irregularly edged, occasionally crusted lesion in her palm. As a result of the examinations, she was referred to our polyclinic as a case with no dermatological cause. There was a constant scratching demand during the day. As a result of scratching, the wounds developed and she started to peel off the crust over the wounds repetitiously. When she tried to prevent herself, she would feel intense tension, irritability and when she picked the crusts, she would feel relief first, then guilt and regret. Her everyday work was hindered due to her being busy with picking. Complaints such as grief, crying, desire to be alone, insomnia have begun for the last one month due to not being able to stop herself and deteriorating relations with her social circle. There was no physical, mental illness in her medical record. She was diagnosed with "skin picking disorder" and "depressive disorder" according to DSM-5. Sertraline was started at 100 mg/day and add aripiprazole 5 mg/day. Her depressive symptoms disappeared completely at the next visit. She would be able to control herself even if there was a desire to pick. In DSM-5, skin picking disorder takes place in the category of 'obsessive-compulsive disorder and related disorders'. Clinical trials have reported that at least one axis 1 disorder is diagnosed in 57-100% of patients with skin picking disorder. It is a clinical picture that should be kept in mind since the risk of infection is high, that a psychiatric comorbidity usually accompanies and impairs the functionality of the person.

### KEYWORDS

Skin-picking disorder; DSM-5;  
major depressive disorder

Abstract:0296

## Methamphetamine-Induced Obsessive-Compulsive Disorder: A Case Report

Gülser Karakoç, Ayşe Ender Altıntoprak and Hakan Coşkunol

Department of Psychiatry, Ege University School of Medicine, Izmir, Turkey

E-mail address: [gulser\\_karakoc@hotmail.com](mailto:gulser_karakoc@hotmail.com)

### ABSTRACT

Methamphetamine is a powerful, widely abused, addictive stimulant. The psychiatric effects of methamphetamine use are psychosis, suicide, craving, depression and obsessive-compulsive disorder (OCD). A 36 year-old man, with multiple-substance use disorder, presented to our clinic with a desire of quitting substance use. He was used cannabis, pregabalin, cocaine, alprazolam, alcohol, ecstasy before. Five years ago, he started methamphetamine via inhalation and he used it every day for five years. Three years ago, the patient was admitted to the addiction service with auditory and visual hallucinations, persecutory and reference delusions. Following the methamphetamine intoxication in August 2016, he was admitted to the addiction service with psychotic symptoms and self-destructive behavior. He was discharged 1 month later and he did not use methamphetamine afterwards. For the last 4 months, the patient has significantly reduced the amount of substance and he has no psychotic symptoms. However, contamination and symmetry obsessions and cleaning and arranging objects compulsions have begun. He was admitted to the hospital in January 2017 and fluoxetine 20 mg/day, haloperidol 5 mg/day, quetiapine 800 mg/day, zonisamide 100 mg/day, bornaprine 8 mg/day treatment was started. Fluoxetine 40 mg/day and zonisamide 200 mg/day were increased in the follow-up. The patient's substance craving, obsessions and compulsions were diminished. The follow-up of the patient who is in partial remission continues in our clinic. Substance-induced obsessive-compulsive disorder is considerably worse, and more difficult for the individual to control. Although substance-induced OCD is rare, the consequences can be severe. OCD is one of the psychiatric effects of methamphetamine use and abstinence. It is probable that treated OCD in methamphetamine users may relieve craving, and thus may prevent relapse.

### KEYWORDS

Methamphetamine;  
obsessive-compulsive  
disorder; psychosis

Abstract:0297

## Duloxetine in Adolescents with Treatment-Resistant Obsessive-Compulsive Disorder: A Case Report

Ipek Percinel Yazici and Kemal Utku Yazici

Department of Child and Adolescent Psychiatry, Firat University School of Medicine, Elazig, Turkey

E-mail address: [ipek.pr@hotmail.com](mailto:ipek.pr@hotmail.com)

### ABSTRACT

In this present, we report an adolescent diagnosed with treatment-resistant obsessive-compulsive disorder (OCD) who were treated with duloxetine. A 17 year-old girl came to our clinic with contamination obsessions, hand-washing compulsions, feeling dirty all the time. She believed if she hadn't washed her hands 15 times each day, she would have been ill. Her complaints began two years ago. She was followed in another clinic last year, and underwent 13 weeks of cognitive behavioral therapy and effective doses of appropriate medications prescribed including sertraline, fluoxetine, citalopram, clomipramine and aripiprazole, single or combined. She did not benefit from her prior treatment and stopped using medications. Her complaints worsened in the last three months and she referred to our clinic. She was diagnosed as OCD. Considering her prior treatment regimen, duloxetine 30 mg/day was prescribed and one month later its dose was increased to 60 mg/day carefully. After four weeks, there was little clinical response in her symptoms and there was no side effect. The duloxetine dose was increased to 90 mg/day. During the follow-up, she responded well to a dose of 90 mg/day. After six month of duloxetine treatment, there was significant improvement in OCD symptoms. She was tolerated duloxetine very well and there was no side effect. Duloxetine is a serotonin and norepinephrine reuptake inhibitor (SNRI). In this present, we report duloxetine markedly improved her OCD symptoms. The effect of serotonin blockade as well as noradrenergic blockade of duloxetine may be benefit on her symptoms. Several studies and case reports have shown efficacy of duloxetine in adults with OCD. To the best of our knowledge, our patient is the first report in the treatment

### KEYWORDS

Adolescent; duloxetine;  
obsessive-compulsive  
disorder; treatment

adolescent diagnosed with OCD. Duloxetine may be an alternative drug in adolescents diagnosed with treatment-resistant OCD.

Abstract:0341

## Compulsions After Atomoxetine Treatment: A Case Report

Hicran Doğru

Department of Child and Adolescent Psychiatry, Erzurum Regional Training and Research Hospital, Erzurum, Turkey

E-mail address: [hicran\\_ktekin@yahoo.com](mailto:hicran_ktekin@yahoo.com)

### ABSTRACT

Attention-deficit/hyperactivity disorder (ADHD) is a neurodevelopmental disorder incidence of which is 5-10% in childhood. Although stimulants are particularly preferred as effective drugs for this group, in the presence of comorbidities like anxiety disorders atomoxetine is usually preferred. A 12-year-old boy with a known history of ADHD and anxiety co-existence presented to Child and Adolescent Psychiatry clinic with complaints of excessive talking, distractibility and restlessness. As a result of a complete psychiatric exam reinforced with psychometric tests and taking history ADHD and mild level mental retardation were diagnosed and atomoxetine treatment was initiated with a daily dose of 0.5 mg/kg. Keeping in mind the mental retardation, the dosage was slowly increased until the desired therapeutic dose is achieved (1.2 mg/kg/day) at the 3rd month of treatment. However, on the last scheduled appointment his mother stated that he began to continuously wash his hands, collect individual hairs from the ground and constantly tidy up seat coverings. During the follow up, it has been observed that attention, distractibility and anxiety complaints have improved significantly but atomoxetine aggravated compulsive behaviors which were sufficiently severe to cause a significant disruption in functionality. Risperidone was initiated and titrated up until 0.75 mg/day. After 2 months of therapeutic dose his compulsions subsided. Comorbid anxiety disorders can be seen in 25-35% of ADHD patients. This comorbidity state displays more aggressive prognostic features (less compliance with treatment, more adverse effect) than ADHD alone. Mild intellectual disability as in this case might expose the patient to a higher potential risk of additional sensitivity to adverse effects. Clinicians must be careful about this potential neurodevelopmental risk in the co-existence of ADHD and mental retardation.

### KEYWORDS

ADHD; atomoxetine;  
compulsion; obsession

Abstract:0352

## Skin-Picking Disorder: A Case Report

Seda Kiraz, Kevser Altıntaş, Fulya Gök and Meliha Zengin Eroğlu

Department of Psychiatry, Health Sciences University Haydarpaşa Numune Training and Research Hospital, Istanbul, Turkey

E-mail address: [drsedakiraz@gmail.com](mailto:drsedakiraz@gmail.com)

### ABSTRACT

Skin picking disorder is a table characterized with picking skin excessively and repetitively, leading to damage in skin tissue but it is not a dermatological disorder. DSM-5 has been identified as a separate diagnosis and has found the right diagnosis and appropriate treatment. A 19 years old, university student, female patient, applied to our Outpatient Clinic for the first time with the complaint of skin picking for about ten years and therefore not wanting to go out from the house. Mostly under stress and plans for the future, when she argued with her mother, skin-picking behavior increased and she then relaxed for a short time afterwards get the feeling of regret said. When the story was deepened, we learned that her mother had previously undergone psychiatric treatment and had psoriasis, and that her father was addicted to alcohol. On physical examination, on the patient's body, on the face, both arms, chest and legs which were reachable by hand, several millimeters of hyperpigmented erosions and erythematous ulcerated areas were found. On the psychological examination, the mood of the patient was mildly depressive and the emotion were consistent. Avoidance behaviors were present due to their lesions. The patient was diagnosed with DSM-5 skin-picking disorder and fluoxetine 20 mg and risperidone 1 mg were started. In the studies, patients diagnosed with psychogenic skin picking disorder was found to be associated with severity of picking behavior and depressive symptoms. In a

### KEYWORDS

Skin-picking disorder; skin-picking behavior;  
psychogenic skin-picking

study by Odlauk and colleagues, in 40% of patients with at least one first-degree relatives have a psychiatric disorder, especially depression and substance abuse. The case has also been shown in the literature that SSRIs are effective in studies for skin picking disorder treatment. Considering all this, the case supports the literature in many ways.

Abstract:0359

## Early-Term Aripiprazole Augmentation and Clinical Efficacy in Adolescents: A Case Series

Ferhat Yaylaci<sup>a</sup>, Handan Özek Erkuran<sup>b</sup> and Murat Eyüboğlu<sup>c</sup>

<sup>a</sup>Department of Child and Adolescent Psychiatry, Karaman State Hospital, Karaman, Turkey; <sup>b</sup>Department of Child and Adolescent Psychiatry, Dr. Behçet Uz Children's Research and Training Hospital, Izmir, Turkey; <sup>c</sup>Department of Child and Adolescent Psychiatry, Mardin State Hospital, Mardin, Turkey

E-mail address: [handanozek@yahoo.com](mailto:handanozek@yahoo.com)

### ABSTRACT

Obsessive-compulsive disorder (OCD) in children and adolescents is characterized by intrusive thoughts and compulsions that typically cause distress and functional impairment. Guidelines for the treatment of OCD include Cognitive- Behavioral Therapy (CBT) as first line treatment option along with family counseling and psychoeducation. Selective serotonin Reuptake Inhibitors (SSRI) have long been used in the pharmacological treatment of OCD, with much success. Multidrug choices and augmentation strategies have only been proposed for cases that are resistant to treatment. The term "treatment-resistance" reflect persistent and severe continuum of symptoms even though efficient and suggested line of treatment options have been used with indicated dose ranges and time interval. This might reflect unsuccessful response to at least two SSRI use or use of one SSRI and clomipramine along with enough number of CBT sessions. Many drugs have been tried for augmentation, in the face of treatment-resistance. However, these mainly have been conducted with adults and studies that assess augmentation in children and adolescents have been scarce. Some of these have focused on aripiprazole as an option to be used for augmentation. This series comprises the clinical course and treatment process of six adolescents diagnosed with OCD from three different centers in Turkey. Due to different underlying reasons that were elaborately described within each case presentation, recommended treatment guidelines were in a way distorted, resulting in an earlier onset of low- dose add-on aripiprazole, in turn, causing relief in symptoms and clinical severity as well as functional impairment. We hope this case series shall make a contribution to relevant literature and studies designed to improve treatment options and guidelines.

### KEYWORDS

Adolescent; aripiprazole; augmentation; child; obsessive-compulsive disorder; treatment-resistance

Abstract:0410

## Late-Onset Obsessive-Compulsive Disorder Following Cerebrovascular Event: A Case Report

Diğdem Göverti, Rabia Nazik Yüksel, Alper Bülbül, Makbule Çiğdem Aydemir and Erol Göka

Department of Psychiatry, Ankara Numune Training and Research Hospital, Ankara, Turkey

E-mail address: [didem.0010@hotmail.com](mailto:didem.0010@hotmail.com)

### ABSTRACT

Obsessive-compulsive disorder (OCD) is a neuropsychiatric illness characterized by intrusive, repetitive thoughts and ritualistic behaviors. The obsessions or compulsions are time-consuming and interfere significantly with the person's normal routine, occupational functioning, usual social activities, or relationships. Most people are diagnosed by about age 18-25. Some studies classify the OCD as "juvenile-onset" (<18 years), "adult-onset" (18-39 years), and "late-onset" (≥40 years)." We report a patient with late-onset OCD who had a cerebrovascular event (CVE) a month before the onset of the obsessive and compulsive symptoms. A 67 year-old female, who did not have any psychiatric complaints before, applied to the emergency service with anxiety, multiple suicide attempts, religious intrusive thoughts and she had compulsive behaviors as avoiding religious routines and repeat other's speeches which she had heard for the last 2 months. In medical history, it has been

### KEYWORDS

Obsessive-compulsive disorder; cerebrovascular event; late-onset



understood that she had right internal carotid artery aneurysm 3 months ago. And a stent was placed to her aforementioned artery as treatment. After hospitalization, there wasn't any reported pathology at cranial magnetic resonance imaging (MRI) and routine blood tests. In her examination she described hypnopompic visual hallucinations without any psychotic symptoms and intrusive religious thoughts. Alprazolam and sertraline were given for her obsessive-compulsive symptoms which presenting with anxiety. These symptoms were partially improved in the fourth week of the treatment. Although there is no objective sign on MRI imaging, late onset suggests that the cause of OCD should have been related with an organic pathology due to CVE. In literature, it is reported that late onset OCD especially after 50 years of age is generally related with organic etiopathogenesis. It is aimed to draw attention to the possible association between late onset OCD and organic etiology. It may be useful to investigate organic etiopathogenesis in late-onset OCD cases.

Abstract:0443

## Complex Childhood Trauma History in a Patient with Obsessive-Compulsive Disorder and Trichotillomania: A Case Report

Ilgaz Kınalı and Münevver Yıldırım Hacıoğlu

Bakırköy Research and Training Hospital for Psychiatry, Neurology and Neurosurgery, Istanbul, Turkey

E-mail address: [ilgazkinali@hotmail.com](mailto:ilgazkinali@hotmail.com)

### ABSTRACT

Child sexual abuse is an important subset of all sexual abuse and encompasses all the behaviors that adults do by fooling, convincing, tempting, enforcing, or enforcing the child's sexual satisfaction. The physical, emotional or sexual abuse that an individual is exposed to during his childhood affects his or her future experience and behavior. Compared to non-abusive individuals, abused individuals experience many psychopathological and physical problems. The reason for this is that traumatic events affect the functioning of the body, resulting in more vulnerable and vulnerable to the threats of the body and subsequent stress stimuli. Studies have shown that childhood trauma can have an important role in both neurotic excoriation and accompanying psychiatric problems. Emotional abuse and incest have been shown to be associated with markedly higher ovarian involvement with sexual obsessions. A 22 year-old woman was admitted to the hospital with the complaints of obsessions mainly in sexual and religious settings and decrease in performance. In physical examination alopecia was observed mainly at the occipital region and trichotillomania was identified. After the medical treatment except the sexual obsessions other obsessive-compulsive disorders were decreased and patient's performance was increased. There is a childhood complex trauma in the patient's history. After we find out about the childhood trauma due to the sexual abuse of the father her treatment started. We related her sexual obsessions with the abuse that she had experienced. In this case we wanted to show that there is a possibility to change the complex traumas which was started in the childhood who present patients with OCD and trichotillomania can be treated. We wanted to show the treatment process and how the resistance could be altered.

### KEYWORDS

Childhood sexual trauma; obsessive-compulsive disorder; trichotillomania

Abstract:0012

## Mianserin-Induced Periorbital Edema: A Case Report

İbrahim Gündoğmuş, Mustafa İspir, Ayhan Algül and Servet Ebrinç

Department of Psychiatry, Haydarpaşa Sultan Abdulhamid Training and Research Hospital, Istanbul, Turkey

E-mail address: [dribrahim06@gmail.com](mailto:dribrahim06@gmail.com)

### ABSTRACT

Mianserin, a tetracyclic and atypical antidepressant, has an antagonistic effect on 5-HT<sub>2A/C</sub>, 5-HT<sub>3</sub>, H<sub>1</sub>, α<sub>1</sub> and α<sub>2</sub>-adrenergic receptors. It is commonly used for the management of depression and anxiety disorders especially the patients or healthy groups which have the impaired sleep quality. Mianserin is generally a safe and well-tolerated medication choice compared with the other antidepressant groups. The adverse effect of mianserin that dizziness, blurred vision, constipation, sedation, somnolence, increased appetite, weight gain and bradycardia, is relatively demonstrated rare. Periorbital edema is defined an acute

### KEYWORDS

Mianserin; periorbital edema; side effect



vascular reaction on dermis and subcutaneous tissue in the periorbital area. This localized edema which seen rarely, is caused by increased dilatation and permeability of the capillaries because of extravasation of serous fluid. Periorbital edema is rare and non-specific symptom and there is limited reference in the literature. The exact mechanism of mianserin related with periorbital edema is unknown and remains unclear. The formation mechanism of edema was described with immune-mediated processes and autoimmune mechanism. Mianserin has a wide action on the different receptors as described above. Generally, antihistaminergic effect of drugs are used for preventing the great deal of allergic reactions. Despite the antihistaminergic receptor activation of mianserin, some kind of allergic reaction might be emerge. This condition shows that different mechanisms can be effective on occurring the periorbital edema. In our case, we discussed a patient with periorbital edema associated with mianserin treatment and possible formation mechanism of this rare side effect and as far as we know, this is the first case that demonstrated the periorbital edema related with mianserin in the literature.

Abstract:0028

## Three Cases with Hypomania Occurred with Use of Sertraline

Hatice Doğan

Giresun State Hospital, Giresun, Turkey

E-mail address: [haticebozdogan2007@gmail.com](mailto:haticebozdogan2007@gmail.com)

### ABSTRACT

Hypomania is a state of behavioral arousal. It is a mood state in which an individual express increased psychological and physical activity but not at a level as high in mania. Decreased need for sleep, pressured speech, and acceleration in thinking, flight of ideas, easily distracted attention and increased goal-directed activity can be observed in hypomania.

Case 1: Sertraline (50 mg/day) was prescribed to a 14 year-old girl presented with irritability, dissatisfaction, and dispiritedness. The drug was gradually withdrawn as the patient reported increased speech, laugh and joy following a month of drug use.

Case 2: The patient was a 12 year-old girl when she presented to our outpatient clinic. She was one of triplets. Unlike two siblings with autism and mental retardation, she had a healthy appearance; however, she was presented with inability to experience pleasure from life, involving into struggle without a reason, insisting to achieve her wishes, continuous irritability and nervousness by parents. She was prescribed sertraline (50 mg/day); however, the drug was gradually withdrawn 2 weeks after prescription due to onset of excessive talking, laughing, buying and attempting to dangerous activities.

Case 3: A 10 year-old girl was prescribed sertraline (25 mg/day) for complaints of distress, boredom and peer jealousy in another facility. The patient, who was stable initially, was referred to our outpatient clinic with inappropriate and excessive laughing, talking during lesson without any reason and sudden outbursts by her teacher. The drug was gradually withdrawn due to hypomania.

Hypomania/mania associated to selective serotonin reuptake inhibitors have been reported in many studies. Likelihood of hypomania with sertraline is reported to be 0.5%. This figure can be decreased by meticulous patient selection and exclusion of patients with previous history of mania/hypomania and those with affective disorder in first degree relatives.

### KEYWORDS

Sertraline; hypomania; SSRI

Abstract:0029

## Separation Anxiety Disorder Manifested with Diffuse Urticaria

Hatice Doğan

Giresun State Hospital, Giresun, Turkey

E-mail address: [haticebozdogan2007@gmail.com](mailto:haticebozdogan2007@gmail.com)

### ABSTRACT

Separation anxiety disorder can be defined as experiencing anxiety more than anticipated according to developmental stage or repeated anxiety over at least 4 weeks regarding separation from home or from individual to whom he/she has attachment. It is seen that the child experiences excessive and continuous anxiety about he/she will lose individuals to whom

### KEYWORDS

Urticaria; separation; anxiety

he/she has strong attachment and that he/she is unwillingness to school or anywhere else due to separation anxiety. In separation anxiety disorder, the child experiences difficulties in major functionality domains (relations in school, peer relations or social life) for his/herself. Acute urticaria is the most common skin disorder leading emergency visits at childhood. In the literature, association between psychiatric factors and chronic urticaria has been investigated in general and it was reported that 70% of patients with chronic urticaria has predisposition to anxiety, depression and psychosomatic symptoms. In our case, we will discuss urticaria triggered by separation anxiety. The patient was a 6-years old child attending to grade 1 in primary school. The patient was referred to our outpatient clinic due to recurrent acute urticaria episodes requiring emergency department visits. The complaints of the patients began after starting preschool education. Parents reported that the patient experienced difficulty to separate from mother; thus, the patient left preschool education. However, the complaints recurred by beginning grade 1 in elementary school. The patient was prescribed fluoxetine (10 mg/day) and dramatic improvement with recovery of urticaria was observed in the patient. As in all anxiety disorders, somatic symptom can accompany to separation anxiety. Somatic symptoms may include abdominal pain, headache, nausea and vomiting as well as skin lesions. In our case, finding that skin lesions were associated to anxiety and regressed by treatment of anxiety disorders suggests that such cases should be evaluated more comprehensively.

Abstract:0049

## Hyponatremia Associated with Citalopram

Sevda Bağ, Merve Çukurova, Ömer Akay and Çağatay Karşıdağ

Department of Psychiatry, Bakırköy Prof. Dr. Mazhar Osman Mental Health and Neurological Diseases Training and Research Hospital, Istanbul, Turkey

E-mail address: [sevdabag@yahoo.com](mailto:sevdabag@yahoo.com)

### ABSTRACT

Hyponatremia is the most common electrolyte disorder and occurs in 1% of hospitalized patients (1). A 57-year-old male patient was admitted to the hospital with anxiety and depression symptoms citalopram 40 mg / day was recommended. Patient has used for one year. He had the sudden onset of headache, anorexia nausea and vomiting sleepiness and then he applied to emergency and hospitalized to internal medicine hospital. In patients with hyponatremia (Na: 107 mmol/L and Cl:78 mail/L) has been detected. Patients without a history of hypertension were treated with 3% NaCl infusion and daily blood Na values were checked. after another reason could not be determined, It was thought that the cause of low sodium was connected to the SSRI. Drug side effects should be considered when unexplained complaints develop in patients within the first few weeks after the initiation of SSRI drug treatment.

### KEYWORDS

Hyponatremia; SSRI; SNRI

## Reference

- [1] Corrington KA, Gatlin CC, Fields KB. A case of SSRI-induced hyponatremia. JABFP 2002;15:63–5

Abstract:0060

## A Case of Olanzapine-Induced Tardive Dyskinesia with Dramatic Evolution in a Week

İbrahim Gündoğmuş, Osman Bakkal, Ayhan Algül and Servet Ebrinç

Department of Psychiatry, Haydarpasa Sultan Abdulhamid Training and Research Hospital, Istanbul, Turkey

E-mail address: [dribrahim06@gmail.com](mailto:dribrahim06@gmail.com)

### ABSTRACT

Tardive dyskinesia is a serious and persistent complication of treatment with antipsychotic agents. It is characterized by involuntary movements, consisting of abnormal, involuntary, irregular choreoathetoid movements of muscles over not only the face and the oral region but also the limbs, the trunk, and the respiratory muscles. This situation predominantly include dystonia, chorea, tics, myoclonus, and stereotypic movements. Olanzapine, a

### KEYWORDS

Olanzapine; side effect; tardive dyskinesia; dramatic evolution

dopaminergic and serotonergic receptor antagonist, is an atypical antipsychotic with efficacy in schizophrenia slightly higher than others. Olanzapine, which is commonly used, are reported several side effects such as weight gain, insulin resistance, including over sedation, extrapyramidal side effects, myocarditis, prolonged QTc interval, toxic megacolon and agranulocytosis. A 32 year-old married military man with a 3-year history of chronic schizophrenia accompanied by paranoid symptoms. He was initiated olanzapine 10 mg/day and titrated up to 30 mg/day in the following 1 month. In September 2016, while the patient was on olanzapine (30 mg/day) and biperiden (4 mg/day), he developed perioral, lingual and jaw movements of moderate severity. He was hospitalized and olanzapine was tapered off and clozapine (25 mg/day initiated and titrated up 200 mg/day) were administered. One weeks later, there was marked improvement of his involuntary movements and it clearly stopped. Two weeks later, there was no evidence of neurological symptomatology. There are a lot case reports indicating that olanzapine treatment is associated with tardive dyskinesia but in our case tardive dyskinesia ameliorated in one week. Although olanzapine has been claimed to carry a low risk for tardive dyskinesia and other extrapyramidal symptoms, in this case tardive dyskinesia was most likely a result of olanzapine treatment. Early detection of extrapyramidal side effects, in particular tardive dyskinesia, is critical to its management and clinicians should remain vigilant regardless of the type of antipsychotic prescribed.

Abstract:0074

## Olanzapine-Induced Hyponatremia: A Case Report

Çağlar Soykan, Serdar Süleyman Can, Ali Çayköylü and Ayşegül Taşdelen Kul

Department of Psychiatry, Yıldırım Beyazıt University, Ankara, Turkey

E-mail address: [aysegul.tsdl04@hotmail.com](mailto:aysegul.tsdl04@hotmail.com)

### ABSTRACT

Psychotropic drugs have clinically important adverse effects such as hyponatremia. Psychogenic polydipsia occurs in 6% to 20% of psychiatric patients and it is more commonly seen in schizophrenia. We report a case presenting with life threatening severe hyponatremia secondary to olanzapine treatment. A 61 year-old, male diagnosed with schizophrenia for 40 years presented to our outpatient psychiatry clinic in a confusional state. He had a history of generalized muscle aches, lethargy, confusion, irritability, headache, weakness for a week before admission to hospital. CT angiography and magnetic resonance imaging of the brain had shown no abnormalities. Laboratory investigations revealed hyponatremia with sodium value of 108 mmol/L. He was on olanzapine 5 mg and risperidone 2 mg daily for last eight years. He had not used any other medication known to cause hyponatremia. Psychiatric history revealed that he had excessive water intake. He received treatment with hypertonic saline. At discharge his sodium levels were normalized, he had clear consciousness. The patient was recommended to continue treatment with risperidone 2 mg/day, water intake of 1.5 L per day and sodium intake of 4 g. Despite the psychiatrist's recommendation to discontinue olanzapine treatment the patient take 5 mg of olanzapine for 5 days. One week after the discharge the patient was presented to our emergency service with the symptoms of weakness, lethargy, nausea and vomiting. Laboratory data revealed serum sodium level of 111 mmol/L. He received hypertonic saline treatment and his serum sodium levels normalized again. He was discharged on risperidone 2 mg with discontinuation of olanzapine treatment there was no hyponatremia and or signs of water intoxication during 2 months follow up. Olanzapine was incriminated as the causative agent of hyponatremia. In conclusion, clinicians should be aware that patients being treated with olanzapine have a risk of hyponatremia.

### KEYWORDS

Hyponatremia; olanzapine; sodium

Abstract:0079

## Duloxetine-Induced Manic Switch: A Case Report

Abdulkadir Karagöz, İbrahim Gündoğmuş, Hakan Kullakçı, Özgür Maden, Ayhan Algül and Servet Ebrinç

Department of Psychiatry, Haydarpaşa Sultan Abdulhamid Training and Research Hospital, Istanbul, Turkey

E-mail address: [karagozabdulkadir@gmail.com](mailto:karagozabdulkadir@gmail.com)

**ABSTRACT**

We report a case of duloxetine-induced manic episodes in a patient with major depressive disorder. A 33 year-old women presented to our clinic showing depressive symptoms. She had no history of a previous psychiatric but according to her husband she had depressive mood all time. After a psychiatric and medical evaluation, according to DSM-5 she was diagnosed with major depressive disorder. She was prescribed duloxetine 30 mg/day and titrated up 60 mg/day in two week. She had no any complaint in control examination six month later. Stopping duloxetine is recommended but the patient chose to continue by herself. While still on duloxetine, admission was necessary because the patient experienced a manic syndrome three months later. At this time she had begun to engage in excessive cleaning, abundant confidence, pressure of speech, episodic irritability, excessive speech, reckless money spending, insomnia, overactivity, physical and verbal aggression and distractibility. Her Young's mania rating scale score was 24 (total score = 60; generally considered cut-off of acute mania = 12). A diagnosis of duloxetine-induced mania was made. She was commenced on lithium 600 mg/day and olanzapine 15 mg/day nocte with gradual improvement in her symptoms over the following two weeks. At the time of follow-up examination 1 month later, he was free of manic symptoms. Reports of duloxetine-induced hypomania or mania involved mostly depressive cases. At the same time, in some cases there was a history of bipolar disorder in the family. Such that, it can be thought that the patient may have been a natural switch as seen in bipolar disorder. For that reason, it may be possible that the duloxetine-induced mania or hypomania in depressed patients is not a genuine adverse-effect.

**KEYWORDS**

Duloxetine; side effects; manic switch

Abstract:0081

## Aripiprazole and Paroxetine-Induced Hyponatremia

Serdar Süleyman Can, Yasin Duman, Murat İlhan Atagün, Ayşegül Taşdelen Kul and Ali Çayköylü

Department of Psychiatry, Yildirim Beyazıt University, Ankara, Turkey

E-mail address: [aysegul.tsdln04@hotmail.com](mailto:aysegul.tsdln04@hotmail.com)

**ABSTRACT**

Hyponatremia is defined as a serum sodium concentration of <135 meq/L. Many different diseases and psychiatric drugs (such as selective serotonin reuptake inhibitors, serotonin and noradrenalin reuptake inhibitors, and second generation antipsychotics) can cause this clinic situation. Here, we present a 46 year-old female patient who has been followed-up for 9 years with major depressive disorder. After seven days of paroxetine 10 mg/day treatment, the patient presented to the emergency room with complaints of nausea, dizziness, confusion and contraction. The patient's blood sodium value was 121 meq/L. The cause of hyponatremia in the patient's detailed examination and laboratory tests was not determined. Hyponatremia was treated with hypertonic solution. The patient started treatment with tianeptine 37.5 mg/day mirtazapine 30 mg/day and depressive symptoms improved. After 1 year, aripiprazole 2.5 mg/day was added to the treatment for increased depressive symptoms after the psychosocial stressor. After three days, the patient presented with complaints of headache, nausea, contractions and admitted to emergency service. The blood sodium level of the patient was determined to be 127 meq/L and treated with hypertonic solution. After the patient's aripiprazole treatment was discontinued, the blood sodium level returned to normal. Hyponatremia could not be detected in laboratory tests during follow up. In conclusion, it should bear in mind that antidepressant and antipsychotic drugs used in the treatment of major depressive disorder may cause significant side effects such as hyponatremia. It has also been observed that different group medicines cause similar conditions in different periods in our patient. The life-threatening side effects of psychotropic medications should be considered by psychiatrists.

**KEYWORDS**

Aripiprazole; hyponatremia; paroxetine

Abstract:0088

## Improvement of Haloperidol Decanoate-Induced Hyperprolactinemia with Aripiprazole in a Patient with Schizophrenia

Yusuf Çokünlü, Memduha Aydın, Tuba Şerife Elmas and İbrahim Eren

Department of Psychiatry, Konya Training and Research Hospital, Konya, Turkey

E-mail address: [dr.bendirzen@hotmail.com](mailto:dr.bendirzen@hotmail.com)

**ABSTRACT**

Hyperprolactinemia is a frequent consequence of antipsychotic medication. Recent studies and clinical trials have suggested that the antipsychotic aripiprazole, a partial dopamine D2 receptor agonist, can lower prolactin concentrations and potentially reduce prolactin-related effects when given with antipsychotics. We describe a patient who developed hyperprolactinemia while taking haloperidol decanoate treatment which improved on the introduction of aripiprazole. A 45-year-old female was diagnosed with schizophrenia for 22 years and received haloperidol decanoate 200 mg every 4 weeks for 4 years. On admission to hospital, her prolactin level was found to be high (237.0 ng/mL, normal range 4.79-23.3 ng/mL). She also suffered from hypothyroidism. She was consulted to endocrinology department due to hyperprolactinemia and TSH level as 7.84 mIU/L (normal range 0.57-5.6 mIU/L). After the brain magnetic resonance imaging, she was diagnosed as asymptomatic (lack of secondary adrenal insufficiency and growth hormone deficiency with preservation of gonadotrophic function and lack of galactorrhea - amenorrhea) partial empty sella. Thyroid hormone replacement was started. On a stable dose of thyroid hormone additional prolactin levels were drawn 3 and 4 weeks after starting thyroid hormone and were 189.73 and 193.58 ng/mL, respectively. Hyperprolactinemia of the patient did not improve sufficiently in this period. Next, aripiprazole 5 mg/ day treatment was added to haloperidol decanoate due to hyperprolactinemia. Fourteen days after the beginning of aripiprazole (5 mg/day), the prolactin level firstly decreased to 97.66 ng/mL and after 3 weeks decreased to 53.92 ng/mL. The case we presented in this report suggests that adjunctive treatment with aripiprazole reduces the prolactin concentration that had been increased because of haloperidol decanoate treatment. Adjunctive aripiprazole therapy was generally well tolerated. We experienced any serious adverse effects during the aripiprazole combination treatment in the reported case.

**KEYWORDS**

Aripiprazole; haloperidol decanoate; hyperprolactinemia

Abstract:0089

## Persistent Drug-Induced Parkinsonism After Discontinuation of Paliperidone Palmitate: A Case Report

Ali Baran Tanrikulu, Memduha Aydın, Tuba Şerife Elmas, Deniz Altunova and İbrahim Eren

Department of Psychiatry, Konya Training and Research Hospital, Konya, Turkey

E-mail address: [barantanrikulu9@gmail.com](mailto:barantanrikulu9@gmail.com)

**ABSTRACT**

Drug-induced parkinsonism (DIP) is the second common cause of parkinsonism. Discontinuation of the neuroleptic agent in DIP should relieve the symptoms of parkinsonism. However, differentiating DIP from Parkinson's disease (PD) may be a challenge to clinicians. Timeframe between the neuroleptic withdrawal and resolution of the symptoms of parkinsonism may prolong up to 6–12 months as written in literature. We aimed to present a persistent DIP with PP treatment. A 47-year-old woman with a history of delusional disorder for 2 years was referred to inpatient clinic. She was started on paliperidone palmitate (PP) 150 mg/1,5 ml loading dose and then 100 mg/1,5 ml maintenance dose per month in her first hospital admission. She was discharged from hospital with 100 mg/1,5 ml PP per month. After 6 months PP dosage was reduced 75 mg/1,5 ml per month. After second dose of 75 mg PP she presented to hospital with parkinsonism. PP was ceased and feniramin maleat, diazepam and biperiden treatment was administered intravenously a few times per day. Although one week administration of antiparkinsonian treatment parkinsonism resisted. She had no psychotic symptoms when admitted to hospital with parkinsonism. She was discharged from the hospital and after 4 months she was admitted to hospital with psychotic flare up. Her symptoms of parkinsonism was still existing. She was started on clozapine and the dose was brought to 300 mg daily. Neurology did not evaluate patient as Parkinson disease. Her parkinsonism symptoms fairly alleviated in the first month of clozapine treatment. In conclusion, case presented highlights the slow recovery from DIP, especially in patients having depot antipsychotics. Parkinsonism may persist up to 18 weeks after cessation of responsible drugs. In our case paliperidone palmitate was ceased after severe parkinsonism symptoms. After cessation of drugs parkinsonism signs completely revealed after 24 weeks.

**KEYWORDS**

Clozapine; drug-induced parkinsonism; paliperidone palmitate

Abstract:0099

## Aripiprazole-Induced Hallucination: A Case Report

Hande Ayraller Taner and Burcu Akin Sari

Department of Child and Adolescent Psychiatry, Başkent University School of Medicine, Ankara, Turkey

E-mail address: [carpediemburcu@yahoo.com](mailto:carpediemburcu@yahoo.com)

### ABSTRACT

Aripiprazole is an antipsychotic agent with partial agonist dopaminergic effect. The drug used for the treatment of schizophrenia, conduct disorder or augmentation for treatment has also been developed specifically for the resolution of side effects of atypical antipsychotics. Although aripiprazole is used for the treatment of schizophrenia, its partial agonist effect may cause some undesirable side effects. In this case such side effects have been observed and discussed. A 16-year-old male patient presented to the clinic with complaints of not getting used to new school, intense anxiety, head and stomach pain, repetition and cleansing compulsions, feelings of uneasiness and unhappiness. In the mental condition examination; he has repetition and cleansing compulsions. There was no perception disorder. In blood tests; fasting blood sugar, thyroid functions, vitamin B12 level, hemoglobin, folic acid liver and kidney function were normal. Considering the obsessive-compulsive disorder in the patient, sertraline 50 mg was recommended. Dosage was increased to the 75 mg as the obsessions did not pass. During follow up the medication was adjusted to 100 mg for the patient since the obsessions decreased but anxiety symptoms were added. Following a 40% reduction in obsessions, aripiprazole 5 mg was added for augmentation. On the 2nd day of aripiprazole, this medication was reduced to 1.25 mg due to the patient's visual hallucination. At this dose, the patient's aripiprazole was withdrawn, since the patient described insomnia, nightmares and visual hallucinations. The resulting hallucinogenic side effect is thought to be due to the sertraline interaction or partial dopaminergic effect.

### KEYWORDS

Aripiprazole; hallucination; side effect

Abstract:0101

## Wolf-Parkinson-White Syndrome Due to Risperidone Treatment in a Patient with Schizophrenia

Tuba Şerife Elmas, Saliha Çalışır, Memduha Aydın, Dudu Demiröz, Ali Baran Tanrikulu and İbrahim Eren

Department of Psychiatry, Konya Training and Research Hospital, Konya, Turkey

E-mail address: [tubaserife@gmail.com](mailto:tubaserife@gmail.com)

### ABSTRACT

Wolf-Parkinson-White (WPW) syndrome is a congenital heart disease, an extra electrical pathway between the atria and the ventricles that causes a rapid heartbeat, a reentrant tachycardia circuit. Risperidone is an atypical antipsychotic and its cardiac effects are orthostatic hypotension, QT prolongation, arrhythmias and sudden cardiac death. We present the case of a patient with schizophrenia and WPW syndrome who was treated with risperidone. A 30 year-old woman was admitted to psychiatry inpatient clinic with complaining of aggression, irritability, psychomotor excitement, suspicion, susceptibility, auditory hallucinations, exacerbation of paranoid and persecutory delusions, reduced sleep, decreased appetite, suicide attempts for 5-6 months. No pathology was found in routine laboratory results. Treatment was ordered as an oral risperidone 3 mg/day, lorazepam 3 mg/day, due to poor compliance with medication long acting injectable risperidone 37.5 mg. Before the start of treatment, ECG was in sinus rhythm, the QTc interval was 458 ms, heart rate (HR): 65 bpm. One week later, QTc: 469 ms, HR:106 bpm. A second injection of risperidone was administered, QTc: 473 ms HR: 72 bpm. A third injection of risperidone, QTc interval was 472 ms, HR: 64 bpm during sinus rhythm. Her psychotic symptoms improved and no side effects worsening arrhythmia was observed. Schizophrenic patients have a shorter life expectancy than many other psychiatric patients and the healthy population. Some antipsychotic drugs may prolong the QTc interval, and whether this may result in torsades de pointes and sudden death. In WPW, wide QRS tachycardias can be caused by multiple mechanisms: sinus or atrial tachycardias, AV nodal reentry, and atrial flutter or fibrillation with anterograde conduction over the accessory pathway; but are not related to prolong the QTc interval and torsades de pointes. Regular ECG and heart rate follow-up are sufficient when treating WPW patients with atypical antipsychotics that the lowest arrhythmogenic side effect should be selected.

### KEYWORDS

Risperidone; schizophrenia; Wolf-Parkinson-White syndrome



Abstract:0102

## Fluoxetine-Induced Hyperprolactinemia and Galactorrhea

Hakan Kullakçı, Mustafa İspir, Ayhan Algül and Servet Ebrinç

Department of Psychiatry, Haydarpasa Sultan Abdulhamid Training and Research Hospital, Istanbul, Turkey

E-mail address: [sismetein@hotmail.com](mailto:sismetein@hotmail.com)

### ABSTRACT

Fluoxetine is an often prescribed selective serotonin reuptake inhibitor. It is certified as a first resort drug by US Food and Drug Administration for use in major depressive disorder, panic disorder, bulimia nervosa, premenstrual dysphoric disorder and in obsessive-compulsive disorder. The most common side effects include headache, nausea, insomnia, anxiety and nervousness. On the other hand with few major side-effects; changed serotonergic transmissions in hypothalamic pathways might lead to a distressing, and often embarrassing, manifestation of hyperprolactinemia. Hyperprolactinemia is characterized as an elevated level of serum prolactin, in the lack of such conditions as pregnancy or lactation, and is induced by an rise in prolactin secretion from the pituitary gland. It is a common endocrine disorder, with a prevalence of 1–1.5%, and may be caused by a number of pathological and pharmacological conditions. Selective serotonin reuptake inhibitors (SSRIs) commonly cause hyperprolactinemia owing to presynaptic mechanisms indirectly via 5-hydroxytryptamine (5-HT)-mediated inhibition of tuberoinfundibular dopaminergic neurons. However, there is not much insight about the mechanisms by which fluoxetine causes hyperprolactinemia via the postsynaptic pathway. In literature, some studies and case reports describing galactorrhea with SSRIs have reported various degrees of changing in prolactin levels. Prolactin is secreted by the anterior pituitary under hypothalamic calibration through a mixed series of connections. In past individual case reports could be indicate a mighty association of SSRIs with prolactin abnormalities. We report here a young women with major depressive disorder of fluoxetine-induced hyperprolactinemic galactorrhea developing treatment on a stable regimen.

### KEYWORDS

Fluoxetine;  
hyperprolactinemia;  
galactorrhea

Abstract:0106

## Vortioxetine And Generalized Acute Urticaria: A Case Report

Mustafa İspir, İbrahim Gündoğmuş, Özgür Maden, Ayhan Algül and Servet Ebrinç

Department of Psychiatry, Haydarpasa Sultan Abdulhamid Training and Research Hospital, Istanbul, Turkey

E-mail address: [mispirkadirli@gmail.com](mailto:mispirkadirli@gmail.com)

### ABSTRACT

Vortioxetine is an antidepressant drug that is certified in the US for the treatment of adults with major depressive disorder (MDD). Its mechanism of action is concerned to its multimodal activity, which combines two pharmacological properties. A multi-modal antidepressant that functions both as serotonin transporter (SERT) inhibitor and as 5-HT<sub>3</sub>, 5-HT<sub>7</sub> and 5-HT<sub>1D</sub> receptors antagonist, 5-HT<sub>1A</sub> receptor agonist and 5-HT<sub>1B</sub> receptor partial agonist. However, we don't know from the how vortioxetine's multimodal mechanism of action contributes to its antidepressant effect. The efficacy and tolerability of vortioxetine in comparison with other antidepressants is not clear. On the other hand, in some studies designed to specify cognition in depression, vortioxetine showed evidence of improving cognitive performance in patients with acute major depressive disorder. According to last studies, vortioxetine appears well-tolerated, with very limited effects on weight gain and sexual functioning. The most commonly side effect (nausea) was generally transitory. We report the case of a female patient with a generalized urticaria because of hypersensitivity to vortioxetine. There were several case reports about generalized urticaria of antidepressants in the literature. But as far as we know, our case is the first showing the possible adverse effect with vortioxetine. Specifically, vortioxetine may have important clinical advantages by virtue of its cognition-increase effects. Clinicians should be careful when prescribe of this drug, because experience with side effects is limited. Although dermatological reactions such as urticaria is seen secondary to antidepressant drug use, rarely life-threatening dermatological disorders may also be seen. Urticarial lesions alone were present in the in our case here and no life-threatening clinical picture such as angioedema accompanied the lesions. Lesions regressed after the cessation of the drug.

### KEYWORDS

Vortioxetine; urticaria; side effect

Abstract:0112

## Risperidone-Induced Bruise-Like Rash in a Child

Özalp Ekinçi, Muhammet Emin Tan and Merve Kalınli

Department of Child and Adolescent Psychiatry, Mersin University School of Medicine, Mersin, Turkey

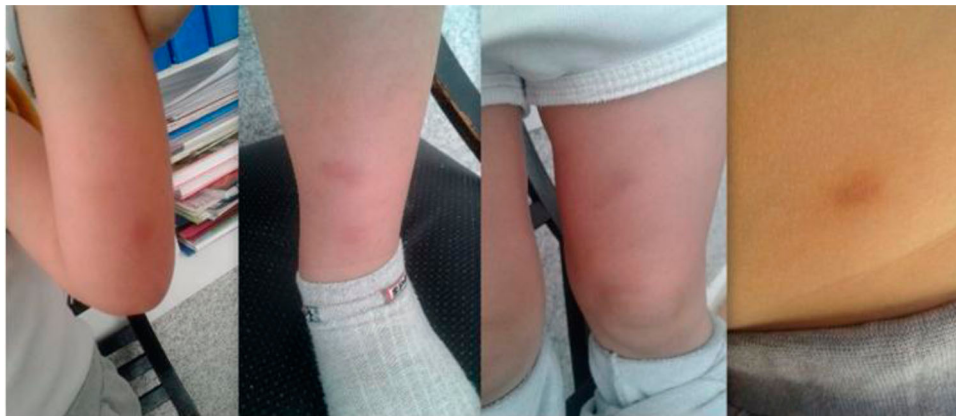E-mail address: [ozalpekinchi@yahoo.com](mailto:ozalpekinchi@yahoo.com)

### ABSTRACT

**OBJECTS:** Atypical antipsychotics have been rarely linked to adverse skin reactions. There is a limited literature on risperidone-induced skin reactions in children. Hereby, we report bruise-like rash in a 4-year-old boy with risperidone use which warrants discontinuation. A 4-year-old boy was admitted with complaints of impulsivity, difficulty following rules and aggressive behaviors at school. He had a borderline developmental delay and all his medical and neurological workup were in normal range. His body weight was 17 kg. Risperidone oral solution was started on the dose of 0.125 mg/day for the first week and was gradually increased to 0.5 mg/day bid. Three days after the dose increase, patient has developed bruise-like lesions on his chest, arms and legs (Figure 1). The inspection and palpation of the skin lesions revealed multiple asymmetrically distributed macules which were not painful. There was no history suggestive of recent physical injury, fever, infection symptoms or intake of any other medications. The patient was firstly consulted to the dermatology department and no dermatologic disease was diagnosed. His blood tests, including bleeding tests, were in normal range. In the differential diagnosis, physical abuse was also ruled out. With the suspect of a risperidone-induced skin reaction, risperidone was discontinued. Bruise-like skin lesions gradually disappeared within 2 weeks. Figure 1 shows the bruise-like rash on different parts of the body. The mechanism through which risperidone causes skin reactions is largely unknown. Proposing a possible immunological etiology, it has been suggested that antipsychotics can alter the cytokine system in the body. In the present case, the adverse reaction appeared after a dose increase which indicates a dose-dependent phenomenon. Clinicians should be aware of bruise-like skin rash as a rare adverse effect of risperidone. This is especially important for child cases where physical abuse is suspected.

### KEYWORDS

Risperidone; antipsychotic; rash; child



**Figure 1.** Bruise-like rash on different parts of the body.

Abstract:0120

## Olanzapine-Induced Facial Edema: A Case Report

Murat Kıyancıcek, İbrahim Gündoğmuş, Özgür Maden and Ayhan Algül

Department of Psychiatry, Haydarpasa Sultan Abdulhamid Training and Research Hospital, Istanbul, Turkey

E-mail address: [mkiyancicek@hotmail.com](mailto:mkiyancicek@hotmail.com)

**ABSTRACT**

Olanzapine is an atypical antipsychotic which is widely used for the treatment of schizophrenia and bipolar disorders effectively and reliably. Olanzapine is also used to increase the efficiency of the treatment for various psychiatric disorders. Olanzapine's mechanism of action involves antagonism at serotonergic, dopaminergic receptors. It was reported that weight gaining, postural hypotension, constipation, dizziness, akathisia and sedation are the most frequently observed adverse effects due to olanzapine usage. One of the slightly-observed side effects of olanzapine is edema. Local edema is reported as a rare-side effect in 3% of the patients treated with olanzapine. Although there are many factors in the etiology of local edema, intake of food and medicine stand out among these factors. Although medicine-induced edema is often developed particularly depending on calcium channel blocker, beta blockers, non-steroid anti-inflammatory medicine and some hormone medicine, it is rarely developed with the new type antipsychotics. The patient's developing facial edema when olanzapine added on his paroxetine treatment and the edema's going away when olanzapine was stopped led us think that the reason of the facial edema was the side effect of olanzapine. Looking into the literature, we have seen 3 olanzapine-induced facial edema cases, however the case of facial edema when olanzapine added on paroxetine treatment is the first in the literature. A peripheral edema may be observed as the side effect of olanzapine which is among atypical antipsychotics. The etiology and development mechanism of the facial edema hasn't been clear. Patients get scared of the look of the facial edema, which interrupts the treatment harmony of the patient. Here, a case that olanzapine-induced facial edema was discussed. Future research is needed to clarify the mechanism, dose dependence and risk factors for olanzapine-induced facial edema.

**KEYWORDS**

Adverse effect; facial edema; olanzapine

Abstract:0134

## Pulmonary Thromboembolism Associated with Quetiapine: A Case Report

Hasret Karabulut Gül, Demet Sağlam Aykut, Emel Uysal and Filiz Civil Arslan

Department of Psychiatry, School of Medicine, Karadeniz Technical University, Trabzon, Turkey

E-mail address: [drhasretkgul@hotmail.com](mailto:drhasretkgul@hotmail.com)

**ABSTRACT**

Little attention has been focused on the antipsychotics potentially fatal adverse drug reaction of venous thromboembolism (VTE), which includes pulmonary embolism and deep-vein thrombosis. Association between antipsychotics and VTE has been strengthened as a result of the published studies and case reports. In this case report, pulmonary thromboembolism was thought to be associated with the use of quetiapine and it was planned to draw attention to this side effect. A 36-year-old man presented to the Emergency Department (ED) complaining of general weakness, mild fever, and dizziness. There was no chest pain, leg edema or swelling, orthopnea, PND, or sweats. The patient has a history of Bipolar disorder and taking 1200 mg/day Lithium. The psychiatrist added Quetiapine 200 mg/day a week before the recourse to ED. The vital signs recorded heart rate 132 beats/min, body temperature 37.9°C and oxygen saturation in room air was 70%. D-dimer was 1773 µg/L. The helical chest CT scan revealed; bilateral superior and inferior lobar branches trunk thrombosis. There were no risk factors such as age, smoking, trauma, immobility, surgery, heart disease and genetic risk factors such as protein C, S and antitrombin III deficiency, dysfibrinogenemia, Factor V Leiden thrombophilia, PT20210 and MTHFR gene mutation, lupus anticoagulant and Homocysteine level was normal. There was no family history of hypercoagulable state. The biological mechanism explaining the relation between antipsychotic drugs and venous thromboembolism is unknown. Several hypotheses have been proposed: antipsychotic drugs enhance aggregation of platelets or increase anticardiolipin antibodies, and venous stasis is exacerbated by sedation. In this case report, pulmonary thromboembolism seen in the patient was associated with the use of quetiapine. We should be more careful about this fatal side effect; pulmonary thromboembolism.

**KEYWORDS**

Bipolar disorder; pulmonary thromboembolism; quetiapine

Abstract:0139

## Urinary Retention After Alprazolam Use: A Case Report

Emel Uysal, Demet Sağlam Aykut, Hasret Karabulut Gül and Evrim Özkorumak Karagüzel

Department of Psychiatry, Karadeniz Technical University, Trabzon, Turkey

E-mail address: [dremelkorkmaz@gmail.com](mailto:dremelkorkmaz@gmail.com)

**ABSTRACT**

Urinary retention is a condition in which impaired emptying of the bladder results in postvoidal residual urine. Data from observational studies suggest that up to 10% of episodes might be attributable to the use of concomitant medication. Urinary retention has been described with the use of drugs with anticholinergic activity, opioids and anesthetics, alpha-adrenoceptor agonists, benzodiazepines, NSAIDs. In this article, a case of urinary retention developed after the use of alprazolam was discussed. A 67-year-old male patient. The patient who underwent prostatectomy operation due to benign prostatic hypertrophy developed complaints such as insomnia and fear of death after surgery. Alprazolam 1 mg/day was started to the patient. After using alprazolam treatment, complaints of drowsiness and inability to urinate in the patient started. There was no pathologic finding to explain the urinary retention in the patient who underwent cystoscopy. The alprazolam treatment was discontinued in the patient who consulted to us about urine retention. It was observed that the patient was able to urinate without urinary catheter after the alprazolam treatment was stopped. Urinary retention following use of benzodiazepines (clonazepam and diazepam) has been reported. But, as far as we know, there has been no report of urine retention after the use of alprazolam in the literature. Also, elderly patients are at higher risk for developing drug-induced urinary retention, because of existing co-morbidities such as benign prostatic hyperplasia and the use of other concomitant medication that could reinforce the impairing effect on micturition. This case is remarkable both reporting the development of urinary retention after alprazolam use and in attracting attention to urinary retention that may develop with the use of benzodiazepine in elderly patients with disorders that have impairing effect on micturition.

**KEYWORDS**

Urinary retention;  
alprazolam; insomnia

Abstract:0171

## Aripiprazole: A Possible Cause of Menometrorrhagia

Burak Karakök and Halime Tuna Çak

Department of Child and Adolescent Psychiatry, Hacettepe University School of Medicine, Ankara, Turkey

E-mail address: [burak.karakok@hotmail.com](mailto:burak.karakok@hotmail.com)

**ABSTRACT**

Menometrorrhagia is a condition in which prolonged or excessive uterine bleeding occurs irregularly and more frequently than normal. There are a few consumer reported menometrorrhagia cases while using aripiprazole and one incident was mentioned on an FDA report. A seventeen-year-old girl with moderate mental retardation had been using aripiprazole for one year. In her medical history, she was treated with risperidone for irritability and hyperactivity for one year. Risperidone was discontinued due to weight gain, hypomenorrhea and reduced effectiveness on her symptoms and aripiprazole was initiated. Within a year of the initiation of aripiprazole, she complained of prolonged and abundant menstrual bleeding and presented to Child and Adolescence Psychiatry Department with the thought of an adverse effect of aripiprazole. Her vital signs were normal and there was no pathological physical examination finding. USG performed by an obstetrician was evaluated as normal. Complete blood count and hemostasis parameters were normal. On account of excluding other causes of menometrorrhagia, we speculated that aripiprazole induced this symptom and stopped the treatment. Within 3 months of follow-up, her menstrual cycles have been regular. Although a few patients shared their experiences of menorrhagia and metrorrhagia associated with aripiprazole on patients' health websites, aripiprazole has not been previously reported as a cause of menometrorrhagia. However, Hoşoğlu and friends reported a case presenting with nasal and gingival bleeding during aripiprazole treatment and suggested that aripiprazole's 5-HT<sub>2A</sub> antagonism might have possibly caused bleeding by its antithrombotic effect on microcirculation. Although it is a rarely reported adverse effect, bleeding might be more frequent than reported. Clinicians should be aware of this adverse effect and further trials should be done to explain this effect.

**KEYWORDS**

Aripiprazole;  
menometrorrhagia; bleeding;  
adverse effect

Abstract:0179

## Remission Achieved by Augmentation with Modafinil in a Patient with Treatment-Resistant Depression: A Case Report

Pınar Kızılay Çankaya<sup>a</sup>, İlkey Keleş Altun<sup>b</sup>, Eren Abatan<sup>a</sup> and Emel Uysal<sup>c</sup>

<sup>a</sup>Fatih State Hospital, Psychiatry Clinic, Trabzon, Turkey; <sup>b</sup>Kanuni Training and Research Hospital, Psychiatry Clinic, Trabzon, Turkey;

<sup>c</sup>Department of Psychiatry, Karadeniz Technical University, Trabzon, Turkey

E-mail address: [dremelkorkmaz@gmail.com](mailto:dremelkorkmaz@gmail.com)

### ABSTRACT

Modafinil is a medication approved by the FDA to treat excessive daytime sleepiness associated with narcolepsy. It is also has been reported as a treatment option in a treatment resistant depression but evidence is sparse. In this case report, we present a patient diagnosed with depression, which had previously failed augmentation with aripiprazole and lamotrigine but achieved remission with the addition of modafinil. A 25 year-old male patient applied to the outpatient clinic. Two years ago, the patient started treatment with paroxetine 20 mg/day with somatic complaints and anxiety. The patient's complaints have declined with this treatment. However, on initial evaluation, he reported a number of depressive symptoms including anhedonia, low energy, lack of motivation and drive. He was postponing his works repetitiously and he wasn't going to school. He was spending all his time playing computer games or sleeping at home. Laboratory studies were all within normal limits. Paroxetine was increased to 40 mg/day gradually but there was no improvement in his symptoms. In the follow-up, aripiprazole and lamotrigine were tried as the strengthening options but the patient did not benefit. Subsequently, paroxetine was reduced and switching to venlafaxine extended release was attempted but continued with paroxetine because the patient was unable to tolerate it. There was a remarkable improvement in the depressive symptoms of the patient after he started paroxetine 40 mg/day and modafinil 100 mg/day. On follow-up, modafinil was increased to 200 mg/day and it resulted in full remission of the patient. Modafinil is not a widely preferred augmentation option by clinicians in the treatment of major depression. In this case report, it is aimed to draw attention to augmentation with modafinil in a patient with treatment resistant depression with continued low energy.

### KEYWORDS

Modafinil; treatment-resistant depression; augmentation

Abstract:0191

## Is There Any Antidepressant Effect of Rasagiline in Bipolar Depression?

Yusuf Çokünlü, Tuba Şerife Elmas, Süleyman Özbek, Ali Metehan Çalışkan and İbrahim Eren

Department of Psychiatry, Konya Training and Research Hospital, Konya, Turkey

E-mail address: [dr.bendirzen@hotmail.com](mailto:dr.bendirzen@hotmail.com)

### ABSTRACT

Patients with bipolar disorder experience depressive episodes three times more often than they do manic and hypomanic episodes. Depression, having a greater impact on patient's global psychosocial functioning. Despite a wide range of various drugs, a significant proportion of depressed bipolar patients fail to respond to the treatment strategies. Rasagiline second-generation, selective, irreversible monoamine oxidase- B inhibitor (MAO-B), is used clinically in treatment of Parkinson's disease. A 58-year-old man with Bipolar I Disorder. The patient admitted to our psychiatry inpatient clinic due to depressed mood, unhappiness, disturbed sleep and appetite, anhedonia, mutism, loss of interest in activities. For the last six months, the patient was receiving sodium valproate (1000 mg/day) and fortnightly 200 mg zuclopenthixol decanoate intramuscular injections. The patient was leaning slightly forward, his arms slightly bent from the elbow and not swinging as he walked. Bradykinesia, rigid and associative movements was noted on examination. Sodium valproate 1000 mg/day, quetiapine 300 mg/day and biperiden 4 mg/day was started. 18 sessions of electroconvulsive therapy was applied. Depressive and parkinsonian symptoms did not improve with this therapy. Antipsychotic medications was stopped because of extrapyramidal side effects and lithium 900 mg/day was started (Lithium level: 0.84 mEq/L). After 3 weeks, rasagiline was added to treatment at the recommendation of neurology. After addition of rasagiline both the patient's depressive and parkinsonian symptoms were improvement. It was demonstrated that protective potential of rasagiline on depressive-like behavior and cognitive impairment in aged mice. The clinical efficacy of rasagiline is well established. In the ADAGIO study (Attenuation of Disease Progression with Azilect Given Once daily), treatment with rasagiline was reported to improve mood symptoms on the non-motor

### KEYWORDS

Bipolar depression; extrapyramidal side effects; rasagiline



experiences of daily living. This case report suggests that rasagiline as adjunct-therapy may be an effective and safe medication for treating treatment-resistant bipolar depression.

Abstract:0208

## Quetiapine-Induced Autoimmune Hemolytic Anemia in a Child Patient: A Case Report

Asiye Arıcı<sup>a</sup>, Hatice Altun<sup>a</sup> and Can Acıpayam<sup>b</sup>

<sup>a</sup>Department of Child and Adolescent Psychiatry, Kahramanmaraş Sutcu Imam University, Kahramanmaraş, Turkey; <sup>b</sup>Department of child hematology-oncology, Kahramanmaraş Sutcu Imam University, Kahramanmaraş, Turkey

E-mail address: [drhaticealtun@gmail.com](mailto:drhaticealtun@gmail.com)

### ABSTRACT

Autoimmune hemolytic anemia (AIHA) can be roughly stratified into two groups according to serological features and secondary causes including drugs induced hemolytic anemia. Drugs induced AIHA is very rare in pediatric patients. Even though hematological side effects such as leukopenia, agranulocytosis, eosinophilia, thrombocytopenic purpura and aplastic anemia might occur due to psychotropic drug use; to the best of our knowledge there is no AIHA case due to quetiapine, an atypical antipsychotics, in literature. We hereby describe the first child case of AIHA during quetiapine treatment. A 12 year-old male patient who have been followed-up with mental retardation and attention deficit hyperactivity disorder in our clinic for 6 years was receiving risperidone for 5 years. Patient experienced risperidone-induced a convulsion. His laboratory test results were normal. After discontinuation of risperidone, quetiapine 12.5 mg/day was initiated for his complaints and four days later the dose was increased to 25 mg/day. Patient presented to pediatric emergency department with weakness and jaundice at the 8th day of treatment. In his laboratory tests these results were observed: Hgb 9.6 g/dL, RBC 3.21 M/uL, reticulocyte (RET) 2.01%, (WBC) 6.81 K/uL, LDH 307 U/L, total bilirubin 3.8 mg/dl, direct bilirubin 0.8 mg/dl, indirect bilirubin 2.88 mg/dL. In his physical examination general medical condition was moderate, his sclera was icteric and his abdomen was slightly sensitive. Patient was diagnosed as hemolytic anemia and steroid treatment was initiated in hematology department. Vitamin B12 level was normal, folic acid level was low and ferritin level was high. Others all organic tests were normal. Because of his direct Coombs test (+++++) result and other laboratory and clinical findings, his AIHA diagnose was related with quetiapine use. It is unclear whether quetiapine or its metabolites cause this clinical picture and whether hemolysis occurred with or without dose-dependent manner. To our knowledge, this case is the first case to report quetiapine-related hemolytic anemia and one should always keep in mind that atypical antipsychotics might cause several hematological side effects including hemolytic anemia.

### KEYWORDS

Autoimmune hemolytic anemia; antipsychotic drugs; child; hematological side effects; quetiapine

Abstract:0210

## Obsessive-Compulsive Symptoms Caused by Atypical Antipsychotic Treatment in Bipolar Disorder

Pelin Çon Bayhan

Psychiatry Hospital, Samsun, Turkey

E-mail address: [pelincon\\_1986@hotmail.com](mailto:pelincon_1986@hotmail.com)

### ABSTRACT

Atypical antipsychotics (AAPs) can induce emergence and exacerbation of obsessive-compulsive symptoms (OCS) in some patients. Induced OCS may be due to complex neuromodulation involving many serotonin, dopamine and glutamate receptors. Girl patient who is 16 years old applied to outpatient clinic with complaints as feeling very energetic, rising in self-esteem, speaking a lot, decreasing in sleep duration for a week. Risperidone 3 mg/day had been started at another hospital five days before. She had a depressive episode before. She was hospitalized with diagnosis of bipolar disorder and the same medical treatment was continued. Obsessive-compulsive symptoms (OCS) started a week later. She had no history of obsessive-compulsive disorder (OCD). Risperidone was slowly reduced and discontinued. Olanzapine 10 mg/day was started, but manic symptoms

### KEYWORDS

Obsessive-compulsive disorder; bipolar disorder; risperidone; olanzapine



continued without decreasing. Lithium 900 mg/day was started instead. The severity of OCSs and manic symptoms decreased after the initiation of lithium treatment. The Yale-Brown Obsessive Compulsive Scale (Y-BOCS) score decreased from 16 to 1 after two weeks. AAPs are efficient as augmentation to selective serotonin reuptake inhibitors (SSRI) in treatment resistant OCD, but AAPs cause induced OCS in some patients. It has been suggested that the anti-serotonergic effects of AAPs are responsible for the emergence of OCSs and the dopamine is implicated in the mediation of some obsessive-compulsive behaviors. Reports of atypical antipsychotic drug-related OCSs are linked to clozapine, risperidone, olanzapine and quetiapine. AAPs induced OCSs seem to be dose-related. Treatment-induced OCSs emerged within weeks to months of AAPs therapy or dose increase. The onset of OCSs does not seem to be predictable. Especially when high doses of AAP are used, OCS should be followed closely.

Abstract:0211

## Tactile Hallucination Developed by Use of Atomoxetine

Neslihan Taştepe, Melike Kevser Gül, Sevgi Özmen and Esra Demirci

Department of Child and Adolescent Psychiatry, Erciyes University, Kayseri, Turkey

E-mail address: [ntastepe1@hotmail.com](mailto:ntastepe1@hotmail.com)

### ABSTRACT

Tactile hallucination (TH) is defined as cutaneous sensations of crawling, stinging, and biting without evidence of infestation to explain these sensations. Stimulant medications such as methylphenidate and mixed amphetamine salts used for the treatment of ADHD have been reported to be associated with TH in five cases in the literature. In all cases, TH resolved after discontinuation of the associated medication. We were unable to find any case of atomoxetine induced tactile hallucination via PubMed and Google Scholar. A 7 years old girl, who was referred our polyclinic with complaints of inattention, forgetfulness, difficulty doing homework, stubbornness. We diagnosed as ADHD inattentive type. ATX was initiated at a dosage of 10 mg /day and the dosage was increased 18 mg/day after 2 weeks. Since the beginning treatment, she had itching in the head and defined cutaneous sensations crawling and biting. We wanted dermatology consultation and they evaluated dermatologic disorders which cause itching in head and they said it was normal from a dermatologically. We searched disorders which occur tactile hallucinations and distinguished psychotic disorders, organic causes such as neurologic diseases, nutritional deficiencies and dermatologic conditions, central pruritus. We decided it was side effect of ATX, we stopped ATX treatment by reducing the dose. 1 month later we evaluated and there was no symptoms. One commonly reported group of medications causing TH in the literature was dopaminergic agents. Stimulants such as methylphenidate and mixed amphetamine salts. TX, is a selective norepinephrine reuptake inhibitor and the first non-stimulant medication for the treatment of ADHD. In our case, we thought that ATX induced tactile hallucination because of developing after the initiation ATX. We believe that clinicians should be aware of this side effect of ATX and should be searched with the clinical trials.

### KEYWORDS

Atomoxetine; hallucination; tactile; treatment

Abstract:0212

## Is Intracranial Hemorrhage and Sudden Hypertension Related to Antipsychotic Use?

Tuba Şerife Elmas, Saliha Çalışır, Ali Baran Tanrikulu, Yusuf Çökünlü, Mustafa Çağrı Yıldız, Zeynep Yücehan and İbrahim Eren

Department of Psychiatry, Konya Training and Research Hospital, Konya, Turkey

E-mail address: [tubaserife@gmail.com](mailto:tubaserife@gmail.com)

### ABSTRACT

Stroke is second most common cause of death and major cause of disability worldwide. The antipsychotic treatment is associated with increased risk of cerebrovascular events in elderly patients. We present the case of a patient with schizoaffective disorder who was treated with

### KEYWORDS

Antipsychotics; intracranial hemorrhage; schizoaffective disorder

antipsychotics and complicated by intracranial hemorrhage after sudden hypertension. A 68-year-old woman patient presented to our inpatient clinic with nervousness, irritability, psychomotor agitation, and logorrhea, flights of ideas, decreased need to sleep, grandiose, paranoid, reference delusions, auditory and visual hallucinations. She had a diagnosis of schizoaffective disorder since age 21. There was no prior history of any other medical disease. Her routine laboratory and physical examination were within normal limits. BMI 25 kg/m<sup>2</sup>, no smoking. Her blood pressure monitors were all under 140/90 mmHg. Treatment was initiated as Quetiapine 12.5 mg/day. Two days later, followed by Risperidone 0.5 mg/day and Quetiapine 25 mg/day. Risperidone dose 2 mg/day was gradually raised and continued for ten days. Suddenly vomiting and loss of consciousness developed after a headache. That blood pressure was 220/140 mmHg. After the first intervention, intracranial hemorrhage was detected in the cranial CT scan taken by the emergency department. When the consciousness started to open, left hemiplegia, speech impairment was detected. Neurosurgery planned operation. In our case, there was no vascular risk factors, such as history of previous stroke, diabetes, hypertension, hyperlipidemia, obesity, smoking and atrial fibrillation and whether it is by chance or by antipsychotic treatment is unclear. Clinical studies indicated that antipsychotics may increase the risk of stroke. In hypertensive rat studies with risperidone may increase the vulnerability to stroke as endothelium injury. Another one long-term clozapine treatment is associated with increased rates of hypertension. Older adults who take atypical antipsychotics may have a risk of cerebrovascular events. Regular blood pressure should be followed.

Abstract:0217

## Decrease in Prolactin Levels After Switching From Long-Acting Injectable Risperidone to Paliperidone Palmitate: A Case Report

İlkay Keleş Altun<sup>a</sup>, Pinar Kızılay Çankaya<sup>b</sup> and Emel Uysal<sup>c</sup>

<sup>a</sup>Department of Psychiatry, Kanuni Research and Training Hospital, Trabzon, Turkey; <sup>b</sup>Psychiatry Clinic, Fatih State Hospital, Trabzon, Turkey;

<sup>c</sup>Department of Psychiatry, Karadeniz Technical University, Trabzon, Turkey

E-mail address: [dremelkorkmaz@gmail.com](mailto:dremelkorkmaz@gmail.com)

### ABSTRACT

Hyperprolactinemia is a side effect of antipsychotic medications and may cause amenorrhea, hirsutism and sexual dysfunction. In this case report, we present a female bipolar disorder patient had hyperprolactinemia and benefited switching from long-acting injectable (LAI) risperidone to paliperidone palmitate (PP). A 24 year old single female patient had a history of bipolar disorder for five years referred to our outpatient clinic by the gynecologist with symptoms of four months prolonged amenorrhea, hirsutism in September 2016. She had been treated 50 mg of LAI risperidone and valproic acid (VA) 1000 mg/day, had 16 months of euthymia. Her prolactin level was 121.0 ng/ml. On her next injection day LAI risperidone was switched to 100 mg of PP and VA 1000 mg/day was continued. Manic or depressive symptoms were not observed in monthly outpatient clinic controls, euthymic state was continued. Serum prolactin level was 28.3 ng/ml in December 2016 on the third control, after the third PP injection. She had her menstrual period twenty days before the control. Risperidone is one of the most potent drugs for prolactin elevation. Prolactin levels in patients treated with LAI risperidone seem to be generally lower than the oral form. Paliperidone is an active metabolite of risperidone. Paliperidone's mechanism of prolactin elevation is substantially congeneric to risperidone. Nevertheless, according to two studies published in 2013, prolactin levels decreased after switching from risperidone to paliperidone. On the contrary, Pandina (2011) have reported no differences in prolactin levels between risperidone-LAI and PP. However, this study compare two long-acting forms yet don't analyze the shift from risperidone-LAI to PP. As a conclusion clinicians should periodically assess prolactin levels of patients on risperidone and paliperidone palmitate. Switching from risperidone-LAI to PP can be an alternative way to decrease prolactin levels.

### KEYWORDS

Hyperprolactinemia; paliperidone palmitate; long-acting injectable (LAI) risperidone

Abstract:0221

## Effect of the Addition of Long-Acting Injectable Aripiprazole on Risperidone Long-Acting Injection-Induced Hyperprolactinemia

Elif Nurgül Sungur and Ayşe Nur İnci Kenar

Department of Psychiatry, Pamukkale University, Denizli, Turkey

E-mail address: [e.nurgul@hotmail.com](mailto:e.nurgul@hotmail.com)

### ABSTRACT

Aripiprazole has D2 receptor agonist and 5HT<sub>2A</sub> receptor antagonist properties, thus does not increase prolactin levels and may even decrease high prolactin levels associated with the use of other antipsychotics. Several studies have showed an improvement of drug-induced hyperprolactinemia after adding or switching to oral aripiprazole, however there are only a few case report about long-acting injectable (LAI) aripiprazole reduced blood prolactin level. We report a case that was treated with risperidone depot 25 mg/2 weeks and decreased her prolactin level after addition of LAI aripiprazole to treatment. A 29 year-old female patient. Her main symptoms included depressed mood, irritability, reference thoughts, self-mutilation and suicidal behavior after stressors for about 8 years. She was diagnosed major depression according to DSM-5 criteria. Her last treatment has been arranged as risperidone depot 25 mg/2 weeks. Routine blood tests showed hyperprolactinemia of 39.9 ng/ml and after 1 month of LAI aripiprazole treatment her prolactin level decreased to 21.9 ng/ml. Finally, her symptoms regressed. Risperidone increased prolactin level by its D2 receptor blockage effect and might directly affect the anterior pituitary gland, which resides outside the blood brain barrier. Aripiprazole has been shown to decrease high prolactin levels induced by risperidone long-acting injection in previous cases. Previously in two cases reported that who were treated with paliperidone depot 100 mg/month, risperidone depot 50 mg/2 weeks, then the normalization of prolactin levels were observed as soon as 2–3 months after switching to LAI aripiprazole. However in this case, LAI aripiprazole added to treatment without stopping risperidone long-acting injection and continued treatment with dual depot injunction. Finally, LAI aripiprazole may be an alternative for treating antipsychotic-induced hyperprolactinemia.

### KEYWORDS

Hyperprolactinemia; LAI; aripiprazole; antipsychotic

Abstract:0229

## Myoclonus Associated with Long-Term Use of Fluoxetine: A Case Report

Sevde Afife Ersoy

Department of Child and Adolescent Psychiatry, Selcuk University, Konya, Turkey

E-mail address: [safife-dr@hotmail.com](mailto:safife-dr@hotmail.com)

### ABSTRACT

Myoclonus are unintentional movements in the form of sudden, brief (<100 ms), shock-like throwing, which can hold the extremities, face and trunk. Various drugs which is most often reported in relation to opiates, antidepressants, antipsychotics, and antibiotics can cause myoclonus. We here describe a case of drug-induced myoclonus by prolonged fluoxetine treatment. A 32 year-old woman who has been treated for depression with fluoxetine (40 mg/day) 5 years previously. The patient developed involuntary jerks through her whole body but predominantly in her upper extremities and neck, also severely affecting her casual activities like eating and sleeping since last one month. On examination she was alert, cooperative and oriented. We observed spontaneous, irregular and non-rhythmical myoclonic jerks of the head, neck, and arms but most marked in her neck. She had cogwheel rigidity in upper extremities and dystonia on her strap muscles of the neck, and shoulders. The rest of the neurologic examination was normal. Fluoxetine was discontinued and consulted to neurologist who had diagnosed her with myoclonus. A trial of valproic acid was commenced to treat the myoclonus, resulted in mild improvement after 3 weeks of treatment at therapeutic blood levels. Next, a trial of clonazepam was added to treat the myoclonus and at the end of 7 weeks the patient was transferred to the neurology clinic. Experimental animal studies and case reports support the association between serotonin and myoclonus. Fluoxetine may indirectly influence dopaminergic neurons or use of SSRI cause 5-HT receptor hypersensitivity similar to that in experimental animals. In our patient movements appeared after prolonged therapy with fluoxetine. There was no central nervous system impairment or concurrent drug use predisposing to myoclonus. Clinicians should be aware that myoclonus may be a side effect associated with SSRIs, especially treatment of long-term periods.

### KEYWORDS

Fluoxetine; myoclonus; side effect

Abstract:0232

## Facial Edema Developed After Use of Olanzapine: A Case Report

Mehmet Gürkan Güröğ, Sevler Yıldız, Tuba Korucu, Denizhan Danacı Keles and Murad Atmaca

Department of Psychiatry, Firat University School of Medicine, Elazığ, Turkey

E-mail address: [mggurog@hotmail.com](mailto:mggurog@hotmail.com)

### ABSTRACT

Olanzapine is an atypical antipsychotic medicine which has proven successful in the treatment of some psychiatric disorders, primarily bipolar disorder, schizophrenia, and similar psychotic disorders. Such frequent anticholinergic side-effects as weight-gain, sedation, dry mouth and constipation may be observed in patients using olanzapine; besides, it is reported in a study that Olanzapine may lead to peripheral edema in 3%. However, there are few studies reporting facial edema. In the present study, we report the case of a facial edema due to use of Olanzapine by a young patient who does not have any medical illness history. A 21 years old, student, the fourth of seven siblings. She does not any medical illness history. The patient, who said that he had not taken any psychiatric treatment before, had the symptoms of irritability, insomnia, audial hallucinations, delusions of persecution, social isolation. On the 8th day of Olanzapine treatment, a swell was noticed on the patient's face, and it was observed that this edema gradually increased. On the 13th day of Olanzapine treatment, during the systemic examination of the patient who had difficulty in opening his eyes, no other finding other than facial edema was observed. When Olanzapine treatment was stopped, the facial edema started to decrease, and disappeared nearly one week later. An aripiprazole treatment was started, but as it was not useful for the patient, a clozapine treatment was started, the psychiatric symptoms of the patient regressed. Olanzapine's mechanism for causing edema is not yet clearly identified, it is thought that Olanzapine blocks alpha-1 receptors and decreases vascular resistance, causing periphery vasodilatation and thus edema. We think that it may be a contribution to the relevant literature to report this side-effect, whose pathophysiology needs to be clearly explained with more research.

### KEYWORDS

Antipsychotic; edema; olanzapine

Abstract:0241

## Buspirone Use for Bruxism in a Child with Severe Mental Retardation and Autistic Features

Esra Hoşoğlu and Ömer Faruk Akça

Department of Child and Adolescent Psychiatry, Necmettin Erbakan University Meram School of Medicine, Konya, Turkey

E-mail address: [crsesrahosoglu@gmail.com](mailto:crsesrahosoglu@gmail.com)

### ABSTRACT

Bruxism is defined as nonfunctional clenching or grinding and more frequent in developmental disorders. The cause of bruxism is not fully understood and there is no specific treatment for bruxism. Pharmacologic agents including benzodiazepine, amitriptyline, propranolol, botulinum, and clonidine have been used in bruxism treatment. In this report we presented a child with severe mental retardation and autistic features whose bruxism disappeared after bruxism treatment. A 6 year-old girl with diagnoses of severe mental retardation and autistic features referred to our out-patient clinic to obtain a statement of health to receive special education. She was also being followed by neurology because of epilepsy. During the interview it was observed that she was frequently grinding her teeth. Her mother reported that she has been grinding her teeth in daytime for about two years. Because the family wanted to receive treatment for bruxism, buspirone 5 mg/day was started on the morning. In their second visit after three weeks of medication her mother stated that bruxism was disappeared in the second week of treatment. Buspirone is an effective agent in anxiety disorders with low side effects. Successful treatment of bruxism with buspirone has been previously reported in patients with drug-induced bruxism and it has been suggested that buspirone may reduce bruxism by increasing dopamine level in striatum via partial agonism at 5HT1A receptors. In the literature there is a report of treatment of non-drug-related bruxism in a child with developmental disorder. In this report we also observed that buspirone may a treatment option for bruxism in patients with developmental disorders.

### KEYWORDS

Bruxism; buspirone; mental retardation

Abstract:0270

## Amotivational Syndrome Induced by Volatile Adhesive: A Case Report

Kübra Kılınç<sup>a</sup> and Barış Şen<sup>b</sup>

<sup>a</sup>Department of Child And Adolescent Psychiatry, Selcuk University, Konya, Turkey; <sup>b</sup>Department of Psychiatry, Selcuk University, Konya, Turkey

E-mail address: [kubradurmus\\_1991@hotmail.com](mailto:kubradurmus_1991@hotmail.com)

### ABSTRACT

Amotivational syndrome is a chronic psychiatric disorder characterized by a variety of changes in personality, emotions and cognitive functions such as lack of activity, inward-turning, avolition, apathy, incoherence, blunted affect, inability to concentrate and memory disturbance. There have been several reports describing similar psychiatric disorders to AS among patients with the history of some psychotropic substances use including solvents, methamphetamine and cough syrup. We would like to present a case of AS with volatile adhesive exposure in this report. The patient was a 47 year-old man, married and had 3 children. He was working in a shoe manufacturing workshop. About the last five months, there were complaints about unwillingness to communicate with the environment, closure, loss of living and working motivation, malaise. There was indifference to family members, watching television most of the day, not being in contact, eating one meal a day, not bathing and shaving for about 2 months, never been out of the house. He complained that he could not do the job he had before, such as problem solving, reasoning, small-scale renovation work, and some home shopping needs. For the last 26 years there has been exposure to adhesive composition containing polychloroprene and polyurethane, unprotected with a mask. Venlafaxine 150 mg/day and pramipexole 0.125 mg/day were started with diagnosis of AS. Significant improvement was observed in about 2 weeks. We evaluated the development of the AS connected with the adhesive composition containing polychloroprene and polyurethane. There are studies that report positive results with the use of various noradrenergic and dopaminergic drugs in the treatment of AS. It should also be kept in mind that AS may be caused by exposure to occupational chemicals.

### KEYWORDS

Adhesive; amotivational syndrome; volatile

Abstract:0272

## SILENT Induced by Chronic Lithium Use: A Case Report

Erdem Örnek, Cengiz Çelebi, Ayşe Sakallı Kani, Ömer Yanartaş, Zeynep Şenkal, Yıldız Akvardar and Kaan Kora

Department of Psychiatry, Marmara University Pendik Training and Research Hospital, Istanbul, Turkey

E-mail address: [erdem.ornek@yahoo.com](mailto:erdem.ornek@yahoo.com)

### ABSTRACT

Lithium has been used for more than 50 years in treatment of acute mood episodes as well as prevention of relapses, subsyndromal symptoms and suicide in patients with bipolar disorder. However acute neurotoxicity of lithium is a well-known serious clinical issue that is carefully studied especially in emergency clinics and on the course of treatment, long-term lithium usage may cause insidiously developed persistent side effects in nervous system even if the lithium blood levels are in the therapeutic range. SILENT (syndrome of irreversible lithium effectuated neurotoxicity) is an important iatrogenic condition defined as long-term sequelae of lithium intoxication. Common clinical appearance comprises of persistent cerebellar symptoms such as tremor, dysarthria and ataxia but dementia, brainstem dysfunction and permanent extrapyramidal syndrome may also arise. Although biological mechanisms underlying SILENT remains uncertain, it has been assumed that widespread demyelination caused by lithium in the nervous system may lead the occurrence of SILENT. In this report we present a persistent cerebellar syndrome which has occurred after 20 years of lithium use in a 46 year-old female patient with bipolar disorder. Speech impairment, gait disturbance, disidiadokinesis and dysmetria occurred when the serum level was normal, and maintained after lithium therapy was discontinued. After detailed physical examination and neurological investigations no significant finding was detected associated with the clinical appearance. Cerebellar syndrome was thought to be related with neurotoxicity induced with chronic lithium usage. With this report we aim to present our case comparing with literature and raise the awareness of SILENT and review the putative precipitating factors that may increase the risk of irreversible neurotoxicity.

### KEYWORDS

Lithium; neurotoxicity; cerebellar syndrome



Abstract:0276

## Black Hairy Tongue Induced by Use of Combined Olanzapine and Lithium: A Case Report

Ümrân Egilmez, Ali Kandeğer and Özkan Güler

Department of Psychiatry, Selcuk University, Konya, Turkey

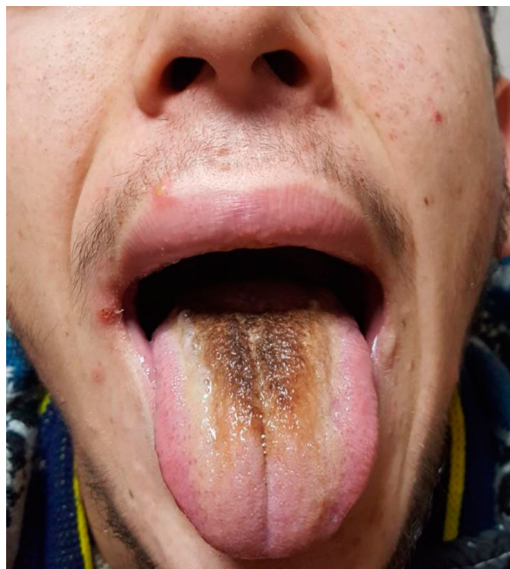
E-mail address: [umrn.egilmez@gmail.com](mailto:umrn.egilmez@gmail.com)

### ABSTRACT

Black Hairy Tongue (BHT) is characterized by accumulation of keratin on the tongue and papillae hypertrophy. BHT may cause the patients to have various complaints including halitosis, disguised. It was reported that poor oral hygiene, smoking, mechanic irritation, alcohol use, some systemic and psychotropic drugs, etc. are among the precipitating factors of BHT. In this presentation, a rarely seen BHT case will be explained, which was developed with combined use of olanzapine and lithium on a patient with Bipolar Mood Disorder (BMD) diagnosis. The patient was a single, 19 years old, male, college student. His relatives indicated that he was very energetic, showing risky behaviors, started smoking and alcohol, and his self-confidence had gone up. The patient was examined and admitted to the hospital due to grandiose delusion and psychotic symptoms. Olanzapine (10 mg/day) and lithium was prescribed to patient after diagnosis of manic episode of BMD. The lithium was increased to 1200 mg/day. After treatment of olanzapine and lithium for 25 days, he had such complains as hairiness on tongue. In the oral cavity exam, dark fledge on the tongue was present (Figure 1). He was diagnosed with BHT due to adverse effect of combined treatment of olanzapine and lithium. He was suggested to brush his tongue three times a day, and to use antiseptic mouthwash, Xerostomia, which was developed with the adverse effect of combined olanzapine and lithium, could be associated with BHT. Xerostomia is among the common adverse effects of lithium. Even though the main reason of xerostomia is known as hyposalivation, thirstiness associated with polyuria could play a critical role. Also olanzapine could cause xerostomia at a relatively low incidence. As a result, It was possible that combined use of olanzapine and lithium could be the cause of BHT development.

### KEYWORDS

Black hairy tongue; lithium; olanzapine; side effect



**Figure 1.** Black Hairy Tongue.

Abstract:0281

## Methylphenidate- and Indomethacin-Induced Visual Hallucination: A Case Report

Kemal Utku Yazici and Ipek Percinel Yazici

Department of Child and Adolescent Psychiatry, Firat University School of Medicine, Elazig, Turkey

E-mail address: [dr.kemal.utku@outlook.com](mailto:dr.kemal.utku@outlook.com)



**ABSTRACT**

A patient diagnosed with attention-deficit/hyperactivity disorder (ADHD) who experienced visual hallucinations developing in the course of concurrent methylphenidate and indomethacin use is discussed in this paper. A 14-year old girl was admitted to our clinic due to weird images. She stated that she saw strange creatures which had a very short stature like a dwarf but with faces different from humans, these creatures looked at her unfriendly and talked between and laughed at her. Her complaints began 48 hours ago. The patient first presented to our clinic four months ago. She was diagnosed with ADHD and 27 mg/day long acting methylphenidate was started and tapered to 36 mg/day thereafter. She had been using methylphenidate for three months when she presented with psychotic symptoms. Her menarche started 4 days ago and she had been using indomethacin for 3 days due to severe dysmenorrhea. Her mother stated that she sometimes experienced headache or abdominal pain and used indomethacin without problem. Organic examinations did not reveal any disorders. Psychotic findings were suggested to result from indomethacin use. Indomethacin was discontinued and methylphenidate continued. Visual hallucinations completely disappeared after discontinuation of indomethacin. Both molecules were reported to be able to cause psychotic symptoms when used separately. In our patient, methylphenidate use alone did not lead to psychotic symptoms. Visual hallucinations emerged when she began to use indomethacin due to dysmenorrhea suggesting that symptoms were related to indomethacin. This condition suggests that these two medications which did not cause a problem when used alone could increase their effects when used together. Drug-drug interactions may lead to dangerous conditions for the patients. Clinicians should keep this in mind in presence of unexpected psychiatric symptoms.

**KEYWORDS**

Adolescent; hallucination; indomethacin; methylphenidate

Abstract:0282

## Urticaria and Angioedema Associated with Bupropion: A Case Report

Selcen Dogru Kösker, Elif Ates Budak, Zeliha Deveci Karasin, Mehmet Diyaddin Güleken and Mustafa Celik

Department of Psychiatry, Diyarbakir Gazi Yasargil Training and Research Hospital, Diyarbakir, Turkey

E-mail address: [scdkosker@yahoo.com](mailto:scdkosker@yahoo.com)

**ABSTRACT**

Drug-induced skin reactions has been reported commonly, which may include a wide range from mild exanthemas to serious systematic reactions. Skin reactions are observed more frequent in women, old people, black people, people using multi drugs and people who have serious medical diseases. Bupropion, a widely-used drug for depression and smoking cessation, may also induce urticaria and rash and less commonly angioedema and serum sickness-like reactions. These reactions are thought to be dose related, more frequent in younger patients and especially angioedema more frequent in women. Here, we report a case of a 28-year-old female who was suffering depression and had angioedema and urticaria induced with bupropion treatment. Main complaints of the patient were unhappiness, unwillingness, heaviness, loss of energy, difficulty in concentration, decreased sleep time. Depressive symptoms were assessed using the Hamilton Depression Rating Scale and her score was 21. Bupropion XL 150 mg/day was administered. After 20 days, the patient was presented with the complaints of urticaria on her face, body and limbs, angioedema in the eyes and lips, tightness in the chest and shortness of breath which were existing for a week. She had no other medical disease or drug use. She was diagnosed with urticaria and angioedema with systematic reactions, and bupropion was discontinued due to recommendation of dermatology consultation. The symptoms had disappeared with antihistaminic treatment. Bupropion's allergic side effects has been reported in previous studies and case reports. Because not only skin reactions but also systemic reactions may be induced, clinicians should be careful against these adverse effects of bupropion.

**KEYWORDS**

Bupropion; allergic reactions; side effects; depression; urticaria; angioedema

Abstract:0291

## Duloxetine in an Adolescent with Body Dysmorphic Disorder: A Case Report

Ipek Percinel Yazici<sup>a</sup> and Kemal Utku Yazici<sup>a</sup>

Department of Child and Adolescent Psychiatry, Firat University School of Medicine, Elazig, Turkey

E-mail address: [ipek.pr@hotmail.com](mailto:ipek.pr@hotmail.com)

**ABSTRACT**

In this paper, duloxetine treatment in an adolescent patient with body dysmorphic disorder (BDD) who did not benefit from selective serotonin reuptake inhibitor (SSRI) was discussed. A 17-year-old male patient presented to our clinic due to checking his face frequently in the mirror, thinking that his right ear is bigger than the left, continuously dealing with a scar tissue in his face, thinking that other people continuously look at this scar, unhappiness, social isolation, distractibility, irritability, harming himself and other people and suicide thoughts. He was diagnosed with BDD and major depression and medication was started at another institution. He was treated with fluoxetine, sertraline, aripiprazole, risperidone and clomipramine alone or in combination in proper doses and durations during his one year follow up. He and his family stated that medications decreased depressive feelings however a significant improvement couldn't be obtained in his beliefs about body dysmorphic disorder. He presented to our clinic as depressive findings increased. He was diagnosed with BDD and major depression. Considering his prior drug therapy and current status, duloxetine was started 30 mg/day and increased to 60 mg/day carefully. BDD symptoms were decreased in follow-up. Thereafter depressive symptoms were significantly improved together with normalization of body image perception. All of his complaints improved at the end of 6 months of therapy. The drug was well tolerated and no drug-related side effects were encountered. Duloxetine is a serotonin norepinephrine reuptake inhibitor (SNRI) group antidepressant which inhibits serotonin and norepinephrine reuptake. Its use is gradually increasing in psycho-pharmacology of children and adolescents. However no reports are available in literature about duloxetine use in adolescent with BDD. Our case significantly benefited from duloxetine treatment. A SNRI drug, duloxetine may be an alternative pharmacologic agent in adolescents with SSRI-resistant BDD.

**KEYWORDS**

Adolescent; body dysmorphic disorder; duloxetine; treatment

Abstract:0292

## Clozapine-Induced Perimyocarditis: A Case Report

Hande Yıldırım and Ayşe Ender Altıntoprak

Department of Psychiatry, Ege University School of Medicine, Izmir, Turkey

E-mail address: [yildirim-hande@hotmail.com](mailto:yildirim-hande@hotmail.com)

**ABSTRACT**

Clozapine is an exceptionally effective antipsychotic which is reserved for treatment-resistant schizophrenia because of its adverse effects. These are predominantly neutropenia and agranulocytosis. Other adverse reactions which also limit its use include sedation, hypotension, seizures, metabolic syndrome and myocarditis. A 39 year-old man with schizoaffective disorder and multiple-substance use disorder, presented to our clinic with suicidal and homicidal thoughts, marijuana and biperidene use. We learned with his psychiatric interview that he used marijuana, biperidene, synthetic cannabinoid, clonazepam, alprazolam. He was diagnosed with schizoaffective disorder in 2013 and for this reason he was hospitalized two times in 2013 and in 2014. In psychiatric examination; auditory, visual and olfactory hallucinations; reference delusion, marijuana and biperidene withdrawal and craving were found. Clozapine was applied to the patient who could not respond to olanzapine 30 mg/day, risperidone long acting injection 50 mg intramuscularly every 2 weeks and venlafaxine 150 mg/day treatment. Clozapine was initiated at a dose of 25 mg per day, and titrated up to 200 mg. At first visit, he was somnolent, febrile and tachycardia. His laboratory results were significant for an elevated CRP, troponin T and leukocytosis. Because of common ST elevation in ECG and elevation of troponin-T, echocardiography was performed by the cardiologist. Pericarditis and myocarditis were coexisted. Clozapine treatment was stopped immediately. Then, fever, chest pain, leukocytosis, elevation of CRP and troponin-T trended down to normal. Several symptoms that are characteristics of clozapine-related myocarditis such as mild fever, tachycardia, and fatigue, are reported to be relatively common while initiating clozapine titration. Once clozapine-related myocarditis has been diagnosed, it is mandatory to immediately stop clozapine treatment. Because myocarditis has a high mortality rate, clinicians should be on high alert when clozapine patients display any symptoms of myocarditis.

**KEYWORDS**

Clozapine; myocarditis; pericarditis

Abstract:0305

## Clozapine Treatment in Risperidone-Induced Pisa Syndrome

Burçin Güler and Baybars Veznedaroğlu

Department of Psychiatry, Ege University School of Medicine, Izmir, Turkey

E-mail address: [guler-burcin@hotmail.com](mailto:guler-burcin@hotmail.com)

### ABSTRACT

Risperidone is a selective monoaminergic antagonist with a high affinity for dopaminergic D2 receptors. Blockade of D2 receptors by classical antipsychotics is responsible for the occurrence of extrapyramidal symptoms such as Pisa Syndrome (PS). A 37 year-old woman, with paranoid schizophrenia, presented to a psychiatry clinic with complaint of wide spread contraction in her body during sitting, doing daily tasks, and especially walking. She was taking long-acting injectable risperidone 50 mg/two weeks. This postural disturbance emerged within four months, after parenteral administration of risperidone 100 mg at last dose, by mistake. Orofacial dyskinesia, dystonia, and opisthotonus developed approximately within 6 months after parenteral administration of risperidone, respectively. She was admitted to our inpatient mental health service due to deterioration of extrapyramidal symptoms. At admission she was taking biperiden and diazepam. Biperiden was discontinued and diazepam was switched to alprazolam 3 mg bid clozapine was started at a dose of 25 mg/day, which was increased gradually to 150 mg/day within 4 weeks. A gradual improvement was detected in both extrapyramidal symptoms and psychiatric symptoms after 6 weeks of treatment with clozapine; dystonia, lateral flexion and finally posture and gait was improved. PS is a postural and locomotor disorder characterized by trunk dystonia from cervical to lumbar zone, slight rotation of the trunk and abnormal posture frequently associated with long-term antipsychotic treatment. PS, which is also known as tardive dystonia, is more common in females than males. Older age, presence of organic brain damage, treatment with parenteral antipsychotic and typical antipsychotic agents was found related to PS. Treatment with high dose parenteral antipsychotic is one of the reasons of PS. Treatment approaches include; discontinuation of antipsychotic medication, anticholinergic treatment in some cases, baclofen, and levodopa. The use of clozapine in resistant cases is known to be beneficial, by reducing basal ganglion hypertrophy in tardive dystonia.

### KEYWORDS

Clozapine; risperidone; Pisa syndrome

Abstract:0308

## Atomoxetine for Gelastic Cataplexy: Possible Mode of Action

Funda Lale<sup>a</sup>, Halime Tuna Çak Esen<sup>a</sup> and Gökür Haliloğlu<sup>b</sup>

<sup>a</sup>Department of Child and Adolescent Psychiatry, Hacettepe University School of Medicine, Ankara, Turkey; <sup>b</sup>Department of Pediatric Neurology, Hacettepe University School of Medicine, Ankara, Turkey

E-mail address: [funda-kutuk@hotmail.com](mailto:funda-kutuk@hotmail.com)

### ABSTRACT

Gelastict cataplexy is a rarely described phenomenon in children presenting with a brief episode of bilateral loss of muscle tone, triggered by laughter. Gelastict cataplexy is a strong predictor of NPC, although it may also be seen in patients with narcolepsy. The aim of this report is to demonstrate the successful treatment of gelastict cataplexy with the use of atomoxetine and to discuss the possible mechanisms of drug action. A nine-year-old female patient with moderate mental retardation was diagnosed as NPC1 at age 4 and was under mglustat treatment since then. She developed gelastict cataplexy at the age of 7. She benefitted from imipramine treatment and was free of cataplexy for 16 months. Later, she developed generalized tonic clonic seizures under imipramine and mglustat treatment. Imipramine was stopped and levetiracetam was started for seizures. In two months she was free of seizures but the cataplexy episodes came back and worsened. Then atomoxetine was started and titrated to 1.2 mg/kg/day. She is again free of cataplexy for the last two months. Current studies consider cataplexy as a complex REM-related phenomenon involving multiple neurotransmitter systems. The REM-On and REM-Off networks work together in regulating REM sleep. It is hypothesized that cataplexy occurs when there is a loss in the excitatory noradrenergic and serotonergic neuron activity of the REM-Off network. We had hypothesized that nonspecific monoamine reuptake inhibitors may be useful in the treatment of cataplexy by increasing the availability of serotonin, noradrenaline and dopamine in the monoaminergic neurons of the REM-Off network, which hold back atonia producing pathways during wakefulness. In this report we further focus our hypothesis on noradrenaline with the successful use of atomoxetine. The positive response to atomoxetine

### KEYWORDS

Atomoxetine; gelastict cataplexy; NPC

in our NPC patient supports the idea of the disrupted noradrenergic activity playing a role in the pathophysiology of cataplexy in NPC.

Abstract:0309

## Visual Hallucination Induced by Escitalopram in an Adolescent Patient: A Case Report

Bahar Yeşil<sup>a</sup> and Behice Han Almış<sup>b</sup>

<sup>a</sup>Elazığ Mental Health and Disorders Hospital, Elazığ, Turkey; <sup>b</sup>Health Sciences University Adiyaman Education and Research Hospital, Adiyaman, Turkey

E-mail address: [baharyesilege@hotmail.com](mailto:baharyesilege@hotmail.com)

### ABSTRACT

Escitalopram is a kind of selective serotonin reuptake inhibitor (SSRI) which used in treatment of depression effectively. In this case we report an adolescent patient with depression, who suffered from visual hallucinations. A 16-year-old girl with depression symptoms, such as depressed mood, lack of interest, anhedonia and weight loss, within the previous two weeks. Developmental story and intelligence capacity were normal limits. No severe medical illness and psychotic symptoms was noted. She started to receive escitalopram 5 mg/ day for the first week, with no side effects, then the dose was titrated to 10 mg/day, however within the second week of the escitalopram treatment the patient defined visual hallucinations. Biochemical tests and neuroimaging were normal. Escitalopram was stopped, visual hallucinations disappeared within 3 days without using antipsychotics. In the following six months no hallucination were seen again. The specific cause of the SSRI-induced hallucinations is unclear. A 70 year-old man with depression was suffered from visual and auditory hallucinations after escitalopram treatment. Sensitive patients including youth and elderly could develop hallucinatory behavior as a general adverse reaction to SSRI. The visual hallucination could be developed because of the serotonergic hyperactivity and subsequent cholinergic hypoactivity. Additionally SSRIs would cause hallucinations through direct blockade of dopamine reuptake or indirectly via stimulation of postsynaptic 5HT2 and 5HT3 receptors. Although escitalopram has been reported to be one of the safest SSRIs it might induce the visual hallucinations through the modulation of neurotransmitters. Clinicians should be careful in term of its side effects especially in specific age groups.

### KEYWORDS

Adolescent; hallucination; escitalopram; SSRI

Abstract:0312

## Treatment-Resistant Akathisia: A Case Report

Nuran Ekinci<sup>a</sup> and Gamze Özçürümez Bilgili<sup>b</sup>

<sup>a</sup>Department of Child and Adolescent Psychiatry, Mersin University School of Medicine, Mersin, Turkey; <sup>b</sup>Department of Psychiatry, Mersin University School of Medicine, Mersin, Turkey

E-mail address: [nurangozpinar@gmail.com](mailto:nurangozpinar@gmail.com)

### ABSTRACT

Akathisia is a frequent adverse effect of antipsychotic drugs. Hereby, we report a case of a 59-year-old female who developed treatment resistant akathisia with risperidone. A 59-year-old female suffering from major depressive disorder with psychotic features has been admitted to our inpatient clinic. Firstly, risperidone 1 mg/day and biperiden 4 mg/day were ordered. To target the psychomotor agitation and restlessness symptoms, which foreground of her depressive complaints, clonazepam 4 mg/day was started. Risperidone gradually stopped in two days. Other benzodiazepines (lorazepam and diazepam) and propranolol were tried for 3 weeks but failed. Thereafter, escitalopram 2,5 mg/day was started for depressive symptoms and increased 5 mg/day after 5 days. Mirtazapine 15 mg/day was also added to treatment both for sleep problems and akathisia. But akathisia was still as severe as to lead to suicidal thoughts. Because of the suspect that escitalopram may have worsened akathisia, its dose was decreased to 2,5 mg/day but it did not work. Because of the previous history of several adverse events with psychiatric drugs (akathisia with risperidone, pretibial edema with olanzapine, cellulite with quetiapine etc.), possibility of being slow metabolizer was evaluated. The patient was informed about this evaluation and she gave informed consent to CYP 450 enzymes mutation analysis. According to the analyses, she was conversely found as a "rapid metabolizer for CYP 2D6 and 2C19" and the possibility of being slow metabolizer

### KEYWORDS

Treatment-resistant; akathisia; antipsychotic

was excluded. Other alternative treatment options including baclofen and hydroxyzine were also tried for additional 3 weeks, but akathisia symptoms did not resolve. After three months, the patient was discharged on her own request. Akathisia not responding to two of the three pharmacological treatments is defined as treatment resistant akathisia. The exact mechanism of this reaction is poorly understood and may involve acetylcholine, serotonin, and GABA systems and CYP 450 polymorphisms.

Abstract:0334

## Milnacipran-Induced Spontaneous Ejaculation

Can Tuncer, Volkan Seneger, Rûmeysa Yeni Elbay and Aynur Görmez

Department of Psychiatry, Istanbul Medeniyet University, Istanbul, Turkey

E-mail address: [drctuncer@gmail.com](mailto:drctuncer@gmail.com)

### ABSTRACT

Milnacipran is an antidepressant of selective serotonergic and noradrenergic reuptake inhibitors (SNRIs). There are reports in the literature about venlafaxine, methylphenidate and amphetamine causing spontaneous ejaculation because of adrenaline and noradrenaline increase. That means noradrenergic reuptake inhibitors lead to decrease ejaculatory latency time and ending up with spontaneous ejaculation through peripheral effects of noradrenaline. A 54 years old, male patient presented with the symptoms of erectile difficulties without loss of libido, premature ejaculation, depressive mood, lack of pleasure, irritability, insomnia, marital problems. He was suffering from depression. His medication included milnacipran capsules 25 mg twice a day and mirtazapine tablets 15 mg one tablet at night. Patient revisited the outpatient clinic 4 days later with complaints of spontaneous ejaculation half an hour later taking milnacipran. This continued for 3 consecutive days. Then milnacipran was stopped and spontaneous ejaculation no longer happened. He continued mirtazapine without spontaneous ejaculation. He was on moclobemide 300 mg per day and then moclobemide was increased 600 mg per day. In the literature, to our knowledge, there is only one case report about milnacipran-induced spontaneous ejaculation and it happened after defecation without orgasm. One of the interesting things about our case was he even experienced spontaneous ejaculation while he was walking. None of his spontaneous ejaculation involved sexual activities. This shows that there might be peripheral involvement of ejaculation function under adrenergic control.

### KEYWORDS

Milnacipran; inhibitors; noradrenergic; reuptake; side-effect; spontaneous-ejaculation

Abstract:0355

## Effect of Methylphenidate on Kleptomania in a Child with Attention-Deficit/Hyperactivity Disorder

Ümit Işık

Department of Child and Adolescent Psychiatry, Yozgat State Hospital, Yozgat, Turkey

E-mail address: [crsumt@gmail.com](mailto:crsumt@gmail.com)

### ABSTRACT

Kleptomania is an impulse-control disorder defined as the recurrent failure to resist impulses to steal objects that are not needed for personal use or for their monetary value. Kleptomania is a relatively rare condition. A number of case reports found various medications effective in the treatment of the disorder. There are only three different case reports examined the effect of methylphenidate (MPH) in patients with attention-deficit/hyperactivity disorder (ADHD). I describe a child with kleptomania and ADHD, treated with methylphenidate. A 7-year-old boy was brought to our outpatient clinic by his father for his inattention, short attention time, concentration difficulties, hyperactivity, impulsivity, irritability, oppositional defiant behavior, and stealing behavior. He had stolen his friends' school materials, including pencil sharpeners, pen cap, and eraser dust. His parents reported that although he collected the things that he had stolen, he almost never used them. Though his parents were uncertain whether he experienced tension prior to stealing, he typically seemed to be comfortable after the acts. Though the parents had used various punishments to criminate him for his actions, no reduction in his stealing behaviors was observed. In his psychiatric assessment, he met criteria for combined type ADHD, oppositional defiant disorder and kleptomania. An

### KEYWORDS

ADHD; kleptomania; methylphenidate

18 mg OROS-MPH treatment was initiated daily. It resulted in significant improvement in the his ADHD symptoms and the complete resolution of the kleptomania within the first week. In the present case, it seems that the MPH treatment is responsible for the significant improvement in the patient's stealing behavior. Kleptomania is a rare condition and this report observing the complete resolution of kleptomania with a MPH treatment in a school-age child with ADHD. The anti-kleptomaniac effect of the MPH for ADHD patients' needs to be validated through additional studies.

Abstract:0390

## Risperidone as a Possible Cause of Seizure: A Case Report

Gonca Aşut, Elif Tatlıdil Yaylacı, Ömer Asan and Erol Göka

Department of Psychiatry, Ankara Numune Training and Research Hospital, Ankara, Turkey

E-mail address: [goncaasut@hotmail.com](mailto:goncaasut@hotmail.com)

### ABSTRACT

Seizure is a serious adverse effect which can happen with psychopharmacological treatment. Almost all antipsychotics decrease the seizure threshold to varying degrees and have been associated with increased risk of epileptic seizures. Risperidone, fluphenazine, haloperidol seem to be the least likely antipsychotics to induce seizures. In this case, we report a patient who suffered from seizure provoked with risperidone use. A 32 year-old male patient was admitted to our inpatient unit with 6-months history of auditory and visual hallucinations, persecutory delusion and aggressive behavior. He had been diagnosed with Schizophrenia for 4 years and had taken no medication for the last 3 years. On admission, the laboratory tests and EEG were within the normal ranges and no pathology was detected by Cranial MRI. Risperidone 4 mg/day treatment was initiated and the dose was increased to 8 mg/day on the 3rd day of treatment. He had 2 generalized tonic-clonic seizures on the 10th day of Risperidone 8 mg/day treatment. There were no history of epilepsy, febrile convulsions or concomitant diseases. We took blood and urine sample after both seizures and all results were within normal ranges. The result of Neurology consultation suggested that his seizure might be associated with the antipsychotic medication. Risperidone was stopped and valproate sodium 1000 mg/day was administered. 6 day after the cessation of risperidone treatment his delusions and hallucinations recurred. As he had a history of good response to Risperidone treatment, Risperidone 2 mg/day was restarted and increased to 4 mg/day at day 4. After 24 days of close seizure monitoring he was discharged from the hospital. There is no doubt that many different drugs used in psychiatry can elicit seizures. Risperidone-induced seizures are reported as quiet rare. Due to propensity to provoke seizures seems to be dose related, high dose therapy, rapid upward dose titration and combination with other antipsychotics should be avoided.

### KEYWORDS

Antipsychotics; epileptic seizures; risperidone

Abstract:0394

## Hyperprolactinemic Galactorrhea as a Side Effect of Aripiprazole in an Adolescent: A Case Report

Serkan Güneş

Department of Child and Adolescent Psychiatry, Hatay State Hospital, Hatay, Turkey

E-mail address: [dr\\_sgunes@hotmail.com](mailto:dr_sgunes@hotmail.com)

### ABSTRACT

Aripiprazole is a partial agonist at dopamine D2 and serotonin 5-HT1A receptors, and an antagonist at 5-HT2A receptors. Because of its minimal or no significant effects in prolactin levels, it is known as a prolactin-sparing antipsychotic. In this paper, we report the occurrence of hyperprolactinemic galactorrhea with a low dose of aripiprazole in an adolescent female. A 16 year-old girl was evaluated in our clinic for teenage problems, irritability, and aggression. Aripiprazole 5 mg/day was initiated at night for behavioral problems and impulse control. One month after, the second examination revealed that there was obvious recovery in her symptoms, but she developed breast tenderness and a milky discharge from the nipples. Her serum prolactin level was 42.0 ng/ml (normal range,

### KEYWORDS

Adolescent; aripiprazole; galactorrhea



4–20 ng/ml). Other biochemical and common blood tests, metabolic parameters, and brain MRI were unremarkable. The increased level of serum prolactin and galactorrhea were thought to be related to aripiprazole and we discontinued the medication. After stopping aripiprazole, galactorrhea had resolved gradually within two weeks and her prolactin level reduced to 8.25 ng/ml. We reported an adolescent female who developed an unexpected adverse effect after initiating aripiprazole and had remission after stopping the medication. The chronological sequence and dramatic response to discontinuation suggested that aripiprazole was probably responsible for hyperprolactinemic galactorrhea in our case. Aripiprazole is known as a partial agonist at dopamine D2 receptors. The functional activity of aripiprazole at D2 receptors depends on the presence or absence of dopamine in the surrounding area. Hence, it is possible that in the presence of dopamine, aripiprazole may act as a functional antagonist at D2 receptors and elevate prolactin levels. In conclusion, aripiprazole related hyperprolactinemia and galactorrhea should be kept in mind when using this medication even at low doses, especially in children and adolescents.

Abstract:0398

## Switching to Aripiprazole in Olanzapine-Induced Hyperprolactinemia: A Case Report

Bahar Yeşil

Elazığ Mental Health and Disorders Hospital, Elazığ, Turkey

E-mail address: [baharyesilege@hotmail.com](mailto:baharyesilege@hotmail.com)

### ABSTRACT

Hyperprolactinemia is a side effect associated with antipsychotics. Galactorrhea, gynecomastia, menstrual irregularities, sexual dysfunction, and osteoporosis could be results of hyperprolactinemia. Little is known about the effect of olanzapine on prolactin levels in women. We report a case with olanzapine-induced hyperprolactinemia. A 37-years-old woman who had been diagnosed with bipolar disorder for 20 years applied psychiatry clinic with excessive speech, insomnia and nervousness. She has hospitalized for one month and olanzapine 20 mg/day and valproic acid 1000 mg/day added on the treatment. 5 months later after discharge, still on olanzapine 20 mg/day, amenorrhea developed. Medical evaluation revealed an elevated serum prolactin level (53.1 ng/ml), a negative pregnancy test, normal thyroid function tests, and premenopausal levels of follicle-stimulating hormone and luteinizing hormone. Magnetic resonance imaging showed no evidence of pituitary adenoma. Olanzapine decreased to 10 mg/d and aripiprazole was added to prevent the exacerbation of psychotic and affective symptoms. One month later prolactin levels decreased to 31.7 ng/ml and patient's menstruation cycle has returned to normal. Aripiprazole increased to 20 mg/d and olanzapine treatment was discontinued. After one month, prolactin level was found 21.1 ng/ml and the patient was still in remission in terms of bipolar disorder. In this case prolactin levels returned to normal levels when olanzapine was stopped and aripiprazole added. The exact mechanism of olanzapine-induced hyperprolactinemia is not clear. It may occur due to dopamine antagonism, which is a part of the antipsychotic activity. It has been suggested that females are more sensitive to dopamine blockade in the tuberoinfundibular region of the brain. Olanzapine is an effective agent for the treatment of bipolar disorders, schizophrenia and other psychotic disorders with its low side effects. Hyperprolactinemia is an important side effect that should be considered by clinicians in the use of olanzapine.

### KEYWORDS

Hyperprolactinemia;  
amenorrhea; olanzapine;  
aripiprazole

Abstract:0413

## Management of Sexual Dysfunction Due to Paliperidone Palmitate Switching Aripiprazole Long-Acting Injectable: A Case Report

Ali Metehan Çalışkan, Ebru Çiftçi, Sehure Azra Yaşar, İkbâl İnanlı and İbrahim Eren

Department of Psychiatry, Konya Training and Research Hospital, Konya, Turkey

E-mail address: [drmete@hotmail.com](mailto:drmete@hotmail.com)

**ABSTRACT**

Sexual side effects such as reduced libido, erectile dysfunction, and retrograde ejaculation are becoming increasingly recognized as important potential side effects of the antipsychotics. Retrograde ejaculation due to potent alpha-1 adrenergic antagonism may also occur, and has been reported frequently with certain typical antipsychotics such as thioridazine, but rarely with atypical antipsychotics. Paliperidone palmitate, a palmitate ester of paliperidone, an atypical long-acting injectable antipsychotic. Paliperidone acts on dopamine D2 and serotonin 5HT2A receptors as an antagonist. It also binds and antagonizes the  $\alpha$ 1- and  $\alpha$ 2-adrenergic receptors and H1-histaminergic receptors. Mr. A 44 year-old male was on paliperidone palmitate (100 mg eq.) and valproate (1000 mg/day) treatment for schizoaffective disorder. Mr. A reported the absence of ejaculation with normal orgasm and reduced libido. On physical examination, patient showed no signs suggestive of any genitourinary lesions or malformations. He was highly distressed about this symptoms. Aripiprazole long-acting injectable (400 mg/month) was started after stopping paliperidone palmitate. He also continued to take valproate in the same dosage. On follow-up after 3 months, patient did not experience reduced libido, dry orgasms anymore. We report a case of paliperidone palmitate-induced retrograde ejaculation in a male who was being treated for schizoaffective disorder. The retrograde ejaculation following treatment with paliperidone palmitate could be postulated due to the blocking of alpha 1-adrenergic receptor. Sexual side effects could interfere with the drug compliance of patients with schizoaffective disorder but are still frequently overlooked by clinicians. Retrograde ejaculation can be due to medications, health conditions or surgeries affecting the nerves or muscles that control the bladder opening. If retrograde ejaculation is caused by a drug, stopping the drug may be an effective treatment.

**KEYWORDS**

Sexual dysfunction;  
retrograde ejaculation;  
schizoaffective disorder;  
paliperidone palmitate;  
aripiprazole long-acting  
injection

Abstract:0417

## The Neutropenia Case of After Atypical Antipsychotic Treatment

Kevsir Altıntaş, Seda Kiraz, Sencan Sertçelik and Meliha Zengin Eroğlu

Department of Psychiatry, Health Sciences University Haydarpaşa Numune Training and Research Hospital, Istanbul, Turkey

E-mail address: [kevsir-su@hotmail.com](mailto:kevsir-su@hotmail.com)

**ABSTRACT**

Clozapine from atypical antipsychotics is more effective in the treatment of schizophrenia resistant to treatment but agranulocytosis is the most important side-effect which limits its use and may be fatal. Until recently, second-generation antipsychotics were not associated with hematologic side-effects. In recent years there have been case reports showing that clozapine is similar to other second-generation antipsychotics in the literature, leading to agranulocytosis. A 68 year old, female. The patient who has been followed with schizophrenia for about 40 years has been recurrent hospitalization. Clozapine therapy was started because the patient had haloperidol, chlorpromazine, fluphenazine decanoate, frequent psychotic exacerbations and hospitalizations at the time of treatment. Approximately 7 years, with the treatment of olanzapine 25 mg/day, risperidone 6 mg/day the patient is stable. According to the information obtained from relatives, the number of leukocytes and neutrophils in hemogram follow-ups continues to decrease in this period. Patient who was stable in psychiatry was admitted to the emergency service with high fever reason. On the examinations, neutropenia and leukopenia were diagnosed and the patient was admitted to internal medicine service. The pathologic findings of the patient during hematological examinations during the hospitalization period and the reason that the hematological chart could be related to olanzapine and risperidone and the psychiatric drugs were stopped. Amisulpride gradually increased to 800 mg/day. She was admitted to our hospital due to a psychotic exacerbation under this treatment. The typical antipsychotic started, the amisulpride was stopped. During the follow-up period, the patient was discharged on improvement of the both psychotic symptoms and the improvement in the number of leukocytes and neutrophils in the hemogram. Leukopenia (white globe<3000)and neutropenia (neutrophil count<1500) have the potential to develop against almost all antipsychotics, and life can be threatening. It is recommended to change antipsychotics when severe hematologic changes are detected. In our case, neutropenia developed with the use of clozapine, olanzapine and risperidone. Our case study also supports the literature that more attention should be paid to the hematologic side effects in the use of new generation antipsychotics.

**KEYWORDS**

Clozapine; neutropenia;  
atypical antipsychotics;  
risperidone; olanzapine

Abstract:0422

## Venlafaxine-Induced Prostatism: A Case Report

Osman Bakkal, İbrahim Gündoğmuş, Özgür Maden, Ayhan Algül and Servet Ebrinç

Department of Psychiatry, Haydarpasa Sultan Abdulhamid Training and Research Hospital, Istanbul, Turkey

E-mail address: [drbakkalosman@gmail.com](mailto:drbakkalosman@gmail.com)

### ABSTRACT

Prostatism which impairs quality of life is an important medical condition, with clinical and social implications. Prostatism is a disorder that appear due to an obstruction in the urethra or pressure on the urethra; the most common cause is hyperplasia of prostate. Forced urination, diminished urine caliber, disrupted urine projection, the need to wait before starting urination, dripping at the end of urination, sensation of incomplete emptying of the bladder, and rarely urinary retention are some primary findings. Male with prostatism symptoms are very common, have a multifactorial etiology and with an ageing population, are likely to increase. Venlafaxine, is selective serotonin-norepinephrine reuptake inhibitors are often used for a number of psychiatric-related conditions such as the treatment of major depression, generalized anxiety disorder, social anxiety disorder, and panic disorder. Venlafaxine which is generally well tolerated, safe and effective is a widely used second generation antidepressant. Including nausea, vomiting, decreased appetite, diarrhea, dry mouth, constipation, somnolence, and increased of liver enzymes are some possible side effect of venlafaxine. In spite of side effects associated with different systems have been reported, prostatism has not been previously reported. Prostatism associated with venlafaxine has not been previously described in any clinical study. Duloxetine, milnacipran and reboxetine that are effective through the noradrenaline mechanism, have been reported that those are related with prostatism but has not been reported with serotonin re-uptake inhibitors. We herein present a case of reversible prostatism that developed in a 49 year-old male patient with major depressive disorder on venlafaxine. As far as we know this is the first report of venlafaxine-induced prostatism.

### KEYWORDS

Venlafaxine; prostatism; side effect

Abstract:0423

## Duloxetine-Induced Hyperhidrosis: Two Case Reports

Abdullah Atli<sup>a</sup>, Aslıhan Okan İbiloğlu<sup>a</sup> and Mehmet Asoğlu<sup>b</sup>

<sup>a</sup>Department of Psychiatry, Dicle University, Diyarbakır, Turkey; <sup>b</sup>Department of Psychiatry, Harran University, Sanlıurfa, Turkey

E-mail address: [mehmetasoglu@gmail.com](mailto:mehmetasoglu@gmail.com)

### ABSTRACT

Duloxetine is used for treating depression. The most common side effects of duloxetine are nausea, dry mouth, constipation, drowsiness, difficulty sleeping, loss of appetite, and dizziness. On the other hand, according to some studies in literature, rare side effects of duloxetine are hypertension, delirium and galactorrhea. In this report we present two cases with hyperhidrosis during duloxetine therapy.

Case 1: A 22-year-old male, who presented to our psychiatry outpatient with complaint of anhedonia, insomnia, restlessness, attention disorder, and depressive symptoms. He was diagnosed as depression. We have initiated to duloxetine 60 mg/day. Fifteen days after initiation, his depressive symptoms and sleep was better. But, he was started to complain hyperhidrosis particularly his face and underarm region. Due to the patient's preferences, treatment was continued in the same way. Around 14 months after treatment with duloxetine was completely improved of depressive symptoms. Therefore, treatment was terminated. Approximately three weeks after duloxetine was discontinued, there was improvement in his complaint of sweating.

Case 2: A 34-year-old woman, who presented to our psychiatry outpatient with complaint of fatigue, loss of appetite, anhedonia, restlessness and insomnia. She was diagnosed as depression. After then, we have initiated to duloxetine 60 mg/day. Two weeks after initiation, she was started to complain of gradually increased sweating of her whole body. She complained that the hyperhidrosis had severely deteriorated of her quality of life. Therefore, her treatment was changed to mirtazapine 30 mg/day. Approximately two weeks after duloxetine was discontinued, there was improvement in her complaint of sweating. Hyperhidrosis associated with duloxetine may be a symptom of serotonin syndrome or drug withdrawal. Because of the absence of other signs of serotonin syndrome, we gave up this opinion. Based on the above-mentioned, it should be considered that the cause of the hyperhidrosis is duloxetine.

### KEYWORDS

Duloxetine; hyperhidrosis; side effect

Abstract:0429

## Milnacipran-Induced Spontaneous Erection

Selma Hilal Avcı, Aynur Görmez, Can Tuncer and Volkan Seneger

Department of Psychiatry, Istanbul Medeniyet University, Istanbul, Turkey

E-mail address: [hilalselma@gmail.com](mailto:hilalselma@gmail.com)

### ABSTRACT

Sexual dysfunction is common symptom of depression also a frequent adverse effect of treatment with most antidepressants and is one of the predominant reasons for premature drug discontinuation. Selective serotonin reuptake inhibitors are the most widely prescribed antidepressants and have significant effects on arousal and orgasm compared with antidepressants that target norepinephrine, dopamine, and melatonin systems. We present a case of milnacipran-induced erectile dysfunction. A 48 year old male who had been suffering from depression and anxiety, was on paroxetine 20 mg and mirtazapine 15 mg for 4 years. When he consulted us due to ongoing symptoms, he was switched to sertraline, mirtazapine dose was increased but his depressive symptoms persisted. Due to insufficient response to treatment and decrease of his libido, he was switched to milnacipran 25 mg/day. The day after starting milnacipran, he reported he had spontaneous erection all day. He was obviously ashamed of this situation and he was covering his front with a bag when he came to outpatient clinic the following day. Milnacipran was stopped and he was switched to sertraline again and erectile dysfunction resolved within a day. But lack of sexual desire was still a problem and this led to his disengagement from psychiatric services. Milnacipran is a dual action antidepressant with a balanced inhibition of the reuptake of serotonin and noradrenaline. In the literature there are inconsistent results about sexual dysfunction effect of milnacipran; however in some cases Milnacipran appears to have positive effects on sexual function together with improvement in depression. On the other hand there are cases involving spontaneous ejaculation by milnacipran. In our case it caused long lasting spontaneous erection that wasn't mentioned in the literature before. Individual vulnerabilities to such unwanted effects should be considered and sexual dysfunction should be assessed thoroughly during the treatment.

### KEYWORDS

Spontaneous erection;  
milnacipran; side effect

Abstract:0432

## Aripiprazole-Induced Sialorrhea Responsive to Amitriptyline Treatment

İbrahim Gündoğmuş, Mustafa İspir, Özgür Maden, Ayhan Algül and Servet Ebrinç

Department of Psychiatry, Haydarpasa Sultan Abdulhamid Training and Research Hospital, Istanbul, Turkey

E-mail address: [dribrahim06@gmail.com](mailto:dribrahim06@gmail.com)

### ABSTRACT

Sialorrhea is a frequent, unbearable, disturbing and persistent adverse effect of antipsychotics, especially related with clozapine, risperidone, olanzapine. This is known dose related adverse effect. This condition may be particularly socially stigmatizing and troubling for patients, resulting in treatment nonadherence or discontinuation. Sialorrhea may emerge all day however its frequency and amount that is inversely proportional with ability to swallow, increases during sleep time. The patients frequently complain of awakening with a "wet pillow". Aripiprazole which is a relatively new atypical antipsychotic used in the treatment of schizophrenia, depression, bipolar disorder, tic disorders, irritability, impulsivity and obsessive-compulsive disorder. This safe and tolerable profile of aripiprazole is not valid for every side effect as sialorrhea and akathisia. We herein present a case of reversible sialorrhea that developed in a male patient with first episode psychotic attack on aripiprazole-induced sialorrhea responsive to amitriptyline. In this report, we presented a case of sialorrhea during aripiprazole treatment and remitted amitriptyline treatment in a patient who suffered from first attack psychosis. Because of the temporal relationship between the onset of sialorrhea and use of aripiprazole, it is thought that the sialorrhea might be associated with aripiprazole. In the literature, there are two reported case, 27 year-old male patient with aripiprazole-induced sialorrhea responsive to diphenhydramine and 14 year-old boy with aripiprazole-induced sialorrhea responsive to trihexyphenidyl. As far as we know, this is the first case of patient with aripiprazole-induced sialorrhea responsive to amitriptyline treatment. In conclusion, it is important to be aware of the possibility of a sialorrhea being induced when starting aripiprazole therapy. Amitriptyline may be a therapeutic option for patients with aripiprazole-induced sialorrhea. We believe that these case reports serve as a base for future research to examine the relationship between using aripiprazole, onset of sialorrhea, and treatment response.

### KEYWORDS

Amitriptyline; aripiprazole;  
sialorrhea; side effect

Abstract:0455

## Maintenance Electroconvulsive therapy in Three Cases

Kevser Altıntaş, Alişan Burak Yaşar and Sencan Sertçelik

Department of Psychiatry, Health Sciences University Haydarpaşa Numune Training and Research Hospital, Istanbul, Turkey

E-mail address: [kevser-su@hotmail.com](mailto:kevser-su@hotmail.com)

### ABSTRACT

ECT is potent and reliable treatment option on the patients who are acute depression, bipolar disorder, and refractory schizophrenia. CT is a suggested method for acute treatment as well as recurrence and prevention from exacerbation. As a result it is shown by the studies that maintenance ECT can be a treatment method alone or with drugs for the continuity of remission in the treatment.

Case1: A 46 years old female patient. In care of schizophrenia with recurrence hospitalization, benefit from acute ECT in exacerbation period. During her hospitalization after acute ECT she was planned maintenance ECT in addition to her medical treatment. Nearly 7 months along 9 sessions had been applied to the patient and she did not have any exacerbation. When she left her maintenance ECT sessions she got exacerbation and hospitalized.

Case2: A 37 years old female patient. She has nearly been followed by the disorder of major depression. She has 4 in average depressive attacks in a year. She has epicenter depressive episode diagnosis and she has repeating admissions to hospital. During her hospitalization she was planned acute ECT in addition to her medical treatment. Her acute ECT treatment finished at the 7 session. Maintenance ECT was planned in addition to her medical treatment. 7 sessions maintenance ECT applied. During sessions she did not have any exacerbation.

Case 3: A 37 years old male patient. He has bipolar disorder nearly 12 years. He has depressive attacks for a month in average in a year. He got admission to hospital with the diagnosis of bipolar disorder-depressive episode. He had 7 sessions acute ECT during hospitalization. Clinical recovery was observed. Therefore maintenance ECT was planned in addition to his medical treatment. Nine sessions maintenance ECT was applied. During sessions she did not have any depressive or manic episodes. Maintenance ECT efficiency is a proven treatment method. However it is not used frequently. Our study and reference studies demonstrated that maintenance ECT is an efficient treatment method. The common result that when maintenance ECT applied, the increase on period of remission of case studies shows the efficiency of maintenance ECT.

### KEYWORDS

Electroconvulsive therapy; maintenance; mood disorders; schizophrenia

Abstract:0264

## Transgenerational Effects of Attachment and Separation

Can Tuncer, Burcu Bakar, Hasan Turan Karatepe and Rûmeysa Yeni Elbay

Department of Psychiatry, Istanbul Medeniyet University, Istanbul, Turkey

E-mail address: [drctuncer@gmail.com](mailto:drctuncer@gmail.com)

### ABSTRACT

The concept of separation in early psychological development and its impact in children's mental health and further implications in adult psychiatric clinical area is well known. The role of attachment in child's early life has enormous effects in development of child's trust and confidence. Winnicott's model of 'two mothers' such as 'environment mother' and 'object mother' is very much instrumental shedding light on pathological effects of attachment in psychiatric disorder. In order to illustrate the pathologic effects of attachment in mothers role and the imposed transgenerational effects on the mother and child in separation anxiety, the following case history will be discussed. An eight year old girl, presented with the symptoms of fear, anxiety, reluctant to be alone, not want to sleep by herself, not want to leave her mother, apprehensive about something bad will happen to herself or to her mother. One of the authors has assessed her mother as well. The family dynamics included mother been very protective and the grandmother also being described as protective to the extent of "guardian angels". These dynamics are essential in highlighting their role in separation anxiety. Awareness of these family dynamics including the pathological effects of attachment difficulties caused by mother and child interaction, even the transgenerational ones are essential in providing high quality psychotherapy to these patients.

### KEYWORDS

Anxiety; attachment; fear; mother; separation; transgenerational

Abstract:0145

## Gender Dysphoria and Eating Disorder Comorbidity: A Case Report

Melike Dönmez, Volkan Topçuoğlu and Ömer Yanartaş

Department of Psychiatry, Marmara University, Istanbul, Turkey

E-mail address: [melikeduran@gmail.com](mailto:melikeduran@gmail.com)

### ABSTRACT

Patients with gender dysphoria (GD) are thought to have increased risk of eating disorders (ED). They are prone to body dissatisfaction and pathological eating behaviors. Some case reports have been reported related to the comorbidity of GD and ED. A 20 year-old male patient presented to the outpatient clinic due to the sex reassignment surgery. Patient's cachectic appearance was remarkable and body mass index was calculated as 14.9. After the first assessment; the patient was consulted to the internal medicine and dietitian for further evaluation. There was not determined any pathological findings in his examination. In his past history; he found thin women more feminine and he was not satisfied with his appearance, he decided to make diet and getting thinner after high school. In the follow-up period, there was an imbalance in eating attitude. The patient had binge eating periods for 3-4 weeks, then he got dissatisfied and restricted food. Body mass index has never been low similar to first assessment but increase and decrease in weight were noteworthy. Patient was diagnosed as eating disorder not otherwise specified due to the both anorexic (i.e., loss of body weight) and binge eating components (i.e., binge eating periods). And also fluoxetine was given due to the depressive symptoms such as; anhedonia, loss of interest, sadness. Both psycho-therapeutic approach and antidepressant agents were useful for eating attitudes and depressive symptoms. Also patient's awareness that eating disorders may interfere with hormone therapy planned to be taken has played a role in his treatment. In his control assessment body mass index was determined as 19. ED may be an important issue for the patients with GD. Thus clinicians should assess these patients in terms of eating attitudes. In order to understand the relationship between ED and GD comorbidity, follow up studies are needed.

### KEYWORDS

Eating disorder; gender dysphoria; transgenderism

Abstract:0186

## An Adolescent with Anorexia Nervosa who Rapidly and Effectively Responded to Fluoxetine Pharmacotherapy: A Case Report

Merve Sertdemir and Ayhan Bilgiç

Department of Child and Adolescent Psychiatry, Meram School of Medicine, Necmettin Erbakan University, Konya

E-mail address: [drcuramerve@gmail.com](mailto:drcuramerve@gmail.com)

### ABSTRACT

Anorexia Nervosa (AN) is characterized by a restrictive eating pattern that causes severe weight loss, amenorrhea, and disrupted perceptions of body weight and shape. This disorder more often have onset in adolescence, causing significant medical and psychiatric conditions. Evidence-supported pharmacological treatment for children and adolescents with eating disorders is not yet adequate. Nevertheless studies with adults reported that SSRIs are low efficacy in acute undernourished cases but effective in preventing relapse. The following case report describes an efficient response to pharmacotherapy with fluoxetine as early as 10 weeks in the treatment of an adolescent with AN. A 16 year-old girl presented to our clinic with complaint of weight loss and unhappiness. She was 39 kilograms and her BMI was 16. She lost 14 kilograms weight over the preceding 12 months, missed her last three menses, and was afraid of gaining weight. She diagnosed as AN and major depression. We started fluoxetine 20 mg/day and patient demonstrated remarkable improvement in depression, irritability, weight loss, distorted body image within four weeks. Her menses returned at the 6th weeks of treatment. She steadily gained weight and returned to her previous weight within 10 weeks. This case illustrates usefulness of fluoxetine in AN coexistence with major depression. The relationship between affective disorders and AN is not well-known. Though pharmacological treatments for children and adolescents with eating disorders are not yet supported with sufficient evidence, this case suggests that fluoxetine may show rapid effect on AN at least when this disorder co-occur with depression.

### KEYWORDS

Anorexia nervosa; adolescent; psychopharmacologic treatments; fluoxetine



Abstract:0323

## Pica Syndrome After Major Depressive Disorder in an Adolescent: A Case Report

Hicran Doğru<sup>a</sup> and Volkan Doğru<sup>b</sup>

<sup>a</sup>Department of Child and Adolescent Psychiatry, Erzurum Regional Training and Research Hospital, Erzurum, Turkey; <sup>b</sup>Department of general surgery, Palandöken State Hospital, Erzurum, Turkey

E-mail address: [hicran\\_ktekin@yahoo.com](mailto:hicran_ktekin@yahoo.com)

### ABSTRACT

Pica syndrome is the persistent and compulsive ingestion of non-nutritive substances for a period of at least one month. A bezoar can occur after ingestion of indigestible foreign substances. Patients eating indigestible foreign substances usually do not notice any difficulty in the gastrointestinal passage. However, persistent intake may alter normal anatomy and physiology each of which may trigger obstruction. Most commonly consumed substances are ice chips, sand, clay, hair and bristles, cloth, lime, paper, rubber, foam, gum, cork, plastic, wax crayon, toilet paper, sponge, sunflower seed. Risk of pica is reported higher particularly in preadolescents, pregnancy, mental retardation, obsessive-compulsive disorder and psychosis. Besides a possible association between pica and vitamin deficiencies is demonstrated in literature, although conversely almost every eating disorder would likely to contribute to such a positive feedback in vitamin imbalance. To this end, it should be aimed to establish a multidisciplinary treatment program to remove the underlying cause of this disease. For the purpose of eliminating the factors behind this condition, we believe characterization of serotonin pathways and dopaminergic neuronal firing is of great importance given that like many pleasurable behaviors eating triggers the release of dopamine.

### KEYWORDS

Depression; gastritis; pica

Abstract:0436

## Anorexia Nervosa Case Following Corticosteroid Treatment

Abdullah Bozkurt, Berkan Şahin and Koray Karabekiroğlu

Department of Child and Adolescent Psychiatry, Ondokuz Mayıs University, Samsun

E-mail address: [abdullahbozkurt87@hotmail.com](mailto:abdullahbozkurt87@hotmail.com)

### ABSTRACT

Psychiatric symptoms that may occur during the use of corticosteroid medication can occur at any time, including the beginning of treatment. Although the most common symptom of euphoria is seen after corticosteroid treatment, the duration of treatment and the depressive complaints are more prominent. Severe depression, mania and psychotic illnesses, suicidal tendencies can also be seen. Anorexia Nervosa (AN), which is associated with comorbid psychopathology after cortisol treatment due to chronic multifocal osteomyelitis diagnosis, is discussed. A 12 year-old girl was diagnosed with chronic multifocal osteomyelitis 1 year ago as a result of patient research with vertebra sagging fracture. He's been using 45 mg cortisol for 2.5 months. Patient whose appetite was normal up to 2 months had a total weight of 6 kg in the last 2 months (body mass index: 16.6). Before starting cortisol, you should be informed that you can 'gain weight' and then fear to lose weight, constantly wearing it, reducing the amount of appetite and food. He always thought his cheeks were fat. After receiving history and mental evaluation, the patient was diagnosed with Depressive Disorder and AN. It has been determined that there is a relationship between the severity of the disease and increased HPA activity and high serum cortisol levels in anorexia cases. Contradictory to this knowledge, there are case reports that the use of high-dose corticosteroids improves AN. In our case, AN clinic developed by comorbid psychopathology accompanied by corticosteroid use for 2 months. It was thought that after the patient had an excessive weight gain after corticosteroid treatment, the patient had been consciously reduced nutrition and developed AN clinic. Rarely emerging AN disease after corticosteroid treatment has made the case interesting.

### KEYWORDS

Anorexia nervosa; corticosteroid; child

Abstract:0168

## Trichotillomania in a Child with Celiac Disease: Irrespective of Iron Deficiency Anemia

Tuğba Kalyoncu and Deniz Argüz Çıldır

Izmir Tepecik Training and Research Hospital, Izmir, Turkey

E-mail address: [tugbadonuk@gmail.com](mailto:tugbadonuk@gmail.com)

### ABSTRACT

Trichotillomania is characterized by recurrent hair pulling behavior and repeated attempts to decrease or stop the behavior. It may result for a trichobezoar in which is a mass of hair found in the stomach, and patients with diagnosed celiac disease may have an urge to swallow their hair due to iron or folate deficiency, which is called pica. We aimed to present a female child referred with an abdominal mass and anemia, diagnosed with trichotillomania and celiac disease and developing trichobezoar irrelevant to iron deficiency and pica. An 11-year-old female child, who diagnosed with celiac disease 4 years ago and had symptoms like digestive problems, iron deficiency anemia, and diarrhea. After a while, she applied with complaints of an uncontrollable, irresistible, and repetitive urge to pull and to swallow her scalp hair. However, her hair pulling and swallowing behaviors have been related to iron deficiency and pica. Although supplementary iron and a gluten-free diet have been instituted, her symptoms have not been decreased and she diagnosed with trichobezoar in her stomach after 2 years. During her pre-op assessment, she was consulted to child psychiatry and her trichotillomania symptoms were associated with as a psychiatric disorders secondary to celiac disease. Her course of illness, diagnostic procedure, and post-op treatment history are described. The connection between celiac disease and an trichotillomania has not explained clearly, yet. In this case, trichotillomania was more likely caused by behavioral disorders secondary to celiac disease rather than caused by the iron deficiency. We attempted to emphasize the importance of psychiatric and comprehensive approaches in patients with celiac disease.

### KEYWORDS

Celiac disease; child; trichobezoar; trichotillomania

Abstract:0393

## Modified-Release Methylphenidate Related Trichotillomania in a Boy with Autism Spectrum Disorder

Serkan Güneş

Department of Child and Adolescent Psychiatry, Hatay State Hospital, Hatay, Turkey

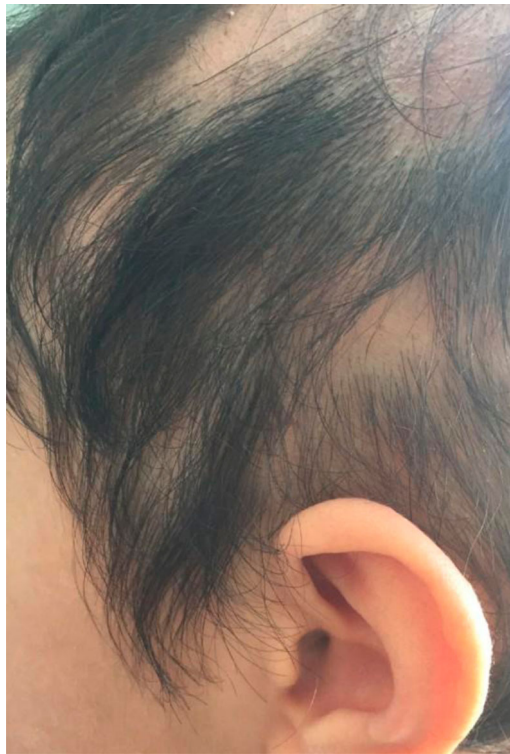E-mail address: [dr\\_sgunes@hotmail.com](mailto:dr_sgunes@hotmail.com)

### ABSTRACT

Trichotillomania (TTM) is a disorder characterized by recurrent hair pulling, generally from the scalp. Methylphenidate (MPH) is a well-accepted treatment for attention-deficit/hyperactivity disorder (ADHD) in children and adolescents. In this paper, we report the occurrence of TTM with modified-release MPH use in a boy with autism spectrum disorder (ASD). Our patient was an eight-year-old boy who was referred to our clinic with the complaint of hyperactivity, anger bursts, and irritability. As a result of his psychiatric and psychometric examinations (CARS total score=45), he was diagnosed with ASD and ADHD and initiated modified-release MPH 20 mg/day. One month after, the second examination revealed that his symptoms improved partially, but he started to pull his scalp hair in the left temporoparietal region (Fig. 1). Metabolic parameters, common blood and biochemical tests were normal. So, we ceased MPH and his hair pulling stopped after discontinuation. Two weeks later, we restarted modified-release MPH 10 mg/day to know whether TTM was associated with MPH or not, and we saw that TTM reemerged within the first week of the medication. We reported a case who developed TTM after initiating MPH and had remission after stopping the medication. The chronological sequence and dramatic response to discontinuation of the medication suggested that MPH was probably responsible for TTM, which was seen in our case. Although not clearly identified, serotonergic, dopaminergic, and noradrenergic dysfunctions are implicated in the pathophysiology of TTM. It is known that stimulants have facilitative effects on serotonin, dopamine, and noradrenaline neurotransmission. Increased serotonergic, dopaminergic, and/or noradrenergic activity with MPH may be related with the emergence of TMM in our case. The use of MPH has become widely common in children and adolescent for treating ADHD. Thus, MPH related TTM should be kept in mind when using this medication.

### KEYWORDS

Autism; methylphenidate; trichotillomania



**Figure 1.** The patient's left temporoparietal region, one month after starting methylphenidate.

Abstract:0125

## Paroxetine Use in an Autistic Adolescent who Had Inappropriate Sexual Behaviors: A Case Report

Cansu Çobanoğlu, Mahmut Müjdeci, Berkan Şahin and Yusuf Yasin Gümüş

Department of Child and Adolescent Psychiatry, Ondokuz Mayıs University, Samsun, Turkey

E-mail address: [drcansucobanoglu@hotmail.com](mailto:drcansucobanoglu@hotmail.com)

### ABSTRACT

Autism Spectrum Disorder (ASD) is defined as a neurodevelopmental disorder characterized by repetitive and stereotypic behaviors and inability in communication and social interaction. Inappropriate sexual behaviors (ISB) such as public masturbation and impulsive-compulsive sexual behaviors can be seen in ASD and they impair functioning. The purpose of this case study was to research the efficiency of paroxetine for ISB in our patient who had ASD, ADHD and childhood obesity. A 14-year old male patient was first admitted to OMU, Child and Adolescent Psychiatry Polyclinic in June 2006 with a complaint of not being able to talk and he was referred to special education with a diagnosis of autism. Risperidone 0.25 mg/day was started for the patient's stereotype and irritability and it was increased to 1 mg/day in follow-ups. With the continuation of weight gain, risperidone was cut down and stopped and instead aripiprazole was started. The treatment was regulated as methylphenidate 90 mg/day, aripiprazole 10 mg/day, haloperidol 20 drops/day. The patient's height was 185 cm, while his weight was 120 kg ( $p > 95\%$ ). It was learned that during the 6 months, there were complaints as playing with his penis in public and rubbing against objects. Paroxetine 5 mg/day was started and it was increased up to 10 mg/day a week later. 6 weeks after the treatment was started, it was learned that there was an obvious decrease in ISB and an increase in appetite with no weight gain. ISB can be an important problem that causes impairment in the patient's functionality in psychiatric diseases such as mental retardation and ASD. Case reports about paroxetine have reported paroxetine to be effective in irritability, destructive behaviors and ISB in autistic individuals. Since ISB had decreased and no obvious weight gain was observed within 6 weeks after paroxetine use in our patient, it can be said that paroxetine use can be a good choice of therapy in obese ASD adolescents who have ISB when compared with drugs that cause weight gain.

### KEYWORDS

Autistic disorder;  
inappropriate sexual  
behaviors; paroxetine

Abstract:0173

## Autism Spectrum Disorder Symptoms in a Child with Pena–Shokeir Syndrome

Merve Kalınlı, Özalp Ekinçi and Serkan Güneş

Department of Child and Adolescent Psychiatry, Mersin University School of Medicine, Mersin, Turkey

E-mail address: [mervekalinli@yahoo.com](mailto:mervekalinli@yahoo.com)

### ABSTRACT

Pena-Shokeir Syndrome (PSS) is a rare and early lethal disease characterized by fetal growth restriction, craniofacial deformities, multiple ankyloses and pulmonary hypoplasia. Our case report describes a child with PSS who presented with autistic spectrum disorder (ASD) symptoms. A four and a half years-old male boy was referred to our clinic for psychiatric evaluation. The patient's external phenotypic features included malrotated low-set ears, a centrally high and arched palate, a short neck, and a long philtrum, bilateral calcaneovalgus deformity of the feet and bilateral camptodactyly of fingers. A clinical geneticist was consulted and agreed with a diagnosis of fetal dyskinesia syndrome, consistent with Pena-Shokeir syndrome type II. In his psychiatric examination, the following autistic-like traits were observed: No eye contact, rarely responding to his name, insufficient response to social interactions, difficulty understanding jokes and other's feelings. Parents reported he had no sense of danger, unusually low pain tolerance and hypersensitivity to unexpected noise. At the time of the examination, he had no meaningful words and marked difficulty understanding simple comments. The CARS was applied and the total score was 58 (corresponds to "severely autistic"). The ABC was applied and the total score was 75 (corresponds to "high probability of autism"). With the diagnosis of severe developmental delay and ASD, patient was referred for special education. Since infants with PSS do not survive to toddler years in great majority of the cases, the neuro-psychiatric features of PSS are largely unknown. To our knowledge, the present case is the first to report autistic-like traits in a patient with PSS type II. The underlying central nervous system dysfunction of PSS characterized by neuron loss may be responsible for ASD traits in our patient. Studies with large sample size are needed to prove the relationship between the PSS and ASD.

### KEYWORDS

Pena-Shokeir Syndrome;  
autistic spectrum disorder;  
child

Abstract:0180

## Treatment of Food Refusal Related to Stereotypic Behaviors in a Child with Autism Spectrum Disorder

Betül Akbaş and Ömer Faruk Akça

Department of The Child and Adolescent Psychiatry, Necmettin Erbakan University Meram School of Medicine, Konya, Turkey

E-mail address: [betullakbas@gmail.com](mailto:betullakbas@gmail.com)

### ABSTRACT

Autism spectrum disorder (ASD) is a neurodevelopmental disorder characterized by impairments in social communication and repetitive patterns of behavior. Comorbid problems are common in children with ASD. Feeding problems like mealtime behavioral problems, food refusal and food selectivity with preference for specific texture or smell has been detected in 90% of children with ASD. Feeding problems have been associated with aggression, externalizing and internalizing behaviors, repetitive behaviors and sensory reactivity. This report includes the medical treatment procedure of a case with food intake restriction and eating refusal due to stereotypic behaviors. An 11 year-old nonverbal boy with ASD admitted to our outpatient service with complaints refusing to eat or drink any foods or drinks, irritability, aggression, self-mutilation, and sleep disturbance. His mother reported that because of stereotypic behaviors and voices related to feeding procedure, he refuses eating or drinking any foods during previous 12 days. Also, he was reported to have difficulty in sleeping because of stereotypic movements and voices. Aripiprazole 5 mg/day and Mirtazapine 15 mg/day medications was started targeting his stereotypic, self-mutilation and aggressive behaviors, in addition to sleep and food intake problems. After starting the medication, the patient's aggression, irritability, sleep problems and stereotypic behaviors decreased gradually within 4 weeks and he began to eat and drink. He had no problems related to eating, sleeping or behavioral issues during 2 months of follow up. Treatment strategies for eating problems in patients with ASD are not well known. Treating these patients is a difficult process especially if the eating problem is related to stereotypic movements or restrictive behavioral patterns. Aripiprazole and Mirtazapine may be helpful in treatment of this kind of patients.

### KEYWORDS

Aripiprazole; autism;  
mirtazapine; stereotypic  
behaviors

Abstract:0301

## Dose-Dependent Headache Due to Atomoxetine Treatment in a Patient with Autism: A Case Report

Hicran Dođru

Department of Child and Adolescent Psychiatry, Erzurum Regional Training and Research Hospital, Erzurum, Turkey

E-mail address: [hicran\\_ktekin@yahoo.com](mailto:hicran_ktekin@yahoo.com)

### ABSTRACT

ASD is a group of complex neurological disorders. These disorders affect behavior, development and communication. With the release of the Diagnostic and Statistical Manual of Mental Disorders, The American Psychiatric Association states that the two conditions can occur together. In a review of studies looking at the comorbidity of ADHD and ASD, researchers found that between 30 to 50 percent of people with ADHD also have symptoms of ASD. Pharmacotherapy of ADHD symptoms in ASDs is often problematic, with unexpected responses, generally poorer tolerability, and less impressive average benefit. In such cases atomoxetine treatment is considered safer. Atomoxetine is a non-stimulant ADHD treatment that increases norepinephrine levels in the presynaptic cleft by blocking the action of the norepinephrine transporter. A 13 years-old boy presented to our clinic with lack of concentration, over activity and getting bored, losing his stuff, lack of concern or inability to react to other people's emotions or feelings, repetitive movement, such as twisting, bothering his class mates during lectures, not completing his homework and tasks, and forgetfulness complaints. Symptoms started at pre-school period and increased with time, especially during school time. Even though many ASD related studies emphasize a better tolerability for atomoxetine than methylphenidate. The neurodevelopmental structure in individuals with autism might be more fragile than pure ADHD patients and might have different sensitivity to drugs. Autism and ADHD are neurodevelopmental diseases. Especially in cases of these diseases seen as comorbid forms the drug dose should be titrated more slowly than usual. Otherwise, drug related side effects might appear much easier. The resulting side effects such as headache might be dose dependent and can regress with reducing the dose again.

### KEYWORDS

ADHD; atomoxetine; autism spectrum disorders

Abstract:0377

## Autism Spectrum Disorder with Bipolar Disorder in an Adolescent: A Case Report

Feyza Hatice Sevgen and Hatice Altun

Department of Child and Adolescent Psychiatry, Sütçü İmam University, Kahramanmaraş, Turkey

E-mail address: [feyzasevgen@gmail.com](mailto:feyzasevgen@gmail.com)

### ABSTRACT

In studies, prevalence of psychiatric comorbidity was found to be higher in patients with autism spectrum disorder (ASD). The rate of association of ASD and bipolar disorder (BAD) was reported to be 0.7–27%. Here, we will discuss association of BAD in a patient with ASD. A 16 years-old boy with ASD presented to outpatient clinic with irritability, harm to objects, violence to others, marked decrease in sleep, increased activity and incomppliance to special education by parents. The patient was using risperidone and aripiprazole over one year but had no improvement; thus, the drugs were tapered while quetiapine and lorazepam were prescribed to the patient. As the patient had no benefit from these drugs given at appropriate dose and duration, a detailed assessment was performed. In the detailed assessment, it was found out that the patient had same complaints four times within prior year; that complaints lasted about 10 days in each episode and responded to risperidone and aripiprazole; that complaints were prolonged in this episode for the first time and more devastating. Screening for organic disorders was reported as normal. BAD was considered in the patient due to above-mentioned episodes within prior year. Valproate was initiated and marked improvement was observed in the patient in control visit one week later. In ASD, the clinical presentation of mania include increased speech and activity, incomppliance to therapy, cheerful appearance, hostile attitude, devastating behavior and aggressiveness, irritability, elevated mood, psychotic symptoms, grandiosity and sexual acts and speech. In ASD, sleep disorder, anger, increased activity and decreased skills can be symptoms of distinct

### KEYWORDS

Autism; bipolar disorder; adolescent; valproate



psychiatric comorbidities such as depression, anxiety disorder, behavior disorder or BAD. Limited verbal skills and the fact that some symptoms can also be observed in the normal course of ASD make it difficult to diagnose and treat a new psychopathology added to ASD. In particular, association of ASD and BAD is not retained by clinicians. In patients with ASD, identifying comorbid conditions is important regarding both quality of life and compliance to education programs. Thus, clinicians should be alert about comorbid diagnosis.

Abstract:0399

## Evaluation of Shared Psychotic Disorder During Forensic Psychiatric Process: A Case Report

Hasan Mervan Aytaç and Fatih Öncü

Department of Psychiatry, Bakırköy Prof. Dr. Mazhar Osman Mental Health and Neurological Diseases Training and Research Hospital, Istanbul, Turkey

E-mail address: [mervan176@hotmail.com](mailto:mervan176@hotmail.com)

### ABSTRACT

Unusual condition has also been called folie à deux and induced or shared psychotic disorder. It develops in an individual in the context of a close relationship with another person who has an established delusion that he or she also believes, and requires an absence of psychotic disorder prior to the onset of the induced delusion. A 58 year-old man and mechanical engineer. His wife is 44 years old, graduated from high school, two children's mother. Due to crime about "disturbing individuals' peace and harmony" that committed in September 2016, they were brought with the police in order to determine the criminal responsibility with the writing of the chief prosecutor of the republic. Patient. Felt that they had been disturbed by their downstairs neighbor for 5 years. He believed their neighbor wanted to influence themselves with telepathic and hypnotic methods. Patient thought that his neighbor could spread electromagnetic waves that were intelligence-linked and could enter into their subconscious minds, thus changing their decisions. His wife who had been admitted to female inpatient clinic at same time, like her husband she had thought that their neighbors would harass them by affecting them with electric waves and force them to take the house from their hands, their phones are listening too so they had to pay a high price bills. According to their evaluations in health council, they were affected by the illness called "Atypical Psychosis" during the crime and they could not perceive the legal meanings and consequences of acts they committed and their ability to direct their behaviors significantly decreased. A report about failure of their parental duties was also wrote and sent to society for protection of children. Although rare, shared psychotic disorder cases will continue to challenge our understanding of psychiatric phenomenology. In forensic pretrial settings, this challenge is multiplied because psychiatric experts must be able to explain this complex disorder to the judge who are most often non-medically trained people.

### KEYWORDS

Shared psychotic disorder; forensic psychiatry; crime

Abstract:0415

## Incest Involving a Grandmother with Dementia: A Case Report

Nilfer Şahin and Damla Balkan

Department of Child and Adolescent Psychiatry, Muğla Sıtkı Koçman University School of Medicine, Muğla, Turkey

E-mail address: [nilfersahin@hotmail.com](mailto:nilfersahin@hotmail.com)

### ABSTRACT

Dementia is a clinical entity associated with loss of acquired intellectual functions, which is general progressive and persistent. Problems in memory, attention and perception, mood and thought disorders, decreased self-care, alteration in personality and socially inappropriate behaviors can be seen in patient with dementia. Here, we presented a sexual abuse case of grandmother with dementia-grandson incest. A 12 year-old boy presented to outpatient clinic with his mother. Twenty days ago, the patient told to his mother that his grandmother asked him "Do you have erection"; thus, he went to the other room but his grandmother followed him and he slept with grandmother and was abused by his grandmother. The patient could not forget this experience, was feeling guilty and was seeing it in his dreams. He was more aggressive and impulsive in the school. In the psychological

### KEYWORDS

Dementia; incest; posttraumatic stress disorder



assessment, he was conscious, oriented and had depressive mood with thoughts about his experience. Based on history and clinical assessment, the patient was diagnosed as posttraumatic stress disorder. Fluoxetine (20 mg/day) and Risperidone (0.5 mg/day) was prescribed to the patient. Since the grandmother was HCV positive, the patient was referred to pediatrics department. Childhood abuse and neglect is an important, frequently seen problem that may recur and results in several physical and psychological disorders or even mortality. A child can be subjected to abuse by caregiver, relatives or unfamiliar persons. Given the family structure and culture in our society, elder individuals with several disorders and children commonly share same environment. Neglect and abuse are important social problems and the most important issue is early recognition and protection. Elder individuals and children comprise two major, featured groups regarding abuse and neglect. In particular, clinicians providing care to these groups should have to assess their patients for abuse and neglect.

Abstract:0045

## The Effect of Fluoxetine on Foreign Accent Syndrome Associated with Conversion Disorder in an Adolescent: A Case Report

Fatma Coşkun, Savaş Yılmaz and Ömer Faruk Akça

Department of Child and Adolescent Psychiatry, Necmettin Erbakan University, Meram School of Medicine, Konya, Turkey

E-mail address: [drfcoskun@hotmail.com](mailto:drfcoskun@hotmail.com)

### ABSTRACT

Foreign Accent Syndrome (FAS) is a rare speech disorder which may cause speaking in an accent different from native language. Speech rhythm alterations and deficits in prosody have been reported in most of the cases. Several adult psychogenic FAS cases associated with conversion disorder have been reported. However, treatment of this disorder is not well known. In addition, there is no report on FAS associated with conversion disorder in adolescents in the literature. Herein, we present an adolescent case who admitted to our clinic with symptoms of FAS secondary to conversion disorder which disappeared with fluoxetine treatment. A 15 year-old girl presented to our clinic with complaint of change in speech accent. A month ago, she had admitted to emergency service due to numbness in her hands and feet which started suddenly. Her family had noticed that she was speaking Turkish with a Syrian accent. Before this event, she had spoken typical Turkish accent. No physical or neurological reason was found which could explain speech disorder and no additional psychiatric disorder was found in her psychiatric evaluation. She was diagnosed as FAS associated with conversion disorder and Fluoxetine 10 mg/day treatment was started. Two months later, her speech was completely normal. Several FAS cases associated with conversion disorder were reported in adults. Our patient is first reported adolescent case. Some reported cases before our patient were treated with speech therapy and cognitive-behavioral therapy. In the literature, selective mutism, cerebellar mutism and psychogenic aphonia cases were reported to be successfully treated with fluoxetine. This is the first report suggesting fluoxetine may be effective for FAS secondary to conversion disorder. Further research is needed on this topic.

### KEYWORDS

Accent; conversion; fluoxetine; prosody

Abstract:0072

## Acute Lymphoblastic Leukemia (ALL) And Micropsia–Macropsia: A Case Report

Çağla Çelikkol, Savaş Yılmaz, Ganime Dilek Emlik and Hüseyin Çaksen

Department of Child and Adolescent Psychiatry, Necmettin Erbakan University Meram School of Medicine, Konya, Turkey

E-mail address: [dr.cagla90@gmail.com](mailto:dr.cagla90@gmail.com)

### ABSTRACT

Micropsia and macropsia is defined as dismetrops and affect the visual perception of humans. Micropsia is a situation that causes objects to be perceived less than they are in reality. Macropsia causes people to feel smaller than they actually. Leukemia, the malign proliferation of immature lymphohematopoietic cells, is the most common childhood cancer and the most common subtype of ALL. In this report, the case with macropsia and micropsia symptoms developing after ALL will be evaluated. A six-year-old female patient was admitted

### KEYWORDS

Acute lymphoblastic leukemia; chemotherapy; micropsia; macropsia; dysmetrops

to our clinic. Patient diagnosed with ALL in 2013, received induction therapy with vincristine, dexamethasone and cyclophosphamide and received maintenance therapy with methotrexate and mercaptopurine, and cured 9 months ago. She has been seeing her relatives' heads, sometimes big or small, for about two months. Neurological examination of the patient and MR, EEG, eye examination revealed no pathology. No psychopathology or psychosocial stress was detected in her. After a month and a half follow-up of, the symptoms of macropsia and micropsia disappeared. Chorioretinopathies may result in micropsia or macropsia. It is known that chorioretinopathies are also observed in ALL. However, no findings have been observed in our case of ophthalmic evaluation suggesting chorioretinopathy. Antineoplastic therapies have also been associated with visuospatial disorders in adults and children. Our previous MR findings are consistent with changes in the use of parietal carcinoma in situ chemotherapy. This finding, which developed after treatment, may be related to cyclophosphamide, methotrexate from the chemotherapy agents used. There is no information on micropsia and macropsia that arise during the treatment of ALL in the literature. And data on visual problems related to chemotherapy agents are limited. This case suggests that micropsia and macropsia should be evaluated both during and after treatment.

Abstract:0200

## The Diagnosis of Dementia With Lewy Bodies Presented Like Neuroleptic Malignant Syndrome: A Case Report

Derya Arslan and Özden Arısoy

Department of Psychiatry, Abant İzzet Baysal University School of Medicine, Bolu, Turkey

E-mail address: [dryarslan.md@gmail.com](mailto:dryarslan.md@gmail.com)

### ABSTRACT

Neuroleptic malignant syndrome (NMS) is a life-threatening idiosyncratic reaction that occurs after the administration of neuroleptic drugs. Dementia with Lewy bodies (DLB)'s thought to be the second most common subtype of the dementia. DLB presents with cognitive, motor and psychiatric symptoms. Cognitive impairment, visual hallucinations, parkinsonism and fluctuating confusion are the most common presenting symptoms of DLB. In this paper, it's aimed to report a case with DLB presenting with psychotic symptoms, parkinsonism and autonomic instability like neuroleptic malignant syndrome. After a follow-up of 10 years with a diagnosis of recurrent major depressive disorder, 50 year-old male patient presented to the hospital with lability of blood pressure, insomnia, parkinsonism, visual hallucinations, cognitive impairment, fecal and urinary incontinence. He was using escitalopram 20 mg/day for a year and olanzapine 2.5 mg/day was added to his treatment for visual hallucinations and insomnia by a psychiatrist 15 days ago. The symptoms worsened after the addition of olanzapine to the treatment. In psychiatric examination; orientation was limited, the association of ideas were disorganized. He had fluctuation of consciousness and affective lability. The content of thought was disorganized by persecutory and reference delusions. He had auditory and visual hallucinations at perception examination. He had psychomotor retardation. Upon suspicion of DLP, the patient was immediately assessed by the consultant neurologist. Ultimately, the neurologist recommended the discontinuation of all treatment. He had a loss of hippocampal volume on MRI. Background activity had slowed down in the EEG. This constellation of symptoms was indicative of the DSM-5 criteria for DLB. The most common NMS symptoms include fever, muscle rigidity, altered mental status and evidence of autonomic instability. Fluctuating cognition, recurrent visual hallucinations, spontaneous parkinsonism and autonomic instability are also the most common symptoms in DLB. About half of patients with dementia with Lewy bodies react adversely to antipsychotics. The diagnosis and the clinical management of DLB must be recognized by the psychiatrists because of the fact that the clinical presentation routinely includes psychiatric symptoms.

### KEYWORDS

Neuroleptic malignant syndrome; dementia with Lewy bodies; psychotic symptoms

Abstract:0024

## The Effectiveness of rTMS on Persistent Auditory Hallucinations

Dilek Sarı, Mustafa Ispir, Ayhan Algul and Servet Ebrinç

Department of Psychiatry, Haydarpasa Sultan Abdulhamid Training and Research Hospital, Istanbul, Turkey

E-mail address: [meralmeklekilek@hotmail.com](mailto:meralmeklekilek@hotmail.com)

**ABSTRACT**

Auditory hallucinations are described as auditory experiences without the presence of out stimuli. They are most strongly linked to schizophrenia but are also characterized in patients with Alzheimer disease and patients with epilepsy. Persistent auditory hallucinations (AHs) are a general problem in patients with schizophrenia and contribute to going on disability and morbidity. Repetitive transcranial magnetic stimulation (rTMS) has recently been developed and trialed as a possible, novel treatment for patients with treatment resistant AHs. rTMS has been subjected to a few small randomized controlled trials. On the other hand, little is known about the long-term impact of rTMS on the clinical outcome of patients with persistent auditory hallucinations. We used PSYRATS scale and Positive and Negative Syndrome Scale (PANSS) for auditory hallucinations. PSYRATS scale provides an assessment of 11 dimensions of hallucination severity and character and has established validity and reliability. The PANSS was also used to measure general psychotic symptoms and psychopathology. A 35-year-old right handed man, suffering from auditory hallucinations presented to the psychiatry clinic. He had been treated over this time with multiple typical and atypical antipsychotic medications at full therapeutic doses. These had resulted in a recovery in his general clinical state but had little impact on the existence or severity of his hallucinations. At the time of first rTMS he had been admission treatment with a combination of quetiapine (400 mg/day) and aripiprazole (20 mg/day) for over 12 months. He was enrolled of treatment and received 10 days of rTMS. This was provided for 15 minutes per day, at 1 Hz, left temporoparietal cortex at 90% of the resting motor threshold. This resulted in a dramatic reduction of his auditory hallucinations from PPSRS and from PANSS AH item. His total PANSS score decreased from 67 at baseline to 42 at study end.

**KEYWORDS**

Auditory hallucinations;  
rTMS; schizophrenia

Abstract:0124

## Serotonin Syndrome Treated with Electroconvulsive Therapy: A Case Report

Vuslat Kara Ölmeztoprak, Esra Porgalı Zayman and Süheyla Ünal

Department of Psychiatry, Inonu University, Malatya, Turkey

E-mail address: [vuslatko@gmail.com](mailto:vuslatko@gmail.com)

**ABSTRACT**

Serotonin syndrome is a condition that could present as a complication of treatment with serotonergic drugs, with both central and peripheral symptoms. Symptoms could be prolonged due to delayed diagnosis, comorbidities of the patient and the agents that triggered the serotonergic toxicity. A 62 year-old woman with psychotic depression had a fluoxetine dose increase at her routine visit as she complained of drowsiness. The patient was admitted to our psychiatry ward with serotonin syndrome, which presented with fever, diarrhea, pupillary dilatation, motor agitation, apathic confusion and unsteady gait. Fluoxetine was discontinued and benzodiazepines with chlorpromazine were started. By the third day of follow-up, fever, diaphoresis and diarrhea ceased. The patient was discharged from the hospital with her relatives' demand and consent about the potential risks. About two weeks later, with no obvious improvement in the debilitating symptoms and after her hospitalization in another center for acute renal failure; the patient applied to the emergency service with persisting confusion and motor agitation. She was first admitted to neurology suspecting encephalitis. After the tests proved negative, admitted again to the psychiatry ward. We started electroconvulsive therapy (ECT) with family consent and she had 9 consecutive doses (3 per week) with gradual but satisfactory improvement. Here we present a case of serotonin syndrome triggered with fluoxetine dose increment that could have overlapping catatonic symptoms of accompanying psychotic depression. The patient was eventually decided to be treated with ECT to accelerate the course of recovery and to prevent further complications. As the symptoms persisted, although the few case reports of ECT triggered serotonin syndrome made us cautious, we decided to give the patient ECT. This report suggests that ECT without serotonergic drugs, could be used in serotonin syndrome patients with residual cognitive and motor symptoms.

**KEYWORDS**

Serotonin syndrome;  
electroconvulsive therapy;  
treatment; fluoxetine;  
psychomotor agitation;  
confusion

Abstract:0159

## Post-Contusional Syndrome and Psychotic Depression

Dudu Demiröz, Hatice Yardım Özeyhan, Sehure Azra Yaşar, Ali Hakan Öztürk and İbrahim Eren

Department of Psychiatry, Konya Research and Training Hospital, Konya, Turkey

E-mail address: [drdemiroz42@gmail.com](mailto:drdemiroz42@gmail.com)

### ABSTRACT

Post-contusional syndrome develops after mild to moderate head trauma and characterized by cognitive, physical, psychiatric manifestations. Physical symptoms such as headache, dizziness, speech impairment, hyperacusis, and sleep disturbance can be seen. Psychiatric complaints such as depression, irritability, anxiety, aggression, personality change, emotional variability, energy insufficiency, fatigue, anorexia and changes in cognitive functions, such as attention, abstraction, perception and memory deficits are also frequently seen. Psychosis is very rare in post-contusional syndrome. We are characterized by the presence of psychotic depression in post-contusional syndrome. A 38 year-old male patient had a history of head trauma fifty days before admission to our polyclinic. After the bicycle accident, the patient applied to the emergency room. No pathological findings were found in cranial imaging studies performed in emergency department. In the posttraumatic period, complaints of fatigue, increase in sleep, decrease in speech desire, decrease in mobility, nervousness, screaming and occasionally not getting to know people around. The patient's psychiatric examination had depressed mood, occasional irritability, increased sleep, decreased speech, and nihilistic delusions. Treatment was planned as oral risperidone 1 mg/day, venlafaxine 75 mg/day and mirtazapine 15 mg/day. During the first month of treatment, the patient's depressive and psychotic complaints regressed. The most common psychiatric disorder in post-contusional syndrome is anxiety disorder and depression. The frequency of major depression following mild to moderate head trauma is 14–29%. Mood changes in post-contractual syndrome are often accompanied by memory loss, decreased information processing speed, and neuropsychological disturbances. In our case, depressive mood, occasional recognition of the surroundings, unknown where it is available. Post-contusional syndrome patients may come physical, cognitive and psychiatric symptoms. Since there are many syndromes that mimic many psychiatric disorders, head trauma in the psychiatric history must be questioned.

### KEYWORDS

Post-contusional syndrome; post-concussion syndrome in psychiatry; psychotic depression

Abstract:0197

## Multiple Complex Developmental Disorder: Two Representative Cases and Diagnostic Difficulties

Başak Karabucak, Ebru Sadriye Çengel Kültür and Tuna Halime Çak Esen

Department of Child and Adolescent Psychiatry, Hacettepe University, Ankara, Turkey

E-mail address: [karabucakbasak@gmail.com](mailto:karabucakbasak@gmail.com)

### ABSTRACT

Multiple complex developmental disorder (MCDD) is a little-known disorder used to be labeled as 'childhood schizophrenia' and 'borderline syndrome of childhood' in the past and as 'childhood schizotypal disorder' or 'schizoid personality' more recently. Although the combination of early onset impairment in affect regulation, high levels of anxiety, disturbed social relationships, and periods of thought problems has been recognized by child psychiatrists throughout the past five decades and is not a rare phenomenon, neither the classification system of ICD-10 nor the DSM-5 lists MCDD as an independent disorder. Cohen, Paul, and Volkmar (1986) suggested the term multiple complex developmental disorder (MCDD) for which they proposed a specific set of diagnostic criteria. They emphasized that the social impairment seen in these children was suggestive of autism, and therefore considered MCDD as belonging to the group of pervasive developmental disorders (PDDs). In this article we aimed to focus on some special features and differential diagnosis of this disorder. Two eleven-years-old male patients admitted in our outpatient clinic with social difficulties, maladjustment and anxiety complaints. They had academic failure, behavioral problems in school, magical thinking and impairment in reality testing was defined as 'odd thinking' in teachers' reports. Both applied to other psychiatry clinics earlier, diagnosed with ADHD because of their distractibility and lack of interest in the class; treated with methylphenidate, both children manifested anger outbursts and suicidal thoughts after pharmacotherapy was initiated. These two cases having similar atypical developmental trajectories and recent complaints will be discussed in terms of differential diagnosis and treatment.

### KEYWORDS

ADHD; multiple complex developmental disorder; pervasive developmental disorder

Abstract:0337

## Acute Dystonic Reaction Induced by Low-Dose Aripiprazole In an Adolescent Case

Ferhat Yaylacı<sup>a</sup> and Handan Özek Erkan<sup>b</sup>

<sup>a</sup>Department of Child and Adolescent Psychiatry, Karaman State Hospital, Karaman, Turkey; <sup>b</sup>Department of Child and Adolescent Psychiatry, Dr. Behcet Uz Children's Research and Training Hospital, Izmir, Turkey

E-mail address: [handanozek@yahoo.com](mailto:handanozek@yahoo.com)

### ABSTRACT

Acute dystonia is defined as extraordinary and long-lasting involuntary contraction of eye (oculogyric crisis), head, neck (torticollis or retrocollis), and limb or trunk muscles. Dopamine blockage within nigrostriatal pathways increase the odds of developing extrapyramidal side effects, including acute dystonia. Due to its differences with regard to receptor binding, acute dystonia caused by aripiprazole is relatively less encountered in clinical practice. Relationship between aripiprazole and acute dystonia, that is uncommon, is mainly demonstrated via case studies. This case report aimed to present a 16 year-old adolescent girl diagnosed with obsessive-compulsive disorder (OCD) that had developed acute dystonia upon aripiprazole add-on to her routine treatment regimen with fluoxetine. Dystonia was resolved quickly after medication cessation.

### KEYWORDS

Dystonia; aripiprazole; adolescent

Abstract:0346

## Mental or Medical Disorder? The Dilemma Regarding Conversion Disorder Diagnosis

Meliha Zengin Eroğlu, Mecit Çalışkan, Seda Kiraz and Arif Çipil

Department of Psychiatry, Health Sciences University Haydarpaşa Numune Training and Research Hospital, Istanbul, Turkey

E-mail address: [melihazengin@gmail.com](mailto:melihazengin@gmail.com)

### ABSTRACT

According to the modern psychiatric classification systems, conversion disorder is defined as a disabling disorder with one or more neurological symptoms that suggest a physical disease and accompanying to psychological conflict. Although conversion disorder is assumed as a psychological diagnosis the lack of organic etiology of its symptoms, the nature of the exact mechanisms of these symptoms are not elusive yet. A misdiagnosis of a neurologic disorder as a conversion disorder will be discussed in this paper. A 44 year-old female patient admitted to our psychiatry outpatient clinic with complaints of vertigo, dizziness, speech problems, sleep disorders and postural instability. Nearly one year ago she was hospitalized to two different neurology clinics because of the same symptoms. She was diagnosed as conversion disorder. She told about her marital problems and dizziness at psychiatric examination. But she was unconcerned about her neurologic problems. Escitalopram treatment changed with fluoxetine and quetiapine was stopped. Because of vertigo and dizziness she fell at home and injured her chin. After this event she hospitalized to our psychiatry clinic to check conversion disorder diagnosis. Routine biochemical, hemogram, infectious, and hormonal tests were normal. Radiologic examinations were at normal limits. She was evaluated by neurology department of our hospital. After discharging psychiatry clinic her depressive and anxiety symptoms increased. Nearly six months later her cerebral magnetic resonance imaging showed diffuse atrophy at both two cerebral and cerebellar hemispheres. Modern psychiatric diagnostic systems classify neurological symptoms that cannot be explained by a physical disease or another psychiatric disorder as conversion disorder. The most common presenting symptoms of misdiagnosed patients are gait and movement disturbances. The aim of this case report is to draw attention to the psychiatric presentations of neurologic diseases.

### KEYWORDS

Conversion disorder; dissociative disorder; autonomic dysfunction

Abstract:0372

## Pathological Lying in an Adolescent: A Case Report

İpek Fatma Özaktac, Murat Altın, Ayşe Sena Sarıdoğan and Eser Buluş

Medical Park Gaziosmanpaşa Hospital, Istanbul, Turkey

E-mail address: [ipekozaktac@gmail.com](mailto:ipekozaktac@gmail.com)

**ABSTRACT**

The main characteristic of pathological lying (PL) is the history of impulsive, frequent and repeated lying for which no external benefit or apparent psychological motive can be discerned. While there is no consensus on the definition of PL across the psychiatric community, there is general agreement on its core elements. PL has been recognized and written about in the psychiatric literature for more than a century. Although, some cases with PL have reported from Turkey previously; PL had been defined as a symptom of Factitious Disorder and Borderline Personality Disorder in these case reports. The aim of this case report is to illustrate a case that exhibit PL without evidence of Factitious Disorder or any other overt psychiatric disorder. A 17 year-old girl presented with a 12 month history of lies which told repeatedly to her school friends and teachers. The lies told by the patient were about the divorce of her parents, car accidents or pregnancy of the patient. Her medical history, physical and neurological examination revealed was negative for another medical condition and this is confirmed by a routine EEG. Other psychiatric disorders were examined during psychiatric interview according to DSM-5 criteria and Minnesota Multiphasic Personality Inventory was performed for the elimination of any other personality problems. For the patient it is demonstrated the PL phenomenon in consequence of the absence of another psychiatric illness, the impulsive and frequent nature of the lies and above all the patient did not have any personal or external benefit. There was a significant reduction in symptoms through a fluoxetine 20 mg/day treatment and cognitive behavioral therapy program for impulse control. We believe that there is a need for the PL patients to provide a detailed clinical evaluation with psychopharmacological treatment and psychotherapy.

**KEYWORDS**

Adolescent; pathological lying; treatment; therapy

Abstract:0381

## The Patient Who Unceasingly Spinning Around Herself: OCD or Psychosis?

Alper Bülbül, Sevilay Güneş, Rabia Nazik Yüksel, Makbule Çiğdem Aydemir and Erol Göka

Department of Psychiatry, Ankara Numune Training and Research Hospital, Ankara, Turkey

E-mail address: [alperbulbul@yandex.com](mailto:alperbulbul@yandex.com)

**ABSTRACT**

Catatonia is a syndrome presenting with motor and psychotic signs; frequently found among patients with mania, depression and schizophrenia. However catatonic symptoms were reported in patients with obsessive-compulsive disorder (OCD) too. We reported a case presenting with psychotic, obsessive-compulsive symptoms and catatonic signs who has been diagnosed and treated for OCD and afterwards psychosis before. A 22 year-old, female applied with spinning around herself which hinders her from daily routine and posturing for the last 6 months. She was unable to sleep and lost 22 kilograms because of spinning. After hospitalization she explained her situation as she was controlled by evil spirits who forced her to spin around. After she was sedated by lorazepam, she could not spin around however we observed she had posturing. We couldn't differentiate her spinning was a compulsive behavior or a stereotypic movement as a part of catatonia. Amisulpride treatment was given for psychotic symptoms but, because of her food and liquid intake rejection we had to apply electro-convulsive therapy (ECT). After ECT and amisulpride treatment psychotic and catatonic symptoms were improved but we observed that she was staring at her right side frequently which is a symptom she could not explain. She was discharged with amisulpride. At the follow-up she explained aforementioned symptoms ridiculous. In OCD patients with resistant stereotypic movements, psychotic disorder should also be considered in differential diagnosis. Even in catatonic situations with or without stereotypic movements, OCD should still be in differential diagnosis. In this case, it was aimed to draw attention to stereotypy and its treatment which is a rare sign of catatonia.

**KEYWORDS**

Catatonia; psychosis; obsessive-compulsive disorder; stereotypy

Abstract:0400

## Two Non-retentive Fecal Incontinence Cases and Comorbidity of Epilepsy

Zehra Koyuncu, Muhammed Tayyib Kadak, Rahime Hülya Bingöl and Burak Doğangün

Department of Child and Adolescent Psychiatry, Istanbul University Cerrahpasa School of Medicine, Istanbul, Turkey

E-mail address: [zboybay@gmail.com](mailto:zboybay@gmail.com)



**ABSTRACT**

Encopresis is defined as passage of stool in inappropriate places in children older than 4 years old. Encopresis may be together with or without constipation. Comorbidity with psychiatric disorder occurs in approximately 30-50% of children with encopresis. Epilepsy, common disease in childhood may accompany with encopresis. A 12 years old boy, has been complaining enuresis and soiling for two years. He was not constipated. He was soiling one or two times a month, he was soiling when he watch TV and he doesn't aware of that. There was no organic pathology obtained in pediatric examination. For further examination electroencephalogram was planned. In the right frontotemporal region of brain spike-wave paroxysmal activity was reported. Patient was diagnosed as epilepsy and valproic acid 500 mg/day treatment was started. Second case was 12 years old boy again. His complaint was soiling for 5 years. His problem started 4 years after toilet training. According to both parent's anamnesis and observation of doctor during the interview, the conflict between the patient and his mother was evident. No organic pathology was found that cause encopresis. Patient was not constipated. Parents expressed that the child had periods of loss of consciousness. EEG was planned for evaluation of epilepsy. Generalized 3 Hz 3-10s spike-wave discharge was reported which was considered as absence epilepsy. The comorbidity of elimination disorders and emotional disorders such as ADHD, conduct disorder is well known in clinical and research practice. However the comorbidity of other medical diseases and elimination disorders such as epilepsy is a strong candidate to be investigated. EEG can be used more frequently in psychiatric patient evaluations. We emphasized that minimal neurological findings should not be ignored in cases with encopresis.

**KEYWORDS**

Comorbidity; encopresis; epilepsy

Abstract:0425

## Akathisia: A Condition Misinterpreted as Psychomotor Agitation

Mine Uzel, Selahattin Ayas<sup>b</sup>, Yüksel Kıvrak and Yiğit Şahbal

<sup>a</sup>Department of Psychiatry, Kafkas University, Kars, Turkey; <sup>b</sup>Department of Neurology, Dumlupınar University, Kutahya, Turkey

E-mail address: [dormansiy@gmail.com](mailto:dormansiy@gmail.com)

**ABSTRACT**

It is a condition with an urge to move which is caused by inner restlessness. Akathisia can be an adverse effect of treatment with several drugs, particularly, antipsychotic, antidepressant or antiemetics. Akathisia is the most escaping sign among acute movement disorders. Patients with this condition are unable to feel comfortable in any position, such as sitting or standing for more than a few minutes. Individuals with this condition have a compulsion to move and feeling of inner restlessness. It may be cause of discontinuation of a drug, violence and suicides. Thus; it is important to differentiate akathisia from the psychotic agitation. Our current case are presented in order to enhance awareness on akathisia, a component of many syndrome and confusing with many clinical situations. A 20 year-old man has distress, unhappiness and sleep disorder, after the army recruitment, his complaints became more evident. The patient was hospitalized to psychiatry service on account of acute onset psychomotor agitation, visual and auditory hallucinations at night. He administered escitalopram 10 mg/day, risperidone 4 mg/day, quetiapine 200 mg/day. After 14 day of treatment period, there were no regresses on complaints. The patient was given 10 days of rest and discharged from hospital voluntarily. Patient discontinued his medications on 5th day of his rest due to exacerbation of complaints. On account of increased activity and aggressiveness, the patient was admitted to emergency department. In the Emergency Room treatment with haloperidol 10 mg, chlorpromazine 25 mg, biperiden 5 mg, and metoclopramide 10 mg intramuscular have been administered. Motor movements, anxiety and agitation exacerbation has occurred after the medicament administration. Following our examination, it could be associated with drug-induced extrapyramidal side effects. There was no pathology detected on image or biochemical tests. Patient started to be treated by Lorazepam and biperiden. His complaints became less evident. Lorazepam and biperiden were given up gradually and continued with escitalopram treatment.

**KEYWORDS**

Akathisia; antipsychotic; psychomotor agitation

Abstract:0140

## Specific Learning Disability in Adulthood

Kübra Kocagöz, Demet Sağlam Aykut, Gamze Kutlu and Ali Baz

Department of Psychiatry, Karadeniz Technical University School of Medicine, Trabzon, Turkey

E-mail address: [kubraa\\_kocagoz@hotmail.com](mailto:kubraa_kocagoz@hotmail.com)

**ABSTRACT**

Learning difficulties include a group of heterogeneous defects that present with delays of impairments in acquiring and using skills of speaking, reading, writing, understanding and arithmetic. This case report discusses through a specific learning disability case diagnosed in adulthood that this clinical picture can also be seen in adulthood. 32 year-old single female patient who was a university student was admitted to psychiatry outpatient clinic with the symptoms that she had misspelling she realized after the exam and she could not learn the route although she lived in the same place and she used the same public transportation vehicle for a month. In her history, she stated that she had difficulties in learning to read and write in elementary school years, she wrote some letters or numbers wrong or mirrored. She bought newspapers and read them to develop her reading skills, she finished high school in 9 years, then was enrolled to the college to major in journalism. Her mental state examination showed that she had good self-care, her speed of speech was partly slowed, she had anxious affect and her thought process was slowed. Clinical, psychometric, EEG, and MRI assessments showed that the patient had impairments in functions such as integration of somatic and visual field information, use of spatial information, movement orientation and finding direction which are related with parietal lobe. The patient was followed with a tentative diagnosis of specific learning disability. Although specific learning disability continues for a lifetime, when the diagnosis is made, the problems these patients have can be solved through education programs specific for them. While specific learning disabilities are frequently seen in childhood, through this case, it can be seen that it should be kept in mind in the diagnostic assessment of patients who are admitted with learning disabilities in adulthood.

**KEYWORDS**

Specific learning disability; adulthood; late diagnosis

Abstract:0247

## Generalized Anxiety Disorder and Attention-Deficit/Hyperactivity Disorder Based on Non-Verbal Learning Disability (NVLD): A Case Report

Güler Göl, Ekrem Gültaş, Mehmet Akif Cansız and Ali Evren Tufan

Department of Child and Adolescent Psychiatry, Abant İzzet Baysal University, Bolu, Turkey

E-mail address: [golguler@gmail.com](mailto:golguler@gmail.com)

**ABSTRACT**

Non-verbal Learning Disorder (NVLD) is a clinical syndrome which is not among those in the diagnosis classifications such as DSM-5 and ICD-10. Some of the characteristics of NVLD are the visual-spatial perception disability, the weakness in the handwriting and math skills, and the problems in the perception of social cues. In this report, in an adolescence case, it is aimed to discuss the differential diagnosis of NVLD and to show that the functionality may increase along with the treatment of comorbid disorders. Fourteen year-old patient applied to our clinic with her parents with the complaints of "inability to communicate with people, to express their feelings and to do as expected from her age". During the evaluation, it is found out that she has no friends and low self-esteem. She has low academic success, low arithmetic skills and difficulties in painting class and physical education class that require motor skills. It was reported that verbal and memorizing skills are very well-developed despite those problems and social communication problems. In the light of history, evaluation, test results, it is considered that the patient may meet the DSM-5 criteria for the ADHD-Predominant Inattentive Presentation, Social Communication Disorder (SCD), Specific Learning Disorder, Developmental Coordination Disorder (DCD), and Generalized Anxiety Disorder (GAD) and, she fits in the clinical characteristics of NVLD. After psycho-education was provided to the parents, the treatment was 0.5 mg/kg/day to 1.2 mg/kg/day atomoxetine. Fluoxetine was started at 10 mg/day to 20 mg/day. In the continued weeks, it is observed a decrease in the anxiety, improvement in the attention, a considerable increase in the academic success. In our case, differential diagnosis of the patient included SCD, Asperger syndrome, ADHD, and DCD. The diagnosis of NVLD is a controversial syndrome due to unclear diagnosis criteria and comorbid disorders. The clearer clinical characteristics will provide more correct diagnosis, treatment and guidance.

**KEYWORDS**

Non-verbal learning disability; anxiety; attention-deficit/hyperactivity disorder

Abstract:0238

## Use of Intravenous Immunoglobulin in the Treatment of Pediatric Autoimmune Neuropsychiatric Disorders Associated with Streptococcal infections: A Case Report

Deniz Argüz Çıldır and Tugba Kalyoncu

Department of Child and Adolescent Psychiatry, Tepecik Training and Research Hospital, Izmir, Turkey

E-mail address: [deniz.argz@yahoo.com](mailto:deniz.argz@yahoo.com)

### ABSTRACT

Pediatric Autoimmune Neuropsychiatric Disorders Associated with Streptococcus infections (PANDAS) was invented by Swedo et al. in 1998 to describe a subset of childhood obsessive-compulsive disorders (OCD) and tic disorders, which is triggered by group-A beta-hemolytic Streptococcus infection. The treatments of OCD and tic disorders are being researched by scientists intensely. Some reports suggest that OCD symptoms or tics in patients diagnosed with PANDAS may be treated with serotonergic and antipsychotic drugs, or combined behavioral and pharmacological treatments. When the standard treatments of PANDAS failed, and the symptoms were still existing, Swedo and colleagues suggested using immunomodulatory interventions. The patient was a 15 year-old boy, who had a treatment history with Amoxicillin/clavulanic acid after his febrile illness, applied to child psychiatry with choreiform movements, as well as motor and phonic tics (including shrugging, knocking and coughing). His course of illness, diagnostic procedure and treatment history are described. The etiology of post-streptococcal inflammation shows that it has an opportunity for treatment and even prevention by applying the immunomodulatory therapies like intravenous immunoglobulin. Recent studies revealed that intravenous immunoglobulin had positive effects to reduce the neuropsychiatric symptoms of severely ill patients diagnosed with PANDAS. However, there were some other reports in which the treatment with immunomodulatory therapy did not effect on symptoms of PANDAS. In this case, we aimed to discuss the effectiveness of this treatment in the context of the literature. According to the PANDAS Physicians Network (PPN) to be able to control all of the symptoms, it is necessary to use a combination of treatments including immunomodulatory therapy, antibiotic prophylaxis, and drugs for target symptoms. These suggestions need to further research in this area.

### KEYWORDS

Autoimmunity; PANDAS; streptococcal infection; immunoglobulin; tic disorders

Abstract:0066

## Search for Unusual Treatment in Insomnia

Yasin Duman, Serdar Süleyman Can, Çağlar Soykan and Ayşegül Taşdelen Kul

Department of Psychiatry, Yildirim Beyazıt University, Ankara, Turkey

E-mail address: [aysegul.tsdl04@hotmail.com](mailto:aysegul.tsdl04@hotmail.com)

### ABSTRACT

Insomnia is one of the most common mental disorders and the prevalence is about 10%. Assessment of insomnia should include structured clinical interview, prospective sleep log, and actigraphy. Pharmacological drugs are used in the treatment of insomnia. Apart from these treatments, cognitive behavioral therapy, sleep restriction, sleep hygiene recommendation, relaxation exercises are also used. The use of alcohol for the treatment of some patients is clinically known. Here we will discuss the alternative method used by the insomnia patient referring to our clinic. A 45 year-old male patient, retired, living alone admitted to our outpatient psychiatry clinic. For 10 years, he has been followed with the diagnosis of primer insomnia. The patient previously used trazodone 50 mg/day, mirtazapine 15 mg/day and agomelatine 25 mg/day treatments, and these treatments did not benefit. The patient started quetiapine 25 mg/day 6 months ago and went up to 50 mg/day 2 months later. The patient said that, he cannot sleep well if he doesn't take two different branded drug with the same molecule. Despite the detailed explanation that the two drugs with different names had the same substance, the patient insisted on this issue. The patient says that he can sleep by doing train travel these days. An average of 190 hours of travel by train per month on a journey of 900 km has been detected. Although there are many options in the treatment of insomnia, some patients do not receive the desired treatment response. Many patients, as we describe in our case, refer to alternative medicine and treatment

### KEYWORDS

Insomnia; travel by train; unusual treatment

methods. In conclusion, consideration of insomnia as a multidisciplinary approach, investigation of comorbid conditions, detailed information of the patient in treatment and sleep hygiene suggestions should be supported.

Abstract:0126

## Effectiveness of Daily Single Dose Buspirone Treatment in Sleep Bruxism

Ebru Sağlam and Ömer Faruk Akça

Department of Child and Adolescent Psychiatry, Necmettin Erbakan University Meram School of Medicine, Konya

E-mail address: [e-saglam-55@hotmail.com](mailto:e-saglam-55@hotmail.com)

### ABSTRACT

Sleep bruxism (SB) is a temporo-mandibular joint dysfunction with grinding or clenching of teeth in the sleep leading to masseter muscle hypertrophy, headache and periodontal problems. It is a common problem (the prevalence of SB in children ranges from 3.5% to 40.6%), however, no specific treatment has been reported for this disorder. Buspirone is an anxiolytic drug with its partial agonistic activity at the serotonin 5-HT<sub>1A</sub> receptors in addition to its various activities on dopamine and 5-HT<sub>2</sub> receptors. In this study, we present a 7-year-old child whose sleep bruxism disappeared with daily single dose buspirone treatment. A 7 year-old boy was referred to our outpatient clinic with complaints of carelessness, hyperactivity, fear of darkness, anxiety about losing his mother, sleeping with mother and tooth grinding about 2 hours every night. After psychiatric evaluation and gathering information from teacher and parent, he was diagnosed with ADHD combined presentation and separation anxiety disorder according to criteria of the DSM-5. His mother did not want medication for ADHD, she only wanted to medication for sleep bruxism. He was treated with daily single dose buspirone (5 mg per night). His bruxism symptoms significantly declined after a week of treatment. By the end of 6 weeks of buspirone treatment, his family reported no bruxism symptoms. On the disappearance of bruxism, his mother stopped the medication. However, SB started again a week after stopping the medication. The treatment was not restarted because his family refused to take treatment again. This report suggests that daily single dose buspirone 5 mg can be useful in bruxism childhood. This may be related to its effects on serotonergic and dopaminergic receptors. Further systematic studies are required in order to establish the relationship between buspirone and bruxism.

### KEYWORDS

Buspirone; single dose; sleep bruxism

Abstract:0187

## Narcolepsy in a Child Psychiatry Unit: A Case Report

Özlem Önen, Ayşe Kutlu and Handan Özek Erkan

Department of Child and Adolescent Psychiatry, Dr. Behcet Uz Children's Research and Training Hospital, Izmir, Turkey

E-mail address: [drozlemonen@gmail.com](mailto:drozlemonen@gmail.com)

### ABSTRACT

Narcolepsy is a chronic disorder that might cause severe morbidity and functional deterioration with a wide range of complicated symptoms and no clear identified etiology. The condition is even more difficult to be recognized in children as clinical picture and symptoms vary and interchange even further. With this report, we aimed to present an 11 year-old case diagnosed with narcolepsy in a child psychiatry unit along with relevant literature. Psychiatric assessment of the case that applied to our child psychiatry unit was carried out by using Diagnostic and Statistical Manual of Mental Disorders 5th edition (DSM-5) criteria. Detailed clinical examination, neurological tests and imaging as well as polysomnography were made. The case was diagnosed with Narcolepsy. She clinically improved with a combined treatment regimen of methylphenydate- OROS and behavioral therapy for sleep pattern and hygiene. As narcolepsy is a less common condition encountered in child psychiatry settings and symptoms might mimic other neurological and psychiatric conditions, in turn, lessening the odds to recognize early on, we believe that we, as child psychiatrists, need to bear this disorder in our minds for differential diagnosis. Since current treatment options mainly target visible symptoms, developing novel treatment strategies directed towards underlying etiology would be important. In that sense, we believe that increasing the number of case studies and researches in this understudied field of child psychiatry shall contribute greatly to have a better understanding of the disorder.

### KEYWORDS

Child psychiatry; diagnosis; narcolepsy; preadolescent; treatment

Abstract:0335

## Kleine-Levin Syndrome in an Adolescent: A Case Report

Handan Özek Erkuran<sup>a</sup>, Ecenur Aydın Aşık<sup>b</sup> and Şermin Yalın Sapmaz<sup>c</sup>

<sup>a</sup>Department of Child and Adolescent Psychiatry, Dr. Behcet Uz Children's Research and Training Hospital, Izmir, Turkey; <sup>b</sup>Department of Psychiatry, Celal Bayar University Medical School, Manisa, Turkey; <sup>c</sup>Department of Child and Adolescent Psychiatry, Celal Bayar University Medical School, Manisa, Turkey

E-mail address: [handanozek@yahoo.com](mailto:handanozek@yahoo.com)

### ABSTRACT

Kleine-Levin syndrome (KLS) is a rare and frequently misdiagnosed disorder with typical onset at adolescence and a male dominance that is presented with hypersomnia, hyperphagia, disinhibited behavior and perceptible abnormalities. Even though increasing number of researches have been conducted to shed a light on its etiology, no clear underlying mechanism have yet been identified. Similar to relatively small information about etiology of the disorder, no specific treatment technique has been identified to successfully eliminate the phenomenon; however treatment options that target symptom relief and decline in frequency of episodes have been present. This case report aimed to present the clinical course of a 12 year-old adolescent with KLS who was successfully treated with a combination of Carbamazepine (CBZ) and short- acting methylphenidate (MPH) that was used during episodes, along with discussion of relevant literature.

### KEYWORDS

Kleine-Levin syndrome; adolescent; methylphenidate; carbamazepine; treatment

Abstract:0354

## Management of Sleep Disturbances Induced by Montelukast: A Case Report

Tuğba Kalyoncu<sup>a</sup>, Deniz Argüz Çıldır<sup>a</sup> and Serpil Erermiş<sup>b</sup>

<sup>a</sup>Izmir Tepecik Training and Research Hospital, Izmir, Turkey; <sup>b</sup>Ege University Medical School, Izmir, Turkey

E-mail address: [tugbadonuk@gmail.com](mailto:tugbadonuk@gmail.com)

### ABSTRACT

Montelukast is a selective leukotriene receptor antagonist which is prevalently used for the treatment of asthma in both children and adults. It is preferred as an add-on therapy to inhaled corticosteroids. Although a number of clinical trials suggested that montelukast is a safe drug in terms of adverse drug reactions (ADRs), several cases have been reported with nightmares and sleep abnormalities. With this case report, we aimed to present a female adolescent patient who had severe and long-termed nightmares after treated with montelukast. A 14 year-old female, who diagnosed with allergic asthma for 3 years ago, had some severe attacks in the certain time of the year. Her physicians took the disease under control with corticosteroids and they attempted to prescribe leukotriene receptor antagonist as an add-on therapy. During the therapy's second week, patient applied with severe nightmares. Her treatment was ceased. One-month after, she applied our child psychiatry unit. Her follow-up process was measured by "Children's Sleep Habits Questionnaire" and "Global Assessment Scale". Sleep disturbances including nightmares due to montelukast have not been described sufficiently, while several cases have been reported. Previous research showed that both adults and children developed psychiatric symptoms after the intake of the medication. However, the symptoms of the reported cases disappeared within 48 h after the cessation of drug intake. We aimed to discuss the management of long-termed nightmares despite of the discontinuation of the montelukast therapy. The use of montelukast can cause several ADRs, especially in children, of which physicians should be aware in their clinical practice.

### KEYWORDS

Asthma; montelukast; nightmare; sleep disturbances

Abstract:0007

## Progression of Bronchospasm Due To Electroconvulsive Therapy

İsmail Karka<sup>a</sup>, Fethiye Kilicaslan<sup>b</sup> and Mehmet Asoglu<sup>a</sup>

<sup>a</sup>Department of Psychiatry, Harran University School of Medicine, Sanliurfa, Turkey; <sup>b</sup>Department of Child and Adolescent Psychiatry, University of Harran, Sanliurfa, Turkey

E-mail address: [drismailkarka@gmail.com](mailto:drismailkarka@gmail.com)

**ABSTRACT**

Electroconvulsive therapy (ECT) is a process of creating generalized convulsions by stimulating the brain with electric stimulation. ECT is used as a primary treatment in psychological depression, such as suicide risk, unresponsive to manic excitation, catatonic schizophrenia. Most side effects of ECT are nondestructive and transient and as well can be prevented by special measures. In this article we will describe an adolescent patient who had bronchospasm after ECT session. A 17 year-old male patient with a diagnosis of bipolar disorder was referred to our clinic due to non-response to treatment. At the admission, the patient had elevated mood, pressured speech and distractibility. He was hospitalized with bipolar disorder-manic episode after these all examination. He has a history of asthma. The patient was on Valproic acid PO 2500 mg/day, Lithium PO 1200 mg/day, and Olanzapine PO 20 mg/day. It was decided to administer ECT due to non-response to treatment. After anesthesiologist evaluated the patient, he was ready for ECT. Propofol as an anesthetic and Rocuronium Bromide as a muscle relaxant were administered before ECT, Sugammadex was given to patient after ECT. After the second ECT session, the patient's saturation went down to 30%. All possible organic etiologies were ruled out. Considering that the crisis was caused by asthma, the patient was treated, after 2 days his saturation increased to 95%. In the literature the incidence of bronchospasm related to ECT was very rare. Propofol is widely used in ECT anesthesia because it relatively does not impair hemodynamic stability. Although rare, anaphylactic reactions resulting in bronchospasm have been reported. The presence of asthma in our patient may have been a facilitating factor in the progress of bronchospasm. Although for our patient it is not certain whether the bronchospasm was due to ECT or propofol, it should be keep in mind when applying ECT in asthmatic patients.

**KEYWORDS**

Bipolar disorder;  
bronchospasm; ECT

Abstract:0044

## Affective Disorder Due to Wilson's Disease: A Case Report

Ceren Enüstün Hürmeydan and Özge Şahmelikoğlu Onur

Department of Psychiatry, Bakirkoy Research and Training Hospital for Psychiatry, Neurology and Neurosurgery, Istanbul, Turkey

E-mail address: [ozge\\_sahmelikoglu@hotmail.com](mailto:ozge_sahmelikoglu@hotmail.com)

**ABSTRACT**

Wilson's disease (WD) is an autosomal recessive disorder due to copper metabolism disorder. In the literature psychiatric disorders such as loss of emotional control, depression, schizophrenia-like conditions, anxiety disorders, dementia, cognitive impairment, mania, drop in school performance, behavioral abnormalities and personality changes and suicide are reported in WD. In this report, it is aimed to present a case of Affective Disorder due to WD. A 32 year-old male patient admitted with complaints of increased amount of speech and religious activities, decreased need for sleep and aggression to his mother. In psychiatric history there were diagnosis of WD at the age of 17, followed by behavioral changes and decreased academic performance, psychotic symptoms and recurrent suicide attempts. In psychiatric examination grandiosity, megalomaniac and mystical delusions and in appropriate laughs, flight of ideas were noted. In laboratory tests; PLT:  $133.7 \times 10^3/\mu\text{L}$  (low), ALP: 132U/L (high), ceruloplasmin:  $<2.0 \text{ mg/dL}$  (low), serum copper:  $48.6 \mu\text{g/Ug/24 h}$  (high), negative hepatitis markers were noted. In neuropsychological test; mildly verbal and moderate nonverbal memory impairment associated with cognitive dysfunction in the frontal axle were detected. Hyperintense lesions in the bilateral putamen T2 sequence were detected in brain MR. The Kayser-Fleischer ring was observed in the examination of eye diseases. He was diagnosed with Affective Disorder due to WD. Amisulpride 800 mg/day and biperidene 4 mg/day were preferred due to the EPS sensitivity in the treatment of the patient. Within about 1 week, the patient was discharged with treatment of 800 mg/day and biperidine 4 mg/day, whose symptoms improved markedly. WD should come to mind in patients with psychiatric complaints, accompanying especially with neurological findings such as movement disorders, forgetfulness. In Wilson's disease; the psychiatric picture can be seen in many different forms such as depression, psychosis, personality changes, and mood disorder.

**KEYWORDS**

Wilson's Disease; affective  
disorder; antipsychotics



Abstract:0046

## Hypomania in a Patient with Acquired Immune Deficiency Syndrome

Sevda Bağ<sup>a</sup>, Suat Yalçın<sup>a</sup>, Ozge Sahmelikoğlu Onur<sup>a</sup> and Didem Nagehan Sarı<sup>b</sup>

<sup>a</sup>Department of Psychiatry, Bakırköy Prof. Dr. Mazhar Osman Mental Health and Neurological Diseases Training and Research Hospital, Istanbul, Turkey; <sup>b</sup>Istanbul Training and Research Hospital, Department of Infectious Diseases, Istanbul, Turkey

E-mail address: [sevdabag@yahoo.com](mailto:sevdabag@yahoo.com)

### ABSTRACT

Human Immunodeficiency Virus (HIV) is a retrovirus. It affects CD4 lymphocytes and inflammation and neoplasms occur as a consequence of destruction of the cellular origin of immunity and disruption of the general immunity regulation. Many psychiatric syndromes can be observed in HIV-infected individuals, such as depressive disorders, anxiety disorders, personality disorders, bipolar disorder, alcohol-substance abuse disorders, delirium, dementia and psychosis. Our aim in this case report is to discuss the case of hypomania that develops in an HIV positive patient. A 41 year-old male patient was diagnosed with acquired immunodeficiency before 6-month and followed up at infection clinic, and the last three days of sudden onset of increased insomnia, more spending money, nervousness complaints. He was consulted to psychiatric polyclinic and at psychological examination of the patient, increased psychomotor activity was detected. Haloperidol 10 mg/day and biperiden ampule 5 mg/day for 3 days were applied. The diagnosis of the psychiatric illness was evaluated as hypomania due to acquired immunodeficiency. 1000 mg/day of valproic acid was started to patient whose symptoms were regressed by discussing the infectious diseases clinic. The patient has been followed in remission for the last three months. The prevalence of mania in HIV disease is 9%. Premorbid bipolar disorder in acute mania HIV disease; may be associated with opportunistic infections or AIDS-related neoplasms or treatments or HIV-based brain lesions. Self or family history of mood disorders were found in those who developed manic syndrome in the early stages of HIV disease, but there was no family story in our case. Finally It is important that patients with acquired immunodeficiency can have various psychiatric disorders and the hypomanic attack should be kept in mind.

### KEYWORDS

HIV; immune; hypomania

Abstract:0083

## A Manic Episode Induced by Herbal Supplement Wild Berry

Bahar Kılıç, Elif Merve Kurt, İsmail Ak and Ali Emre Şevik

Department of Psychiatry, Karabuk University, Karabuk, Turkey

E-mail address: [bhrtklc@gmail.com](mailto:bhrtklc@gmail.com)

### ABSTRACT

Herbal supplements are used widely in alternative medicine. These supplements are mostly used for various health problems. There are reports for manic episodes caused by hypericum perforatum, physalis peruviana, arginine-ornithine-lysine containing supplements. This case report illustrates a supplement containing wild berry as a cause of manic episode. The patient was 34 year-old man who has been working as a security officer. He was referred to our with manic symptoms. This symptoms were visible after starting an herbal supplement. Patient's Young Mania Rating Scale (YMRS) score was 32. When he did not accept to be hospitalized, he was prescribed antipsychotic. After patient was recommended on often visits. The last exam showed that the patient was recovered from the manic symptoms. When evaluated with Young scale again, he scored 6 on YMRS. In the patient giving the fact that working in shifts made it easier to onset of mania in genetically prone people. But the lack of family history and having no attacks in earlier ages as well as lacking the seasonal changes has driven away this diagnosis. The fact that manic episode has an abnormal onset age led us to think of an organic reason. Using an herbal supplement as well as the symptoms onset led to belief that this condition was caused by supplement. Diagnosis was supported by patient getting better after stopping the supplement. There were no case reporting that blueberry can be caused of manic episode. If there is no other stimulants in the after mentioned supplement, this case may be important for the effects of blueberry. The herbal supplements like this one causing our patient to have a manic episode, should be tested extensively. While questioning the patient about substances, we believe psychiatrists should question herbal supplements also.

### KEYWORDS

Herbal supplement; manic episode; wild berry

Abstract:0128

## Quetiapine Treatment in First Time Manic Episodes Induced by Cannabis and Corticosteroid Use: Two Case Reports

Ayşe Dilara Yalçın, Ümit Tural and Hilmi Yaşar

Department of Psychiatry, Kocaeli University, Kocaeli, Turkey

E-mail address: [dradyalcin@gmail.com](mailto:dradyalcin@gmail.com)

### ABSTRACT

Corticosteroid use could cause psychiatric symptoms such as mania/hypomania or depression<sup>1</sup>. Also it is known that cannabis use increases the risk of developing mania<sup>2</sup>. We present two cases having first time manic episodes induced by cannabis or corticosteroid use and both were treated with quetiapine.

Case 1: Our first case was a 37 year-old, married, female patient. One month ago she was diagnosed of solitary plasmacytoma. She was treated with dexamethasone 16 mg/day (approximately 106.6 mg/day prednisolone equivalent). On the tenth day of the steroid use she had insomnia, increase in her speech amount and speed, grandiosity and irritability. She was transferred to psychiatry clinic for having manic episode. She was treated with quetiapine 600 mg/day and corticosteroid was discontinued. The manic symptoms improved rapidly in two weeks and quetiapine was stopped a month later. During her follow-ups for two years she did not show recurrence.

Case 2: Our second case is a 42 year-old, single, female patient. She had symptoms such as insomnia, grandiosity and increase in her speech amount and speed for a month. She was using cannabis every day for the last two months. The patient was hospitalized with the diagnose of manic episode and quetiapine 900 mg/day was started. After one month she was discharged and quetiapine doses were decreased to 300 mg/day. During her follow-ups for one year, she also did not show recurrence.

Using corticosteroids for short term and high doses (>40 mg/day prednisolone equivalent) by intravenous administration causes more likely manic symptoms than depressive symptoms<sup>3</sup>. There are also other risk factors for our first case such as being female, having a first degree relative with psychiatric disorders and having hypoalbuminemia. For the both of our cases, the rapid improvement and not having any recurrence during long-term follow-ups showed that using quetiapine was an effective choice to consider.

### KEYWORDS

Cannabis; corticosteroids; mania; quetiapine

Abstract:0130

## Interferon $\beta$ 1-a-Induced Hypomania

Serdar Süleyman Can, Yasin Duman, Ali Çayköylü, Şükrü Alperen Korkmaz, Görkem Karakaş Uğurlu and Ayşegül Taşdelen Kul

Department of Psychiatry, Yildirim Beyazıt University, Ankara, Turkey

E-mail address: [aysegul.tsdln04@hotmail.com](mailto:aysegul.tsdln04@hotmail.com)

### ABSTRACT

Psychotic and manic disorders are more common in patients with multiple sclerosis compared to the general population. Interferon- $\beta$ 1a treatment is commonly used for patients with multiple sclerosis and have several psychiatric adverse effects. These side effects are described as depression, delusion and acute delirium in studies and case reports. We will discuss the manifestation of manic symptoms after the interferon  $\beta$  1a treatment has been started for the patient who has been followed up for ten years with diagnosis of multiple sclerosis. A 25 years-old male, working as security officer and diagnosed with multiple sclerosis for ten years presented with depressive mood, suicidal ideas, anhedonia, impaired sleep, and loss of appetite for 4 months was referred to psychiatry outpatient clinic from neurology. The patient gave no family history of bipolar disorder in a sibling. There was no history of substance abuse and psychiatric illnesses. It was learned that the patient had started IFN beta 1a treatment 6 months ago. Afterwards he began to exhibit euphoric mood, hyper sexuality, psychomotor acceleration, decreased need for sleep, excessive talkativeness for a month. In this period, it was learned that there was no psychiatric outpatient admission and that the functioning was not significantly affected. Because the patient don't have any mood episode story before and complaints emerged after the interferon B1a treatment, hypomanic episode is attributed to drug. Psychiatric side effects, particularly mood disorders,

### KEYWORDS

Hypomania; interferon; multiple sclerosis

have been reported with IFN- $\alpha$  treatment before but IFN- $\beta$ -induced hypomania or mania is not yet fully established. Considering the link between IFN- $\beta$  and psychiatric symptoms, physicians should closely monitor the patients who takes multiple sclerosis treatment.

Abstract:0144

## Bipolar Disorder with Marfan Syndrome: A Case Report Based Possible Involvement of TGF- $\beta$ 1 in the Common Etiopathogenesis

Yasin Hasan Balcioglu, Simge Seren Kirioglu and Guliz Ozgen

Department of Psychiatry, Bakirkoy Prof. Dr. Mazhar Osman Training and Research Hospital for Psychiatry, Neurology and Neurosurgery, Istanbul, Turkey

E-mail address: [yasinhasanbalcioglu@bakirkoyruhsinir.gov.tr](mailto:yasinhasanbalcioglu@bakirkoyruhsinir.gov.tr)

### ABSTRACT

Marfan Syndrome (MFS) is mainly characterized by pathological connective tissue in various organ systems. The mutant *fibrillin-1* (*FBN1*) gene misleads the constitutive pathways of various tissues through inappropriate *transforming growth factor beta* (TGF- $\beta$ ) signaling. Bipolar disorder (BPD) is believed to arise as results of impaired synaptic modulation and neural plasticity in crucial pathways those mediate cognition and affection. In the literature, Marfan Syndrome and BPD comorbidity has not been sufficiently figured out. This report aimed to present a Marfan Syndrome case with BPD with arguing probable impaired neuroprotective mechanisms. A 26 years-old male, was diagnosed MFS when he was found to have aortic root dilatation requiring surgical repair, in his 23, with confirmed lens dislocation and shown mutation in chromosome 15. The patient was diagnosed with BPD in his 18, with the first episode of mania. The patient was hospitalized with suicidal thoughts, anhedonia and sleeplessness, with the diagnosis of BPD depressive episode. He had been under per oral medication with olanzapine 10 mg/day and lithium carbonate 900 mg/day. We raised olanzapine up to 20 mg/day and lithium carbonate up to 1200 mg/day per oral and depressive symptoms improved. Defects on the microfibrillar-proteins may predispose for neurodevelopmental abnormalities. TGF- $\beta$  was found to be affiliated with neurogenesis and developmental neural remodeling in animal studies. Altered TGF- $\beta$  functions with pleiotropic effects to the brain could increase susceptibility to psychiatric disorders. Disrupted circuits of molecular signaling chains cause improper synapse formation, synaptic transmission and synaptic plasticity those ultimately end up with BPD. The mutant *FBN1* gene in MFS misleads the TGF- $\beta$  signaling and may disrupt its roles in neuroprotection and neurodevelopmental processes. Our report could pave the way for latter studies on possible shared etiopathogenesis via defective microfibril proteins, of both disorders.

### KEYWORDS

Bipolar disorder; Marfan Syndrome; neuroprotection; TGF- $\beta$ 1

Abstract:0151

## Atypical First Episode Bipolar Mania: A Case Report

Deniz Altunova, Recep Başaran, Mustafa Çağrı Yıldız, Ali Baran Tanrikulu, Münir Karaaslan and İbrahim Eren

Psychiatry Clinic, Konya Training and Research Hospital, Konya, Turkey

E-mail address: [denizaltunova@hotmail.com](mailto:denizaltunova@hotmail.com)

### ABSTRACT

Bipolar disorder, also known as manic depression, is a mental disorder with periods of depression and periods of elevated mood. The causes are not clearly understood, but both environmental and genetic factors play a role. Mania can be easily diagnosed generally. Early diagnose and suitable treatment provides some advantages like short duration of manic episode, decrease the possibility of new manic episode and protection of cognitive functions. In this report we presented case about first episode mania and conversion disorder like epileptic seizure differential diagnosis and treatment. The patient was a 31 year-old married woman. She complained sleeplessness, suspiciousness, irritability, self-mutilation, inappropriate crying and laughing attacks in the past 3 days. Because of these complaints she applied emergency service and after first treatment she consulted with psychiatrist. After first examination; initial diagnosis is manic episode so that olanzapine 5 mg/day was ordered. 2 days later she fainted like epileptic seizure or conversion disorder. After analyzing EEG and

### KEYWORDS

Mania; conversion disorder; epilepsy

Brain MRI by neurologist for differential diagnosis of manic episode or temporal lobe epilepsy. In MRI there is no major pathology but in EEG there is slow wave activity. Neurologist ordered carbamazepine 400 mg/day to the patient. Her seizure frequency increased after medication of carbamazepine so carbamazepine stopped. ECT has been applied 10 session and olanzapine dose potentiate to 20 mg/day. After this treatment her complaints seizures regressed obviously. Valproic acid was ordered to patient as mood stabilizer. Conversion disorder is now contained under the umbrella term functional neurological symptom disorder. In cases of conversion disorder, there is a psychological stressor. Conversion symptoms typically do not conform to known anatomical pathways and physiological mechanisms. Mania must be differentiated from conversion symptoms and disorder. So psychiatrist must be aware of this situation because early diagnose is important for treatment and prognosis of mania.

Abstract:0167

## A Case of Major Depressive Disorder with Psychotic Features Due to Life Events

Fatih Kizilağaç and Ümit Tural

Department of Psychiatry, Kocaeli University, Kocaeli, Turkey

E-mail address: [fatihkizil1987@hotmail.com](mailto:fatihkizil1987@hotmail.com)

### ABSTRACT

The role of psychological and social factors in depression is important. Particularly major economic problems, loss of love object, experience of injurious events and more physical and psychological events cause to initiate and become chronic mood disorder. In this case report, it was aimed that negative life events could initiate to Major Depressive Disorder in vulnerable individuals to depression. A 62 year-old, uneducated, illiterate woman who was married 41 years ago and lost her husband from myocardial infarction 5 years ago, has 8 children and not working female patient. The patient has been seeing evil images and talking to them for the last 1.5 months. She thought that others have injured her. After the patient had lived in her hometown for 60 years, she migrated to her children a year ago due to economic problems. She was an unsocial, helpful, self-giving, benevolent, meticulous person. When she was a child, she experienced physical violence from her mother, her father and then her husband in marriage. When the patient was child her mother and father and then in marriage her husband may have been exposed to physical violence, loss of partner, migration from their home country for a long period of time, problems in their new environment, financial problems; they may have induced her unpleasantness, inferiority, imperfection, failure and inadequacy ideation and they may have led her to believe that she was a worthless and unloved person, that her future would dark and empty, and that she may has perceived it. The patient with personality traits that were susceptible to depression may has been exposed to adverse events many times during her life, has been unable to escape from them in the face of painful events, has been unable to cope them may have caused to depression.

### KEYWORDS

Depressive disorder; life events; psychotic

Abstract:0263

## Treatment-Resistant Depression (TRD) as a Predictor for Bipolar Disorder: A Case Report

Ali Baran Tanrikulu, Mustafa Çağrı Yıldız, İkbāl İnanlı, Tuba Şerife Elmas and Yusuf Çokünlü

Konya Training and Research Hospital Psychiatry Clinic, Konya, Turkey

E-mail address: [dr.floyd9@yahoo.com](mailto:dr.floyd9@yahoo.com)

### ABSTRACT

Treatment-resistant depression (TRD) is a term used to describe case of major depressive disorder (MDD) that do not respond adequately to appropriate courses of at least two antidepressants. Bipolar disorder, also known as manic depression, is a mental disorder with periods of depression and periods of elevated mood. According to DSM-5, patients must be experiencing their first manic episode to meet the diagnostic criteria for bipolar I disorder, single manic episode. This requirement rests on the fact that patients who are having their

### KEYWORDS

Treatment-resistant depression; bipolar disorder; predictive

first episode of bipolar I disorder depression cannot be distinguished from patients with major depressive disorder. In this report we presented a case about treatment resistant depression relationship with bipolar disorder. A 62 year-old married woman with history of depressive disorder for 2 years was referred to inpatient clinic. She has been started medications as fluoxetine, venlafaxine, olanzapine, lorazepam for 2 years for depressive complaints like sleep disturbances, hopeless, loss of appetite, somatic symptoms, fatigue, psychomotor retardation, diminished functioning. She has taken venlafaxine 300 mg/day for 1 year and fluoxetine 40 mg/day for 1 month. Although regularly medication taking her complaints are not regressed. Venlafaxine was titrated up to 375 mg/day. She was started to ECT. After 1 month because of inadequate response to treatment; it was augmented with bupropion 300 mg/day, aripiprazole 5 mg/day. After 9 session of ECT she was presented with irritability, persecutory delusion, and logorrhea, goal-directed behavior, disoriented in time, person and place. After 3 days her complaints revealed. She was assessed as switching to mania and ECT was continued. Totally 13 session ECT was administered. Affective symptoms was revealed and she was discharged with current treatment. There are some clinical features predictive of bipolar disorder as bipolar family history, depression with marked psychomotor retardation, failed antidepressants from different classes, agitated depression, recurrent depression, and hyperthymic temperament. In this case, patient has some indicators for bipolarity as hyperthymic temperament, failed antidepressant therapy, marked psychomotor retardation. In conclusion, case highlights the importance of switching from depression to mania in treatment resistant depression which clinician should be vigilant about ongoing treatment.

Abstract:0304

## Manic Symptoms Associated with Isotretinoin: A Case Report

Esra Porgali Zayman, Rifat Karlıdağ, Mustafa Akan, Lara Utku İnce and İsmail Reyhani

Department of Psychiatry, Inonu University, Malatya, Turkey

E-mail address: [esra\\_porgali@hotmail.com](mailto:esra_porgali@hotmail.com)

### ABSTRACT

Isotretinoin, also known as 13-cis-retinoic acid, is used to treat acne vulgaris. Isotretinoin is associated with several psychiatric side effects. In the present case we reported on an isotretinoin-induced manic in a patient and we aimed to add this growing body of data. A 21 year-old male patient presented to our psychiatry outpatient clinic by his relatives due to decreased need for sleep, increased psychomotor activity, rapid speech, irritability, flight of ideas, grandiosity. His symptoms had started about 30 days previously. In the past medical history of the patient, dermatologist had started isotretinoin treatment 8 months prior and the dosage was increased 3 months prior. After only 2 months of the dosage increased, psychiatric symptoms began to emerge. The patient had a history hypomanic episode and depressive episode. But he hadn't admitted any psychiatry clinic for the treatment. Dermatologists recommended stopped using Isotretinoin. Risperidone was started at 2 mg/day and increased to 4 mg/day. Sodium valproate 1250 mg/day was added on the 11th day. After this treatment, the patient's symptoms decreased and returned completely to premorbid status. Although the mechanism of action for isotretinoin is not exactly known, the current knowledge indicates that isotretinoin can affect the central nervous system, particularly neuronal development and neurotransmitter systems. These findings and previous work indicate that isotretinoin may provoke bipolar symptoms in individuals who had previous psychiatric disease history. In a study based on the reports of the US Food and Drug Administration (FDA), mania emerged, 40.62% of patients using isotretinoin for 1 to 6 months. In our case the manic symptoms began to emerge when the Isotretinoin dosage was increased after 2 months. Dermatologists should be aware of the possible side effects of isotretinoin in the patients who have history of psychiatric disorders.

### KEYWORDS

Isotretinoin; mania; treatment

Abstract:0315

## Delusion of Pregnancy in Bipolar Disorder: A Case Report

Ender Cesur, Sevda Bağ and Çağatay Karşıdağ

Bakirkoy Research and Training Hospital for Psychiatry, Neurology, and Neurosurgery, Istanbul, Turkey

E-mail address: [ender\\_cesur@hotmail.com](mailto:ender_cesur@hotmail.com)

**ABSTRACT**

Pregnancy delusions are a special form of hypochondriac/somatic delusions. Even though pregnancy delusions are rare, delusional development is similar to psychodynamics of other delusions. Despite the lack of evidence, it can be described as a false belief that someone is pregnant. Historically, the first case involving pregnancy delusions was documented by Esquirol in the early 19th century (1). It can be seen not only in women but also in men. Patients can be married or single (2). Pregnancy delusions can be seen from different age groups (3). More of pregnancy delusions is associated with organic brain injury and delusions can be seen in schizophrenia, schizoaffective disorder, mood disorders, as well as in relation to many organic and metabolic conditions. Patients with pregnancy delusions may have higher treatment resistance, which negatively affects the prognosis. In this case report, a forty-six year-old female with bipolar disorder was presented. She had multiple hospitalizations. At each visit she described similar delusions of pregnancy. The medication has not been adjusted since it is thought that the treatment will harm the babies. Despite availability of many treatment options, delusions contributes to a significant loss in patient's quality of life.

**KEYWORDS**

Pregnancy; delusions; bipolar

**References**

- [1] Vie J, Bobe J. Les idees delirantes de grossesse. *L'Encephale* 1932; 27: 468–502.
- [2] Simon M, Vörös V, Herold R, Fekete S, Tenyi T. Delusions of Pregnancy with Post-Partum Onset: An Integrated, Individualized View. *Eur. J. Psychiatry* 2009;23(Suppl. 4):234–242.
- [3] Camus V, Schmitt L, Foulon C, Lima CA, Wertheimer J. Pregnancy delusions in elderly depressed women: A clinical feature of Cotard's syndrome? *Int J Geriatr Psychiatry*. 1995;10:1071–1073.

Abstract:0320

## A Bipolar Disorder Patient with Primary Polydipsia: A Sign of HPA Axis Dysfunction?

Yasin Hasan Balcioglu, Simge Seren Kirlioglu and Fatih Oncu

Bakirkoy Prof. Dr. Mazhar Osman Training and Research Hospital for Psychiatry, Neurology and Neurosurgery, Istanbul, Turkey

E-mail address: [yasinhasanbalcioglu@bakirkoyruhsinir.gov.tr](mailto:yasinhasanbalcioglu@bakirkoyruhsinir.gov.tr)

**ABSTRACT**

Primary polydipsia (PP) is a condition that refers excessive thirst and intake of fluids, and observed with psychiatric disorders in general. It is important to diagnose and treat the PP due to its life-threatening complications some like seizures, cerebral edema, cardiac arrest and coma which are existed through hyponatremia. Hypothalamic-pituitary-adrenal (HPA) axis dysregulation and malfunction of thirst center have been asserted as underlying pathologies of PP. Although PP is reported with schizophrenia in common, bipolar disorder (BPD) is infrequently described in concurrence. We aimed to provide evidence for the associative role of HPA axis dysfunction in PP comorbid bipolar disorder. A 28 year-old man had been diagnosed with BPD for three years, presented with 5-month-history of increased water intake, around 12–15 L/day. He had a history of three episodes of mania and two of depression in the past. His last manic episode was registered 5 months ago and remission was observed with lithium 2100 mg/day and paliperidone 6 mg/day treatment. He admitted our outpatient clinic for a follow-up. A thorough clinical and diagnostic assessment revealed that patient had not any medical condition which could lead to polydipsia. We planned to add quetiapine in his treatment with the aim of benefit its effects on dopaminergic receptors and close follow-ups were offered. Despite the cause of polydipsia remains unclear, it had been suggested that defect in hypothalamic thirst center lead to altered feedback regulation of the HPA axis via excessive water intake. HPA axis dysfunction has been also asserted in BPD due to result in dopaminergic neurotransmission disturbance. It is argued that dysregulation of HPA axis could be the underlying reason of affective disorders and the mechanism which may lead to PP. In this case, we aimed to discuss that probability of common etiology PP and BPD.

**KEYWORDS**

Bipolar disorder; HPA axis; polydipsia



Abstract:0333

## Electroconvulsive Therapy-Induced Manic Episode in a Pharmacotherapy Resistant Catatonic Adolescent Patient

Fatma Belger and Bürge Kabukçu Başay

Department of Child and Adolescent Psychiatry, Pamukkale University, Denizli, Turkey

E-mail address: [fbelger@hotmail.com](mailto:fbelger@hotmail.com)

### ABSTRACT

Catatonia may be associated with numerous psychiatric or medical conditions. Bipolar disorder is the most common cause of catatonia. In this report electroconvulsive therapy (ECT)-induced mania in an adolescent catatonic patient with bipolar depression is presented. A 15 year old girl who was on follow-up with bipolar depression admitted to the hospital with complaints of food intake refusal for three days and standing still in the same body posture, when she was on 1200 mg/day lithium, 200 mg/day, quetiapine and 0.5 mg/day lorazepam. The patient's psychomotor retardation was profound and she was hospitalized with catatonia. Bupropion 150 mg/day, lamotrigine 50 mg/day, lorazepam 2.5 mg thrice daily, and escitalopram 20 mg/day were added to treatment. Since skin rashes appeared, lamotrigine was stopped. As the symptoms persisted, 18 sessions of transcranial magnetic stimulation was applied, however again with no significant benefit. Thus, ECT was started. She improved from catatonia after the 6th session. At the 8th session ECT was stopped with manic switch. Escitalopram was stopped, and quetiapine was increased to 600 mg/day. The patient was discharged upon the parents' request. Currently, she has been receiving 1200 mg/day lithium, 600 mg/day quetiapine, 4 mg/day risperidone, 150 mg/day bupropion and 2.5 mg/day lorazepam and manic symptoms are still present after the 2nd month of mania. In children and adolescents, catatonia is similar to those in adults; and responds favorably to benzodiazepines and/or ECT. However, the obstacles are fairly numerous. Patients with bipolar disorder with an earlier onset age are characterized by lower response rate and higher manic switch rate. There are reports of increased mania risk following ECT. However, there are no established management guidelines. Benzodiazepine resistant psychomotor retardation and long-lasting manic episode were the main challenging characteristics of our patient. ECT improved the severe catatonia however shifted the patient into a manic episode which could not be controlled easily.

### KEYWORDS

Bipolar disorder; catatonia; ECT; mania; treatment resistance

Abstract:0344

## Onset of Organic Affective Disorder Following Meningioma Resection

Volkan Seneger, Can Tuncer, Hasan Turan Karatepe and Aynur Görmez

Department of Psychiatry, Istanbul Medeniyet University, Istanbul, Turkey

E-mail address: [senegervolkan@hotmail.com](mailto:senegervolkan@hotmail.com)

### ABSTRACT

In everyday busy psychiatric clinical practice, there are important lessons we take such as paying attention to the initial non-psychiatric symptoms. Here we present a case with organic affective disorder following neurosurgical operation. Organic affective disorders may originate from different medical disorders such as, metabolic disorder, neurological disorder, endocrine disorder and cancer. Not so often following brain surgery organic affective disorder may occur. 45 years-old, female patient initially presented with the symptoms of headache, tiredness, fatigue, difficulties in walking, and falling. She has no family history of psychiatric illness. Then 3 months later an MR of the brain examination revealed atypical meningioma pressing on right ventricle. She had urgent operation and the tumor was removed. Immediately MR of brain following operations revealed edema on right side of the brain. Immediately after the surgery, she had developed insomnia, irritability, increased energy, agitation, increased speech, disturbing auditory hallucinations. she also had delusions of persecutory nature. Her treatment included quetiapine 75 mg tablet per day then increased to 100 mg. Because of feeling sedated, quetiapine was reduced to 50 mg per day and aripiprazole 10 mg was introduced. Her symptoms were improved greatly. This case shows how non-psychiatric symptoms may lead to psychiatric disorder. During the course of her clinical presentation the surgical intervention most likely caused manic episode by pressure on right hemisphere.

### KEYWORDS

Affective disorder; meningioma; non-psychiatric; organic symptoms

Abstract:0385

## A Patient who was Admitted for Substance Withdrawal but Diagnosed with Bipolar Disorder: A Case Report

Tuba Şerife Elmas, Saliha Çalışır, Ali Metehan Çalışkan, Ali Baran Tanrıkulu and İbrahim Eren

Department of Psychiatry, Konya Training and Research Hospital, Konya, Turkey

E-mail address: [tubaserife@gmail.com](mailto:tubaserife@gmail.com)

### ABSTRACT

Mood disorders, depression and bipolar disorders, are the most common psychiatric comorbidities among patients with substance use disorders (SUD). Comorbid mood and SUD often have more severe illness that is difficult to manage compared with either a mood or a SUD alone. A 61 year-old man presented to emergency department with superficial wrist incisions. He is suffering unhappiness, misery, hopelessness, desperation, thoughts of death, insomnia, nasal discharge, sneezing, tearing, fatigue, trembling in hands and feet and not wanting to talk. Approximately 6 months of daily use of 2 gr heroin. The examination revealed that the patient's speech was vivid, elaborate, the amount and speed of the conversation increased, accompanied by mimics-gestures. The use of heroin is good for his own confusion, sleepiness, taking care of his work, doing his job, ensuring calmness in his movements. Despite the irritability of the mood, there were hopelessness, regret, sinful thoughts. The past history of the patient was detailed and diagnosed as bipolar disorder (YMRS score:17; HAM-D score:39) and treatment were given 100 mg of quetiapine. Findings of abstinence were not detected. Buprenorphine + naloxone were not needed. Follow-up treatment was regulated as lithium 600 mg/day and quetiapine 600 mg/day. Why are these comorbidities so common? Mood disorders may motivate individuals to resort to drugs and alcohol to cope with their negative affective states. Individuals will tend to select drugs that reduce their specific psychiatric symptoms. An underlying neurobiological tendency to sensitization may promote both drug dependence and mood disorders. Some evidence indicates that treating a comorbid mood disorder can decrease substance abuse and craving. Mood disorders and SUD comorbidity are common. Therefore, patients with SUD should be carefully questioned in other psychiatric disorders in their anamnesis. Successful treatment of one condition can be helpful recovery from the other.

### KEYWORDS

Bipolar disorder; substance use disorder

Abstract:0387

## Ciprofloxacin-Induced Mania: A Case Report

Aslihan Okan Ibiloglu<sup>a</sup>, Abdullah Atli<sup>a</sup>, Mehmet Asoglu<sup>a</sup> and Mustafa Ozkan<sup>b</sup><sup>a</sup>Department of Psychiatry, Dicle University School of Medicine, Diyarbakir, Turkey; <sup>b</sup>Harran University School of Medicine, Sanliurfa, TurkeyE-mail address: [aslihanokan@gmail.com](mailto:aslihanokan@gmail.com)

### ABSTRACT

We report here a case of antibiotic-induced mania that developed in a 32 year old woman treated with ciprofloxacin for urinary tract infections (UTIs) and which resolved spontaneously after discontinuation. A 32 year-old housewife presents to the emergency department with her husband. She seems very restless, pacing up and down the emergency room. She is intermittently starts singing rather loudly. She is wearing bright and colorful clothes. The patient was started on 500 mg of oral ciprofloxacin twice daily for 7 days by the family physician. According to her husband, at the fourth days of treatment, the manic symptoms began. For the past 5 days she has had a broken sleep, but she feels increase of energy. She displays irritable mood, grandiosity, and excessive spending reflecting poor judgement for 5 days. Her speech was mildly pressured and tangential. Physical examination is unremarkable. There is no family history of any mental illness. Results of serum electrolytes, liver and renal function, and blood glucose tests; hemogram; brain magnetic resonance imaging; and electroencephalogram were within normal limits. She smokes 15–20 cigarettes a day, for 6 years. Antibiotic-induced mania, a rare but significant adverse-effect of many drugs, is mostly under-recognized. Our case is presenting with a manic episode. Her ciprofloxacin was stopped at admission. The patient improved as spontaneously several days after stopping the ciprofloxacin therapy. It means that, starting of treatment with mood stabilizing and antipsychotic drugs. Most cases of drug-induced mania are frequently resolved if the etiology is treated. Mania that has drug causes generally does not require protective mood-stabilizing treatment. Indeed, new-onset mania in older adults is most commonly secondary. The

### KEYWORDS

Antibiotic; case; ciprofloxacin; side effect; mania

mechanism behind antibiotic-induced mania is unclear but could be related to  $\gamma$ -aminobutyric acid (GABA) antagonism. There is evidence that ciprofloxacin is a GABA antagonist.

Abstract:0388

## The Mayer-Rokitansky-Küster-Hauser (MRKH) Syndrome with Bipolar Disorder Due to Substance Abuse

Özge Şahmelikoğlu Onur, Ender Cesur, Gülşen Teksin, Suat Yalçın and Sevda Bağ

Bakırköy Research and Training Hospital for Psychiatry, Neurology and Neurosurgery, 3rd Psychiatry Department, Istanbul, Turkey

E-mail address: [ozge\\_sahmelikoglu@hotmail.com](mailto:ozge_sahmelikoglu@hotmail.com)

### ABSTRACT

The Mayer-Rokitansky-Küster-Hauser (MRKH) syndrome is a malformation of the female genitals (occurring in one in 4000 female live births) as a result of interrupted embryonic development of the Müllerian (paramesonephric) ducts. When the literature is screened, there are studies evaluating psychiatric disorders accompanying MRKH, and most of them are about anxiety and depression. There is a limited number of case of MRKH with substance/drug abuse and bipolar disorder. We present a case of MRKH with bipolar disorder due to substance abuse. A 25 year-old female, with the history of MRKH syndrome and have been using cannabinoid, methamphetamine for 6 years, admitted for grandiose delusions, insomnia, rapid speech and agitation. These symptoms began 1 week after she started using methamphetamine. She had been diagnosed with bipolar disorder 6 years ago and had been hospitalized for 3 times and advised to take sodium valproate 1000 mg/day, risperidone 2 mg/day aripiprazole 10 mg/day and quetiapine 100 mg/day. Her lab work up was remarkable; including positive urine toxicology ecstasy and cannabinoid. In her psychiatric examination grandiose delusions, auditory hallucinations, elevated mood were noted. She noted that she had been using substance for forgetting of having MRKH syndrome and of being stigmatized. The patient met DSM-5 criteria for a manic episode and was started on haloperidol 20 mg/day and biperidene 10 mg/day and quetiapine 200 mg/day. The patient's symptoms gradually improved within one week with attainment of euthymic mood, improved sleep and resolution of grandiosity. She noted that she had been using substance for forgetting of having MRKH syndrome and of being stigmatized. Based on this case it might be suggested that psychiatric disorders such as substance abuse should be assessed cautiously in MRKH patients due to development of mood symptoms.

### KEYWORDS

Mayer-Rokitansky-Küster-Hauser syndrome; Bipolar disorder; substance abuse

Abstract:0391

## Manic Symptoms Due to Modified-Release Methylphenidate Use in an Adolescent: A Case Report

Serkan Güneş

Department of Child and Adolescent Psychiatry, Hatay State Hospital, Hatay, Turkey

E-mail address: [dr\\_sgunes@hotmail.com](mailto:dr_sgunes@hotmail.com)

### ABSTRACT

Methylphenidate (MPH) is a widely prescribed agent for the first line treatment of attention-deficit/hyperactivity disorder (ADHD) in children and adolescents. In this paper, we report the occurrence of mania-like symptoms with modified-release MPH use in an adolescent with intellectual disability (ID). A 16-year old male patient was referred to our clinic with the complaint of attention difficulty and learning disability. As a result of his psychiatric and psychometric examinations, he was diagnosed with ADHD and mild ID and initiated modified-release MPH 20 mg/day. One week after initiating MPH, he presented to emergency room with the complaint of irritability, logorrhea, and sleeplessness. His psychiatric evaluation revealed euphoria, grandiosity, and incongruent affect. Young mania rating scale (YMRS) score was 32. His neurologic examinations, blood tests, and computerized tomography were normal. Methylphenidate was stopped, however, his symptoms did not resolve. We initiated valproate 1000 mg/day and risperidone 2 mg/day and his symptoms

### KEYWORDS

Adolescent; child; mania; methylphenidate

started reducing within a week. Two months later YMRS score decreased to 6 and we stopped both valproate and risperidone. Therapeutic doses of stimulants can cause psychosis and/or mania symptoms in a small proportion of treated children. Presenting symptoms generally resolve within a week after discontinuation. However, the symptoms did not resolve with stoppage of MPH and we had to initiate valproate and risperidone in our case. Although not clearly understood, psychotic/manic symptoms may be associated with the mechanism of action of MPH. MPH inhibits the reuptake of dopamine and noradrenaline in the striatal, frontal, and temporal regions. Increased dopaminergic and/or noradrenergic activity in these regions may be related with the emergence of the symptoms. Eventually, this case highlights the fact that therapeutic dose of modified-release MPH may cause mania-like symptoms in children and adolescents with ID and psychopharmacological interventions may require to control these symptoms.

Abstract:0431

## Ecstasy-Induced Bipolar Disorder with Psychotic Features

Ali Metehan Çalışkan, Ebru Çiftçi, Sehure Azra Yaşar, İkbāl İnanlı and İbrahim Eren

Department of Psychiatry, Konya Training and Research Hospital, Konya, Turkey

E-mail address: [drmete@hotmail.com](mailto:drmete@hotmail.com)

### ABSTRACT

The role of stimulants in Bipolar Disorder has been an area of interest. 3,4-methylenedioxymethamphetamine (MDMA) is an amphetamine derivative stimulant, and is typically the active component of ecstasy, a popular illicit drug. The pharmacological action of MDMA leads to a rapid and substantial increase in serotonin levels in the intrasynaptic space but it also boost dopamine, norepinephrine and acetylcholine in multiple brain regions. It may have antidepressant-like effects. MC is a 21 year-old man. In 2016, MC had used one ecstasy tablet and directly afterwards he was brought to the emergency service by his mother for increased level of energy, decreased need for sleep, increased verbal output with a disorganized thought process and auditory and visual hallucinations. The patient was hospitalized. Valproate (1000 mg/day) and olanzapine (10 mg/day) was started. He improved clinically and was discharged on day 35. At 12 weeks after discharge his mood was normal on assessments. After he had used one ecstasy tablet his symptoms relapsed. When he presented the second time, his behavior was more exaggerated than the first hospitalization. Olanzapine's dose was increased by 20 mg. At 4 weeks after increasing olanzapine, he improved clinically and was discharged. Our patient developed a manic episode with single dose use of MDMA. The case presented here is unusual because in most reported cases, the authors described manic episode in individuals who were heavy stimulant abusers and who also chronically misused other illicit drugs. It is documented that ecstasy may induce manic episode associated with psychosis among adults and it would be prudent for clinicians to routinely ask patients about ecstasy use and to include MDMA in toxicology screens.

### KEYWORDS

Bipolar disorder; manic episode; ecstasy; 3,4-methylenedioxy methamphetamine (MDMA)

Abstract:0444

## Buspirone-Induced Hypomania: A Case Report

Erensu Baysak, Nese Yorguner Kupeli, Serhat Ergun and Kaan Kora

Department of Psychiatry, Marmara University School of Medicine, Istanbul, Turkey

E-mail address: [erensubyskk@gmail.com](mailto:erensubyskk@gmail.com)

### ABSTRACT

Buspirone, a 5HT<sub>1A</sub> partial agonist, is an anxiolytic agent and has dopaminergic, noradrenergic, and serotonin-modulating activity. Its efficacy resembles to that of benzodiazepines in general anxiety disorder although its antidepressant effect is controversial. However, buspirone-induced mania/hypomania was encountered in rare cases as follows. A 63 year-old patient who has been followed-up with bipolar disorder for 30 years and cognitive impairment for 2 years presented to our clinic with complaints such as free floating anxiety, annoyance, depressive mood, psychomotor agitation, anhedonia, and suicidal thoughts. He was

### KEYWORDS

Bipolar disorder; buspirone; hypomania; mania

diagnosed with bipolar depression and hospitalized. He was taking lithium 900 mg, clozapine 400 mg, and quetiapine 400 mg as maintenance treatment. An add-on therapy of buspirone 15 mg/day was titrated to 30 mg/day for his anxiety. Neither antidepressants nor benzodiazepines were prescribed because of switch risk and cognitive impairment. In 2 weeks all complaints were improved and the patient was discharged. One week later, he presented with increased energy, elevated mood, improperly spending money, increase in sexual desire, decrease in need for sleep, flight of ideas, and boost in goal-directed activity. The patient was hospitalized with hypomanic episode. Buspirone treatment was discontinued and 300 mg quetiapine was prescribed. After 3 weeks the patient was discharged with partial remission. Buspirone, which the patient never used before, reduces depressive anxiety; however, manic shift can be interpreted as mania/hypomania induced by buspirone. Possible mechanism is that buspirone may enhance dopaminergic and catecholaminergic activity while inhibiting serotonergic activity in the central nervous system. In our case there is also a known bipolar disorder, it may be a hypomanic episode unrelated to the buspirone. Nevertheless, given the facts in the literature, hypomania may be developed after the onset of buspirone, and this case report may be an example for buspirone-induced mania/hypomania.

Abstract:0445

## Major Depressive Disorder During Parkinson's Disease: A Case Report

Mehmet Asoğlu<sup>a</sup>, Hatice Takatak<sup>b</sup>, Abdullah Atlı<sup>c</sup> and Aslıhan Okan İbiloğlu<sup>c</sup>

<sup>a</sup>Department of Psychiatry, Harran University School of Medicine, Sanliurfa, Turkey; <sup>b</sup>Department of Child and Adolescent Psychiatry, Harran University School of Medicine, Sanliurfa, Turkey; <sup>c</sup>Department of Psychiatry, Dicle University School of Medicine, Diyarbakir, Turkey

E-mail address: [mehmetasoglu@gmail.com](mailto:mehmetasoglu@gmail.com)

### ABSTRACT

Parkinson's disease (PD) is a chronic and progressive neurodegenerative disease co-occurring degeneration in dopaminergic neurons. It is recognized by the presence of a variety of neurological symptoms such as rigidity, bradykinesia, postural imbalance, and usually unilateral resting tremor. Although Parkinson's Disease is mainly a movement disorder, it defined as a neuropsychiatric disorder due to often accompanied by affective, cognitive and psychotic disorders. The incidence of depression is around 30-40%, which the most common psychiatric disorder in Parkinson's disease. We aimed to share a case to contribute to the literature, which major depressive disorder was diagnosed in the outpatient clinic and understood to be Parkinson's disease causing depression as a result of detailed anamnesis and examination in the clinic. At the age of 55, he had Parkinson's disease for 6 years and did not receive any treatment. He applied to our clinic with reluctance, malaise, lack of enjoyment of life, decreased self-care, insomnia and decreased appetite. There were tremor, mask face, bradykinesia and parkinsonian walk depending on the Parkinson. The blood count, routine biochemistry, complete urine analysis, thyroid function tests were within normal limits. Cerebral magnetic resonance imaging was within normal limits. Patient's history was obtained from the family and this was not supportive of dementia diagnosis. Patient was counseled with neurological examination with MR results, and then Parkinson was diagnosed and Parkinson therapy was added to the depression treatment. In this case report, it was emphasized that depressive disorder may occur during Parkinson's disease monitoring, that patients should be watched carefully and the treatment should be regulated.

### KEYWORDS

Parkinson's disease; major depressive disorder

Abstract:0451

## The First Episode Bipolar Disorder Mania with Psychotic Features Induced by Amphetamine Use

Mehmet Asoğlu<sup>a</sup>, Öznur Akıl<sup>a</sup>, Abdullah Atlı<sup>b</sup> and Aslıhan Okan İbiloğlu<sup>b</sup>

<sup>a</sup>Department of Psychiatry, Harran University School of Medicine, Sanliurfa, Turkey; <sup>b</sup>Department of Psychiatry, Dicle University School of Medicine, Diyarbakir, Turkey

E-mail address: [mehmetasoglu@gmail.com](mailto:mehmetasoglu@gmail.com)

**ABSTRACT**

Amphetamine is one of the most frequently used illegal substances in Turkey. During the case of amphetamine use, emotional and behavioral symptoms such as blunted affect, tension, anger, stereotyped repetitive behaviors, judgmental disorders, delusions, and hallucinations may arise in the affect. Symptoms similar to schizophrenia due to the use of amphetamine have been reported. However, there was no data on the cause of bipolar disorder mania. Patient is a 19 year-old single girl, a high school graduate, is a consultant in a private firm. She has complaints such as too many talk, billingsgate, excessive anger, harm to herself and the environment, waking, restlessness, increasing energy, not eating, increasing religious worship, increasing sexual desire, self-importance, hear directing voices. Her complaints started 10 days ago for the first time, there was no psychiatric story in his past and his family history. Delirium was excluded for differential diagnosis. Dependency screening tests were requested. The level of amphetamine was high. Treatment was started with lithium 1200 mg/day, olanzapine 20 mg/day, haloperidol 20 mg/day, biperidine 4 mg/day, and chlorpromazine 200 mg/day. The patient began to gain insight and her complaints reduced. She discharged with a full remission on the 19th day of hospitalization, with reduced doses of the drug.

Manic episode related to substance use was diagnosed according to DSM-5, with symptoms are not before the use of the substance, it takes a considerable amount of time after the use of the substance and the exclusion of delirium. The manic episode may have been triggered directly by the use of amphetamine, or amphetamine use, will develop in the future of a manic episode may have led to the emergence earlier.

**KEYWORDS**

Mania; amphetamine; bipolar disorder